



# An Overview of the Epidemiology, Pathogenesis, Diagnosis, and Treatment of Human Parvovirus B19

Kumaran Vadivel<sup>a++\*</sup>, Balaji Nandagopal<sup>a</sup>,  
Mageshbabu Ramamurthy<sup>a</sup>, Nithiyanandan Saravanan<sup>a</sup>  
and Prashanth Rajendiran<sup>a</sup>

<sup>a</sup> Sri Sakthi Amma Institute of Biomedical Research, Sri Narayani Hospital and Research Centre, Sripuram, Vellore - 632055, Tamil Nadu, India.

## Authors' contributions

This work was carried out in collaboration among all authors. All authors read and approved the final manuscript.

## Article Information

DOI: 10.9734/AJRID/2022/v11i4226

## Open Peer Review History:

This journal follows the Advanced Open Peer Review policy. Identity of the Reviewers, Editor(s) and additional Reviewers, peer review comments, different versions of the manuscript, comments of the editors, etc are available here: <https://www.sdiarticle5.com/review-history/94102>

**Review Article**

**Received: 20/09/2022**  
**Accepted: 26/11/2022**  
**Published: 01/12/2022**

## ABSTRACT

Human Parvovirus B19 (HPV-B19) infections are reported from different parts of the globe. The infection occurs in all age groups; however, most infections occur in childhood. There is evidence of exposure to the virus in about 80% of adults when screened for specific IgG. HPV-B19 is incriminated in several conditions like erythema infectiosum, aplastic crisis, hydrops fetalis and arthropathy. HPV-B19 is a cause of the Fifth disease (erythema infectiosum); it could also cause a febrile illness with or without rash in adults. Many adults especially women develop arthropathy and the condition could be chronic following a febrile illness. Patients (adults) with End Stage Renal Disease (ESRD) are prone to develop aplastic crisis or chronic anemia [1]. This review article aims to comprehensively describe the etiology, epidemiology, clinical features, diagnostic methods, and treatment in the management of HPV-B19.

<sup>++</sup> Assistant Professor

\*Corresponding author: E-mail: kumaranv1978@gmail.com;

**Keywords:** Arthropathy; End-stage renal disease; febrile illness; IgM; HPV-B19.

## 1. INTRODUCTION

Human Parvovirus B19 (HPV-B19) infection is associated with erythema infectiosum (fifth disease), with febrile illnesses [1]. There is evidence that fever alone without rash and fever with arthralgia without a rash can occur in HPV-B19 infection [2,3]. It is proposed that HPV-B19 could cause acute glomerulopathy and could also be a cause of anemia in ESRD and kidney transplantation. Members of the family *Parvoviridae* are among the smallest known DNA-containing viruses that infect mammalian cells (*Parvum* "small"; Latin). The *Parvoviridae* family contains many pathogenic animal viruses and (HPV-B19) is one among them known to be pathogenic in humans. HPV-B19 is also one of the best-characterized members of the family *Parvoviridae* and is classified as a member of the *Erythroparvovirus* genus.

The HPV-B19 virion is an icosahedron consisting of 60 copies of the capsid proteins. Most of the capsid is VP2, a 58-kD protein, with 5% or less of the larger 84-kD, VP1 protein. These capsid proteins are encoded by overlapping reading frames and are expressed during productive infection. The smaller VP2 protein constitutes 95 percent of the capsid while the larger VP1 protein makes up only 5 percent. VP1 protein differs from VP2 by an additional 227 amino acids at the amino terminus. The virion surface has a major depression encompassing the fivefold axis, similar to the canyon structure found in RNA-containing icosahedra viruses. In HPV-B19 capsids, there is also a hollow cylindrical structure around the fivefold axis that appears to penetrate the inside of the virion. The structural distribution of VP1 in the HPV-B19 capsid structure cannot be inferred from the crystallographic structures, but based on antibody-binding and structural studies, in infectious HPV-B19 the VP1 unique region appears to be exposed on the viral surface adjacent to the fivefold axis cylinder. It has been shown that the VP1 unique region of all parvoviruses, including HPV-B19, has a phospholipase A2 motif. Infection studies with HPV-B19 (and other parvoviruses) show that this motif is required for viral infectivity [4]. Parvovirus B19 infection causes wide spectrum of disease, this review focuses on transmission of HPV-B19 Arthralgia Arthropathy, Transient Aplastic Crisis, Hydrops Fetalis, and other

syndromes associated with HPV-B19, Persistent Infection in the immuno-compromised host, diagnosis and treatment.

## 2. GENOTYPES OF HUMAN PARVOVIRUS

The human erythroviruses are now classified into genotypes 1 (prototype), 2 (A6 and LaLi), and 3 (V9 and D91.1). It is now well established that there are three different genotypes, with approximately 10% variability at the DNA level between them. Furthermore, phylogenetic analysis has revealed two subgroups within genotypes 1 and 3. Analysis of 13 nearly full-length genotype 3 sequences from Ghana, Europe and Brazil identified two genetically distinct clusters. The classification of genotype 3 strains into two subtypes (3a and 3b) was proposed. The rate of evolutionary change of HPV-B19 genotype 3 strains ( $2 \times 10^{-4}$  nucleotide substitutions per site per year) was similar to those of the HPV-B19 genotype. The estimated divergence time between 3a and 3b was 525 years. In Ghana, subtype 3a was predominant [5]. Phylogenetic analysis of sub-genomic HPV-B19 genomes from Vietnam revealed two major subgroups within genotype 1 (1A and 1B) with an estimated nucleotide difference of >5% between each subgroup. The mean percentage of amino acid variation between subgroup HPV-B19-1A and HPV-B19-1B was >2% of the NS1, VP1 and VP2 proteins [6].

"The HPV-B19 genome contains two identical terminal repeats (ITRs) of approximately 380 nucleotides; these are imperfect palindromes and form hairpin loops. The terminal repeats of genotype-2 and genotype-3 have not been cloned and sequenced. The most striking variation is observed within the promoter area (~20%). Within the NS1 gene, sequence divergences between genotypes 2 and 3 and genotype 1 are ~13% at the nucleotide level. The amino acid sequence of the A6 and V9 NS1 proteins diverges from that of the prototype-encoded counterpart by 6.2% and 6.1 %, respectively. Within the open reading frame encoding the VP1/VP2 proteins, at the nucleotide level, genotypes 2 and 3 differ from the prototype by 9 and 12%, respectively, but at the amino acid level, they differ by only 1.1 and 1.4%. However, the degree of amino acid divergence within the VP1 unique region (uVP1) is higher; genotypes 2 and 3 differ from

genotype 1 by 4.4 and 6.6%, respectively. Interestingly, amino acids 130 to 195 of the VP1 gene containing the reported phospholipase 2 activities are highly conserved, and variation is mostly clustered in the N termini" [7]. "Despite the differences in the DNA sequences, the capsid protein sequence is conserved between the different genotypes, and there is evidence for both serologic and cross-neutralization" [8-10].

## 2.1 Transmission of HPV-B19

"The HPV-B19 infections in temperate climates occur in the spring, with small epidemics every few years being typical. Rates of infection may also increase every 3 to 4 years, as reflected by corresponding increases in the major clinical manifestations of HPV-B19 infection" [11,12].

## 2.2 Transmission through the Respiratory Route

"HPV-B19 DNA has been found in the respiratory secretions of patients at the time of viremia, suggesting that infection is generally spread by a respiratory route of transmission. The virus can be readily transmitted by close contact, and the secondary attack rate has been calculated in various settings. Young children are the main source of respiratory-acquired HPV-B19. Individuals at highest risk for acquiring the virus include household contacts of infected individuals, daycare workers, and those in a crowded environment" [13]. "Serologic studies are generally not available for school outbreaks, but 10% to 60% of students may develop a rash consistent with HPV-B19 infection. Workers in close contact with affected children, such as daycare providers and school personnel are at risk of the highest secondary attack rates and annual sero-conversion rates, even in the absence of known community outbreaks" [14].

## 2.3 Nosocomial Infections

HPV-B19 can be transmitted from patient-to-patient, patient-to staff, staff-to-patient and staff-to-staff. In one study, transmission from two patients with the transient aplastic crisis was noted in 36 and 42% of susceptible contacts [15]. In several other reports, no source for infection was identified, but transmission occurred between staff and patients. However, other studies did not find nosocomial transmission; in these studies, the rate of infection in exposed or at-risk staff was similar to unexposed staff and/or community controls. It is

therefore likely that many cases of presumed nosocomial transmission may represent infection acquired in the community during outbreaks of HPV-B19 [16,17]. "Patients with transient aplastic crisis or persistent disease should be considered infectious and appropriate precautions taken to limit interaction with other patients and susceptible staff" [18].

## 2.4 Transmission through Body Fluids

HPV-B19 has been reported to be transmitted by blood products, especially pooled components such as factor VIII and IX concentrates [19]. The virus can be found in serum, and infection can be transmitted by blood and blood products including albumin and plasma. Even though contaminated blood products can transmit parvovirus HPV-B19 Infection, there are no regulations governing HPV-B19 contamination of pooled plasma or blood products [20]. "Individuals requiring regular infusions of blood product(s) that are made from large plasma pools are at the greatest risk of acquiring the virus compared to those individuals receiving single units. Patients receiving less than 106 genome equivalent/mL have not shown evidence of virus transmission. The lack of a lipid envelope and the stable DNA genome make parvovirus notoriously resistant to heat inactivation and solvent detergents. They can withstand the usual thermal treatment aimed at infectious agents in blood products. In addition, solvent-detergent methods, which inactivate only lipid-enveloped viruses, are ineffective" [21].

## 2.5 Vertical Transmission

HPV-B19 can be transmitted from a mother to a foetus during her pregnancy. The risk of a poor outcome for the foetus is greatest when the congenital infection occurs within the first 20 weeks of gestation [22,23]. "Vertical transmission of HPV-B19 from a primarily infected mother may cause foetal infection. Pathogenic mechanisms include the development of acute anaemia upon infection of foetal hematopoietic cells. In early pregnancy, haematopoiesis is seen in the liver and later pregnancy this shifts to the bone marrow. The anaemia may resolve spontaneously or proceed by causing cardiac failure and development of hydrops fetalis and in rare cases foetal death. The virus may also cause myocarditis and cardiac arrest by direct infection of myocardial tissue.

## 2.6 Incubation Period and Infectivity

“Patients with HPV-B19 infection are most contagious during the phase of active viral replication and viral shedding. Viremia occurs approximately 5 to 10 days after exposure and usually lasts approximately 5 days, with virus titers peaking on the first few days of infection, which can reach or exceed 10<sup>12</sup> viral particles/mL of blood. During this phase, patients can be asymptomatic or present with non-specific flu-like illness. Immuno-compromised patients may underlying hematologic abnormalities can suffer severe anaemia. In immuno-competent hosts, there will be the production of B19V-specific antibodies followed by antigen-antibody immune complex formation occurs” [24]. At this point, “immuno-competent patients may present with specific symptoms or signs (e.g., arthralgia, arthritis, and/or an exanthema) of HPV-B19 infection. Individuals are no longer infectious when exhibiting these clinical characteristics. Immuno-compromised individuals who lack a detectable immune response to HPV-B19 may suffer from extended bouts of infection with measurable levels of the virus” [25]. The presence of detectable viremia in such patients without neutralizing antibody production may be assumed infectious.

## 3. PREVALENCE AND INCIDENCE

“Human Parvovirus B19 (HPV-B19) infections are reported from different parts of the globe”. The infectivity rates are similar, inferred from the presence of anti-parvovirus IgG antibodies in sera similar in the United States, Europe, Africa and Asia. HPV-B19 infection is common in childhood, and by the age of 15 years, approximately 50% of children have detectable immunoglobulin G (IgG) against HPV-B19. Infection also occurs in adult life, and more than 80% of elderly people have detectable antibodies” [26]. In the study by Jain et al. 67% of our healthy blood donors were having anti-HPV-B19 IgG in their serum below this level is achieved in the population by the age of 15 years [27]. In another study done by a large number of blood donors, 157/23,889 (0.66%) donors provided 347 HPV-B19 DNA-positive samples with a prevalence of 0.45% and incidence of 0.20%, although, HPV-B19 DNA concentrations were very low [28]. “Studies done in different countries (France, Germany, Japan, the United Kingdom, and the United States) show similar patterns of sero-prevalence, with significantly higher levels in parts of Africa and

Papua New Guinea, with >80% of 10-year-olds having detectable antibody” [29]. In one of the latest studies from Israel by Mor et al., the overall IgG prevalence was 61.4% and the age-adjusted prevalence rate was 58-2%. Seropositivity was significantly associated with age and showed the seasonal peak of B19V IgM positivity in June month of each year [30]. In another study from Sudan, ~ 61.0% of pregnant women were positive for anti-HPV-B19 IgG antibodies [31]. “In contrast, parts of Asia and some isolated tribal populations have a much lower prevalence” [32,33].

HPV-B19 infection persists throughout adult life, and the great majority of the elderly are seropositive. Although antibodies are prevalent in the general population, very high-titer viremia (>10<sup>7</sup> genome copies/mL) is rare. Researchers reported in a recent study that they were unable to detect HPV-B19 DNA in any of the blood donors using real-time PCR anti-HPV-B19 IgM [34]. “In contrast to that, approximately 1 per 20,000 to 1 per 40,000 units of blood during epidemic seasons contains high-titer HPV-B19 [35].

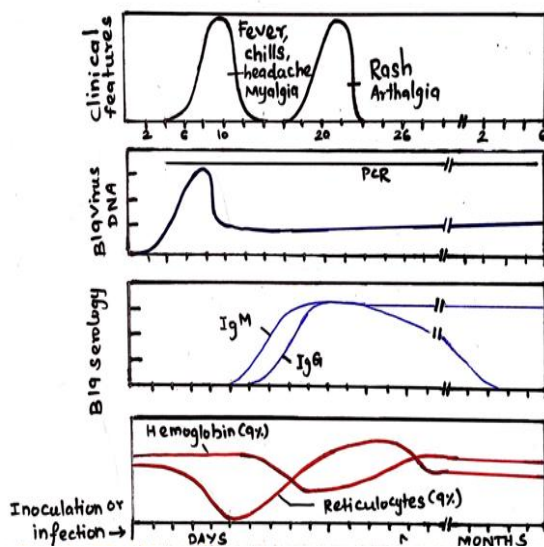
The virus though transmitted primarily through the respiratory route but is transmitted by blood and blood products also. The spread of the virus is very efficient in crowded areas by the respiratory route. The incubation period for the infection ranges from 4 days to 4 weeks with an average of 2 weeks. The symptomatic or asymptomatic infection in patients may last at least a week. Early childhood infections are common. It is primarily a human pathogen and is now distinctly associated with several human clinical conditions which include Fifth disease (erythema infectiosum), arthritis/arthralgia in adults, aplastic crisis and hydrops fetalis [36].

### 3.1 Diseases Caused/ Clinicopathological Associations

The association of HPV-B19 with clinical disease was made in the early 80s. Currently, HPV-B19 infection is shown to have a wide variety of disease manifestations. This varies dependent on the immunologic and hematologic status of the host. In HPV-B19 infections, about 25 percent of infected individuals would be asymptomatic, and 50 percent will have only nonspecific flu-like illness which presents with malaise, muscle pain, and fever. Febrile illness with rash (erythema infectiosum) and/or arthralgias is seen in about 25% of infected

individuals [37]. HPV-B19 is the cause of the fifth disease or "slapped cheek" disease i.e., erythema infectiosum which can be seen in normal immuno-competent children. Joint involvement is more common in adults (particularly women), though it could be seen in both children and adults. The illness could resemble rheumatoid arthritis clinically but is rheumatoid factor negative. Infection with HPV-B19 could lead to a transient reduction of red blood cell production and a transient aplastic crisis [38]. The association of the virus is strongly implicated in chronic anemia of ESRD. The virus is a documented cause of fetal hydrops due to its ability to cause chronic anemia in the fetus. The anemia associated with HPV-B19 could be exacerbated in children who acquire malaria or hookworm infestation [39]. Persistent DNAemia has been documented in immuno-competent individuals even in the presence of IgG [40].

The different clinical conditions, their nature and age of affliction caused by HPV-B19 are shown in Table 1. The details of the incubation period, clinical manifestations and the appearance of viral markers including antibody response and viral DNA are shown in Fig. 1.



**Fig. 1. Dynamics of HPV-B19 infection and viral markers (Reproduced from Anderson, et al., 1985)**

Joint symptoms are the most common manifestation in adults (Particularly women), although either can be seen in both children in adults (Table 1). Occasionally, especially in women, the fifth disease leads to an acute

symmetrical polyarthropathy, which can mimic rheumatoid arthritis.

"The humoral immune response is dominant in HPV-B19 infection. HPV-B19 specific IgM antibodies develop soon after infection, can be detected on days 10 through 12, and can persist for up to five months; specific IgG antibodies are detectable about 15 days post-infection and persist long-term dominant; development of a robust antibody response corresponds to virus clearance and subsequent protection from disease. Natural antibody production correlates with the disappearance of the virus from blood, and the presence of IgG appears to confer lasting protection against a second infection. HPV-B19 infection can persist if immunoglobulin production is defective such that antibody fails to neutralize the virus; reactivity of antibodies to the unique amino-terminal region of VP1 is especially important. Antibodies to VP1 are required for effective immune response" [41]. In patients unable to control HPV-B19 infection because of immuno-suppression or immunodeficiency, continued lysis of RBC precursors leads to the prolonged cessation of RBC production and the development of severe, chronic pure red cell aplasia and anemia.

### 3.2 Fifth Disease

HPV-B19 infections are generally asymptomatic. The infection in childhood primarily presents as erythema infectiosum or fifth disease. This is a febrile illness with a rash characterized by a "slapped cheek" finding. This illness has a prodrome phase characterized by fever, coryza, headache, nausea, and diarrhoea. In volunteers who were administered HPV-B19 intranasally typical influenza-like complaints occurred in the early phase along with demonstrable viremia. The rash seen after a week later coincided with the appearance of antiviral antibodies. Volunteers who showed a biphasic illness had arthralgia in the second phase [42].

The HPV-B19 produces a rash-like illness that is immune-mediated. The individuals show serum antibodies at the time of appearance of the rash. The clinical condition resolves in a few weeks but can rarely be chronic lasting several years [43]. Among children erythema, infectiosum should be considered as a differential diagnosis for rubella. The rash is not very typical among adults and is difficult to spot in dark-skinned individuals [44]. The clinical features seen in children with HPV-B19 are shown in Table 2.

summarizes all clinical conditions that this infection is associated with. Some of the associated symptoms of various clinical manifestations of HPV-B19 infection are shown in Table 3.

**Table 1. Clinical conditions of HPV-B19 infection**

Disease	Acute or chronic	Host
Fifth disease	Acute	Normal children
Polyarthropathy syndrome	Acute or chronic	Normal adults
Transient aplastic crisis	Acute	Immuno-compromised patients
Hydrops fetalis or congenital anaemia	Acute or chronic	Foetus (<20 wk.)
Persistent anaemia	Chronic	Immunodeficient immuno-compromised patients

*\*Adapted from Heegaard and Brown, (2002), 'Human Parvovirus B19', Clin Microbiol Rev 15(3), 485-505*

**Table 2. Range of HPV-B19 signs and symptoms in children**

Signs and Symptoms	Percent affected
Fever	14 to 53
Headache	12 to 53
Sore throat	12 to 60
Pruritus	0 to >50
Cough	5 to 40
Diarrhea	0 to 40
Nausea and/or vomiting	0 to 33
Coryza and/or conjunctivitis	4 to 27
Arthralgia and/or arthritis	0 to 9

*Adapted from Anderson, L.J. Pediatr Infect Dis J 1987, 6:711*

**Table 3. Clinical manifestations of HPV-B19 infection**

Diseases	Organ	Patients
<b>Most common manifestations</b>		
Asymptomatic B19 Infection	-	Adults
Erythema infectiosum (fifth disease)	Cheek	Children
Arthralgia (acute arthritis)	Joints	Adults
Hydrops fetalis	Liver and endothelial cells	Foetus
Pure red blood cell anaemia (PRCA)	Bone Marrow	Adults
Transient aplastic crisis	Bone Marrow	Adults
<b>Rare syndromes</b>		
Congenital red cell aplasia	Liver	Foetus
Chronic bone marrow failure	Bone marrow	Adults
Encephalitis	CNS	Children
Kawasaki disease	Skin and Muscle	Children
Myocarditis/Heart failure	Myocardium	Infants
Pruritus	Nerves, Fingers and Toes	Adults
Vasculitis	Endothelial Cells	Adults, Children
<b>Others (causality unconfirmed)</b>		
Chronic fatigue syndrome	Smooth Muscle	Adults
Congenital malformation	Palate	Infants
Conjunctivitis	Conjunctiva	Adults
Hepatic dysfunction/Hepatitis	Liver	Adults
Kikuchi's disease	Lymphoid Tissue	Children
Nephritis/Glomerulonephritis	Kidney	Adults
Systemic lupus erythematosus	Connective Tissue	Adults

### 3.3 HPV-B19 Arthralgia/Arthropathy

The condition is a complication seen in adults, especially in women wherein inflammatory arthritis can be seen. It is estimated that 15% of all reactive arthritis may be attributed to HPV-B19 infection. The clinical condition may resemble rheumatoid arthritis. HPV-B19 arthropathy resolves without specific antiviral therapy and no inflammatory damage to joints but could increase the severity of rheumatologic diseases. These include juvenile rheumatoid arthritis, systemic lupus erythematosus, and fibromyalgia [45, 46].

### 3.4 Transient Aplastic Crisis

This condition is linked to HPV-B19. If there exist haemolytic disorders, the outcome of the infection could be adverse. The predisposing conditions for poor outcomes include hereditary spherocytosis, thalassemia, red cell enteropathies such as pyruvate kinase deficiency, and autoimmune haemolytic anaemia [47]. The virus hence may be an opportunistic pathogen in an individual's post- bone marrow transplant. The infection can lead to acute aplastic crisis. "In a study of 308 patients with homozygous sickle cell disease, acute infection with HPV-B19 was documented in 114 patients, of whom 91 (80 percent) developed transient aplastic crises" [12].

It is observed that when viremia seen in transient aplastic crisis disappears, the red cell production resumes. This coincides with the appearance of antibodies. There is evidence for protective immunity which is long-lasting. The anemia may be a precipitating factor for congestive heart failure and cerebrovascular accidents. In a transient aplastic crisis, the bone marrow typically shows immature erythroid precursors "giant pronormoblasts" which is due to the direct toxicity effects of the virus. HPV-B19 has been linked to agranulocytosis, thrombocytopenia and pancytopenia [47].

### 3.5 Hydrops Fetalis

Early maternal infection results in the transplacental transfer of the virus to the fetus which affects RBC production. This results in severe anemia which is the cause of fetal hydrops. The fetal wastage is because of myocarditis and congestive heart failure in the fetus. In prospective studies, the risk has been estimated to be 30% to the fetus of the mother

infected in early pregnancy. Fetal wastage is seen in 9% of infected mothers. Infection later in pregnancy is associated with non-immune fetal hydrops. Infection in the third trimester is associated with abortion. Typically, congenital malformations have not been reported unlike in the case of CMV or Rubella virus infection. Infants affected by red cell crisis may be given in-utero blood transfusions or exchange transfusions at birth [48].

### 3.6 Other Syndromes Associated with HPV-B19

There is evidence for the role of HPV-B19 in hepatitis seen in young children as well as myocarditis. Altered liver enzymes are typically seen in the affected children. There is serological evidence as well as DNAemia in children with other conditions like necrotizing vasculitis, Kawasaki disease, Henoch-Schonlein purpura, Giant cell arteritis, Glove-and-sock syndrome (an exanthema localized to the hands and feet consisting of edema, erythema, paraesthesia and pruritus). Occasionally, CNS complications like meningitis and encephalitis may be seen in the fifth disease. HPV-B19 has been documented in hematological malignancies/ solid tumors [49].

### 3.7 Persistent Infection in the Immuno-Compromised Host

Infection in immuno-compromised individuals is characterized by chronicity especially involving the bone marrow. Erythroid precursors are affected which manifests as an aplastic crisis. Typically, the bone marrow picture shows joint pronormoblasts. Antibody to HPV-B19 may not be demonstrable but viral DNA is positive in blood with high viral loads [50].

### 3.8 Diagnosis of HPV-B19 Infection

The infection is established by serology and/or viral genome demonstration. Acute infection is documented by IgM demonstration and/or detection of viral DNA in the blood/sera of infected individuals. Precious exposure to the virus is shown by specific IgG. The widely used serological tests are ELISA based and genome demonstration is by nested PCR or real-time PCR. Virus load estimation is by quantitative real-time PCR [51,52]. The cellular location of HPV-B19 has been shown for antigen using an indirect immunofluorescence assay. This is not a

clinically useful test [53]. The Indian literature indicates the use of serological assays for some HPV-B19 studies. There are several limitations with such IgG and IgM antibody-based studies. A direct link between virus activity and several of these disease conditions is better established with documentation of viral genomic DNA by PCR.

### 3.9 Available Treatment for Human Parvovirus B-19

There is no specific antiviral therapy. An infection resolves spontaneously in immuno-competent individuals but could be chronic in immuno-compromised individuals. However, intravenous immunoglobulin (IVIG, which could contain a large amount of anti- HPV-B19 IgG) is a preferred treatment for aplastic anemia [54]. The dosage is at 0.4 g/kg body weight given for a maximum of 10 days. This results in the clearance of DNAemia [55]. Some patients recover spontaneously without treatment [56]. As mentioned previously, intrauterine blood transfusions have been used for suspected cases of hydrops details.

“More recently, cidofovir has been used successfully to suppress HPV-B19 replication (real-time PCR for viral DNA) in two model systems, the UT7/EpoS1 cell line and erythroid progenitor cells (EPC), generated from Peripheral Blood Mononuclear Cells (PBMC). The investigators showed dose-dependent inhibitory activity in infected UT7/EpoS1, for the determination of EC50 and EC90 values (7.45-41.27  $\mu$ M, and 84.73-360.7  $\mu$ M, respectively)” [57]. “The clinical and laboratory signs of HPV-B19 infection and corresponding therapeutic strategies are dependent on host factors and underlying clinical disorders” [58]. For example, the pathogenesis in the HPV-B19-infected foetus is a result of the physiologically higher red blood cell turnover and the relative immunodeficiency of the foetus. It must be pointed out that the infection resolves spontaneously in many cases in all risk groups and treatment is therefore only given to severe cases” [59].

## 4. CONCLUSION

Parvovirus B19 infection is related with a wide range of clinical signs of which some are deeply grounded and some of which are still questionable. A cautious thought of clinical features, serological aspects and epidemiology survey is necessary to direct the clinicians in

decision making on diagnostic and treatment. Parvovirus B19 infection role is as to trigger of glomerular illness presently can't seem to be solidly settled however merits further consideration since it might have suggestions in counteraction methodologies and treatment. While most virally interceded arthritis's are self-restricting some warrant the commencement of explicit antiviral treatment. Parvovirus B19 therapy includes red-cell transfusion, alterations in medications and management if intravenous immuno-globulin. Our review will be helpful to understanding the clinical signs, epidemiology, diagnostic capability and treatment in the management of HPV-B19.

## CONSENT

It's not applicable.

## ETHICAL APPROVAL

It's not applicable.

## COMPETING INTERESTS

Authors have declared that no competing interests exist.

## REFERENCES

1. Ozeki M, Fukushima T, Ohzeki M, Sasaki T, Kashihara N. A nosocomial parvovirus B19 infection-induced transient aplastic crisis in a patient with chronic renal failure. *Clin Nephrol.* 2006;65(2):141-3. PMID: 16509466. DOI: 10.5414/cnp65141
2. Pedranti MS, Barbero P, Wolff C, Ghiotto LM, Zapata M, Adamo MP. Infection and immunity for human parvovirus B19 in patients with febrile exanthema. *Epidemiol Infect.* 2012;140(3):454-61. Epub 2011 May 18. PMID: 21676356. DOI: 10.1017/S0950268811000823
3. Kerr JR. Pathogenesis of human parvovirus B19 in rheumatic disease. *Ann Rheum Dis.* 2000;59(9):672-83. PMID: 10976079; PMCID: PMC1753262. DOI: 10.1136/ard.59.9.672
4. Kerr JR, Tyrrell DA. Cytokines in parvovirus B19 infection as an aid to understanding chronic fatigue syndrome. *Curr Pain Headache Rep.* 2003;7(5):333-41. PMID: 12946285. DOI: 10.1007/s11916-003-0031-3



5. Zádori Z, Szelei J, Lacoste MC, Li Y, Gariépy S, Raymond P, et al. A viral phospholipase A2 is required for parvovirus infectivity. *Dev Cell*. 2001; 1(2):291-302. PMID: 11702787. DOI: 10.1016/s1534-5807(01)00031-4
6. Parsyan A, Szmaragd C, Allain JP, Candotti D. Identification and genetic diversity of two human parvovirus B19 genotype 3 subtypes. *J Gen Virol*. 2007;88(Pt 2):428-431. PMID: 17251559. DOI: 10.1099/vir.0.82496-0
7. Toan NL, Duechting A, Kreamsner PG, Song LH, Ebinger M, Aberle S, et al. Phylogenetic analysis of human parvovirus B19, indicating two subgroups of genotype 1 in Vietnamese patients. *J Gen Virol*. 2006;87(Pt 10):2941-2949. PMID: 16963753. DOI: 10.1099/vir.0.82037-0
8. Dorsch S, Liebisch G, Kaufmann B, von Landenberg P, Hoffmann JH, Drobnik W, et al. The VP1 unique region of parvovirus B19 and its constituent phospholipase A2-like activity. *J Virol*. 2002;76(4):2014-8. PMID: 11799199; PMCID: PMC135890. DOI: 10.1128/jvi.76.4.2014-2018.2002
9. Tolfvenstam T, Rudén U, Broliden K. Evaluation of serological assays for identification of parvovirus B19 immunoglobulin M. *Clin Diagn Lab Immunol*. 1996;3(2):147-50. PMID: 8991627; PMCID: PMC170264. DOI: 10.1128/cdli.3.2.147-150.1996
10. Corcoran A, Doyle S, Allain JP, Candotti D, Parsyan A. Evidence of serological cross-reactivity between genotype 1 and genotype 3 erythrovirus infections. *J Virol*. 2005;79(8):5238-9. PMID: 15795309; PMCID: PMC1069586. DOI: 10.1128/JVI.79.8.5238-5239.2005
11. Srivastava A, Lu L. Replication of B19 parvovirus in highly enriched hematopoietic progenitor cells from normal human bone marrow. *J Virol*. 1988;62(8):3059-63. PMID: 3392774; PMCID: PMC253750. DOI: 10.1128/JVI.62.8.3059-3063.1988
12. Kelly HA, Siebert D, Hammond R, Leydon J, Kiely P, Maskill W. The age-specific prevalence of human parvovirus immunity in Victoria, Australia compared with other parts of the world. *Epidemiol Infect*. 2000;124(3):449-57. PMID: 10982069; PMCID: PMC2810931. DOI: 10.1017/s0950268899003817
13. Serjeant GR, Serjeant BE, Thomas PW, Anderson MJ, Patou G, Pattison JR. Human parvovirus infection in homozygous sickle cell disease. *Lancet*. 1993;341(8855):1237-40. PMID: 8098391. DOI: 10.1016/0140-6736(93)91145-c
14. Harrison J, Jones CE. Human parvovirus B19 infection in healthcare workers. *Occup Med (Lond)*. 1995;45(2):93-6. PMID: 7718826. DOI: 10.1093/occmed/45.2.93
15. Gillespie SM, Cartter ML, Asch S, Rokos JB, Gary GW, Tsou CJ, et al. Occupational risk of human parvovirus B19 infection for school and day-care personnel during an outbreak of erythema infectiosum. *JAMA*. 1990;263(15):2061-5. PMID: 2157074.
16. Bell LM, Naides SJ, Stoffman P, Hodinka RL, Plotkin SA. Human parvovirus B19 infection among hospital staff members after contact with infected patients. *N Engl J Med*. 1989; 321(8):485-91. PMID: 2548096. DOI: 10.1056/NEJM198908243210801
17. Dowell SF, Török TJ, Thorp JA, Hedrick J, Erdman DD, Zaki SR, et al. Parvovirus B19 infection in hospital workers: Community or hospital acquisition? *J Infect Dis*. 1995;172(4):1076-9. PMID: 7561182. DOI: 10.1093/infdis/172.4.1076
18. Ray SM, Erdman DD, Berschling JD, Cooper JE, Török TJ, Blumberg HM. Nosocomial exposure to parvovirus B19: Low risk of transmission to healthcare workers. *Infect Control Hosp Epidemiol*. 1997;18(2):109-14. PMID: 9120238. DOI: 10.1086/647564
19. Azzi A, Morfini M, Mannucci PM. The transfusion-associated transmission of parvovirus B19. *Transfus Med Rev*. 1999;13(3):194-204. PMID: 10425692. DOI: 10.1016/s0887-7963(99)80033-9
20. Seng C, Watkins P, Morse D, Barrett SP, Zambon M, Andrews N, et al. Parvovirus B19 outbreak on an adult ward. *Epidemiol Infect*. 1994;113(2):345-53. PMID: 7925671; PMCID: PMC2271527. DOI: 10.1017/s0950268800051773
21. Jordan J, Tiangco B, Kiss J, Koch W. Human parvovirus B19: Prevalence of viral DNA in volunteer blood donors and clinical outcomes of transfusion recipients. *Vox Sang*. 1998;75(2):97-102. PMID: 9784661.
22. Yu MY, Alter HJ, Virata-Theimer ML, Geng Y, Ma L, Schechterly CA, et al. Parvovirus

- B19 infection transmitted by transfusion of red blood cells confirmed by molecular analysis of linked donor and recipient samples. *Transfusion*. 2010;50(8):1712-21. Epub 2010 Feb 12. PMID: 20158689; PMCID: PMC5547753.  
DOI: 10.1111/j.1537-2995.2010.02591.x
23. Cartter ML, Farley TA, Rosengren S, Quinn DL, Gillespie SM, Gary GW, et al. Occupational risk factors for infection with parvovirus B19 among pregnant women. *J Infect Dis*. 1991;163(2):282-5. PMID: 1846391.  
DOI: 10.1093/infdis/163.2.282
  24. Jordan JA. Identification of human parvovirus B19 infection in idiopathic nonimmune hydrops fetalis. *Am J Obstet Gynecol*. 1996;174(1 Pt 1):37-42. PMID: 8572031  
DOI: 10.1016/s0002-9378(96)70370-8
  25. Broliden K, Tolfvenstam T, Norbeck O. Clinical aspects of parvovirus B19 infection. *J Intern Med*. 2006;260(4):285-304. PMID: 16961667.  
DOI: 10.1111/j.1365-2796.2006.01697.x
  26. Flunker G, Peters A, Wiersbitzky S, Modrow S, Seidel W. Persistent parvovirus B19 infections in immunocompromised children. *Med Microbiol Immunol*. 1998;186(4):189-94. PMID: 9574901.  
DOI: 10.1007/s004300050063
  27. Röhrer C, Gärtner B, Sauerbrei A, Böhm S, Hottenträger B, Raab U, et al. Seroprevalence of parvovirus B19 in the German population. *Epidemiol Infect*. 2008;136(11):1564-75. Epub 2008 Jan 16. PMID: 18198003; PMCID: PMC2870752  
DOI: 10.1017/S0950268807009958
  28. Jain P, Jain A, Prakash S, Khan DN, Singh DD, Kumar A, et al. Prevalence and genotypic characterization of human parvovirus B19 in children with hematological disorders in North India. *J Med Virol*. 2015;87(2):303-9. Epub 2014 Aug 2. PMID: 25087946.  
DOI: 10.1002/jmv.24028
  29. Juhl D, Steppat D, Görg S, Hennig H. Parvovirus b19 infections and blood counts in blood donors. *Transfus Med Hemother*. 2014;41(1):52-9. Epub 2013 Dec 30. PMID: 24659948; PMCID: PMC3949617.  
DOI: 10.1159/000357650
  30. Wildig J, Mueller I, Kiniboro B, Maraga S, Siba P, Cossart Y. Seroprevalence of antibodies to parvovirus B19 among children in Papua New Guinea. *Am J Trop Med Hyg*. 2007;77(2):354-7. PMID: 17690412
  31. Mor O, Ofir I, Pavel R, Bassal R, Kra-Oz Z, Cohen D, et al. Parvovirus B19V infection in Israel: prevalence and occurrence of acute infection between 2008 and 2013. *Epidemiol Infect*. 2016;144(1):207-14. Epub 2015 May 20. PMID: 25990962; PMCID: PMC9507271.  
DOI: 10.1017/S0950268815000230
  32. Adam O, Makkawi T, Reber U, Kirberg H, Eis-Hübinger AM. The seroprevalence of parvovirus B19 infection in pregnant women in Sudan. *Epidemiol Infect*. 2015;143(2):242-8. Epub 2014 Mar 20. PMID: 24650427; PMCID: PMC9206789.  
DOI: 10.1017/S0950268814000600
  33. Ke L, He M, Li C, Liu Y, Gao L, Yao F, et al. The prevalence of human parvovirus B19 DNA and antibodies in blood donors from four Chinese blood centers. *Transfusion*. 2011;51(9):1909-18. Epub 2011 Mar 7. PMID: 21382040.  
DOI: 10.1111/j.1537-2995.2011.03067.x
  34. de Freitas RB, Wong D, Boswell F, de Miranda MF, Linhares AC, Shirley J, et al. Prevalence of human parvovirus (B19) and rubella virus infections in urban and remote rural areas in northern Brazil. *J Med Virol*. 1990;32(4):203-8. PMID: 1964474  
DOI: 10.1002/jmv.1890320402
  35. Jain P, Jain A, Prakash S, Khan DN, Singh DD, Kumar A, et al. Prevalence and genotypic characterization of human parvovirus B19 in children with hematological disorders in North India. *J Med Virol*. 2015;87(2):303-9. Epub 2014 Aug 2. PMID: 25087946.  
DOI: 10.1002/jmv.24028
  36. Juhl D, Steppat D, Görg S, Hennig H. Parvovirus b19 infections and blood counts in blood donors. *Transfus Med Hemother*. 2014;41(1):52-9. Epub 2013 Dec 30. PMID: 24659948; PMCID: PMC3949617  
DOI: 10.1159/000357650
  37. Ros C, Gerber M, Kempf C. Conformational changes in the VP1-unique region of native human parvovirus B19 lead to exposure of internal sequences that play a role in virus neutralization and infectivity. *J Virol*. 2006;80(24):12017-24. Epub 2006 Oct 4. PMID: 17020940; PMCID: PMC1676260.  
DOI: 10.1128/JVI.01435-06

38. Woolf AD, Campion GV, Chishick A, Wise S, Cohen BJ, Klouda PT, et al. Clinical manifestations of human parvovirus B19 in adults. *Arch Intern Med.* 1989;149(5):1153-6. PMID: 2541666
39. Chorba T, Coccia P, Holman RC, Tattersall P, Anderson LJ, Sudman J, et al. The role of parvovirus B19 in aplastic crisis and erythema infectiosum (fifth disease). *J Infect Dis.* 1986;154(3):383-93. PMID: 3016109.  
DOI: 10.1093/infdis/154.3.383
40. Wildig J, Michon P, Siba P, Mellombo M, Ura A, Mueller I, et al. Parvovirus B19 infection contributes to severe anemia in young children in Papua New Guinea. *J Infect Dis.* 2006;194(2):146-53. Epub 2006 Jun 14. PMID: 16779719.  
DOI: 10.1086/505082
41. Lefrère JJ, Servant-Delmas A, Candotti D, Mariotti M, Thomas I, Brossard Y, et al. Persistent B19 infection in immunocompetent individuals: Implications for transfusion safety. *Blood.* 2005;106(8):2890-5. Epub 2005 Jun 23. PMID: 15976179.  
DOI: 10.1182/blood-2005-03-1053
42. Young NS, Brown KE. Parvovirus B19. *N Engl J Med.* 2004;350(6):586-97. PMID: 14762186. DOI: 10.1056/NEJMra030840
43. Anderson MJ, Higgins PG, Davis LR, Willman JS, Jones SE, Kidd IM, et al. Experimental parvoviral infection in humans. *J Infect Dis.* 1985; 152(2):257-65. PMID: 2993431.  
DOI: 10.1093/infdis/152.2.257
44. Lindblom A, Isa A, Norbeck O, Wolf S, Johansson B, Broliden K, et al. Slow clearance of human parvovirus B19 viremia following acute infection. *Clin Infect Dis.* 2005;41(8):1201-3. Epub 2005 Sep 2. PMID: 16163641.  
DOI: 10.1086/444503
45. Lowry SM, Brent LH, Menaldino S, Kerr JR. A case of persistent parvovirus B19 infection with bilateral cartilaginous and ligamentous damage to the wrists. *Clin Infect Dis.* 2005;41(4):e42-4. Epub 2005 Jul 14. PMID: 16028146  
DOI: 10.1086/432118
46. White DG, Woolf AD, Mortimer PP, Cohen BJ, Blake DR, Bacon PA. Human parvovirus arthropathy. *Lancet.* 1985;1(8426):419-21. PMID: 2857804.  
DOI: 10.1016/s0140-6736(85)91145-6
47. Serjeant BE, Hambleton IR, Kerr S, Kilty CG, Serjeant GR. Haematological response to parvovirus B19 infection in homozygous sickle-cell disease. *Lancet.* 2001;358(9295):1779-80. PMID: 11734237.  
DOI: 10.1016/S0140-6736(01)06807-6
48. Young NS. Hematologic manifestations and diagnosis of parvovirus B19 infections. *Clin Adv Hematol Oncol.* 2006;4(12):908-10. PMID: 17235275.
49. Musiani M, Pasini P, Zerbini M, Gentilomi G, Roda A, Gallinella G, et al. Prenatal diagnosis of parvovirus B19-induced hydrops fetalis by chemiluminescence in situ hybridization. *J Clin Microbiol.* 1999;37(7):2326-9. PMID: 10364606; PMCID: PMC85149.  
DOI: 10.1128/JCM.37.7.2326-2329.1999
50. Ramirez MM, Mastrobattista JM. Diagnosis and management of human parvovirus B19 infection. *Clin Perinatol.* 2005 Sep; 32(3):697-704. PMID: 16085027.  
DOI: 10.1016/j.clp.2005.04.003
51. Grabarczyk P, Kalińska A, Kara M, Wieczorek R, Ejduk A, Sulkowska E, et al. Identification and characterization of acute infection with parvovirus B19 genotype 2 in immunocompromised patients in Poland. *J Med Virol.* 2011;83(1):142-9. PMID: 21108352.  
DOI: 10.1002/jmv.21947
52. Jordan JA. Diagnosing human parvovirus B19 infection: Guidelines for test selection. *Mol Diagn.* 2001;6(4):307-12. PMID: 11774195.  
DOI: 10.1054/modi.2001.28632
53. Manaresi E, Gallinella G, Zuffi E, Bonvicini F, Zerbini M, Musiani M. Diagnosis and quantitative evaluation of parvovirus B19 infections by real-time PCR in the clinical laboratory. *J Med Virol.* 2002;67(2):275-81. PMID: 11992590.  
DOI: 10.1002/jmv.2218
54. Poole BD, Karenyi YV, Naides SJ. Parvovirus B19-induced apoptosis of hepatocytes. *J Virol.* 2004;78(14):7775-83. PMID: 15220451; PMCID: PMC434113.  
DOI: 10.1128/JVI.78.14.7775-7783.2004
55. Kurtzman G, Frickhofen N, Kimball J, Jenkins DW, Nienhuis AW, Young NS. Pure red-cell aplasia of 10 years' duration due to persistent parvovirus B19 infection and its cure with immunoglobulin therapy. *N Engl J Med.* 1989;321(8):519-23. PMID: 2548098  
DOI: 10.1056/NEJM198908243210807

56. Crabol Y, Terrier B, Rozenberg F, Pestre V, Legendre C, Hermine O, et al; Groupe d'experts de l'Assistance Publique-Hôpitaux de Paris. Intravenous immunoglobulin therapy for pure red cell aplasia related to human parvovirus b19 infection: a retrospective study of 10 patients and review of the literature. Clin Infect Dis. 2013;56(7):968-77. Epub 2012 Dec 12. PMID: 23243178. DOI: 10.1093/cid/cis1046
57. Garewal G, Ahluwalia J, Das R, Marwaha RK. Parvovirus B19-associated transient red cell aplasia in children: The role of bone marrow examination in unusual presentations. Pediatr Hematol Oncol. 2004;21(6):505-11. PMID: 15552814. DOI: 10.1080/08880010490477293
58. Broliden K, Tolfvenstam T, Norbeck O. Clinical aspects of parvovirus B19 infection. J Intern Med. 2006;260(4):285-304. PMID: 16961667. DOI: 10.1111/j.1365-2796.2006.01697.x
59. Bonvicini F, Bua G, Manaresi E, Gallinella G. Antiviral effect of cidofovir on parvovirus B19 replication. Antiviral Res. 2015; 113:11-8. Epub 2014 Nov 13. PMID: 25446336. DOI: 10.1016/j.antiviral.2014.11.004

© 2022 Vadivel et al.; This is an Open Access article distributed under the terms of the Creative Commons Attribution License (<http://creativecommons.org/licenses/by/4.0>), which permits unrestricted use, distribution, and reproduction in any medium, provided the original work is properly cited.

*Peer-review history:*  
*The peer review history for this paper can be accessed here:*  
<https://www.sdiarticle5.com/review-history/94102>