



# Giant Pancreatic Pseudocyst Complicating Twin Pregnancy with Spontaneous Resolution: Case Report

Abdelilah El Bakouri <sup>a</sup>, Abderrahmane Lamnaouar <sup>a</sup>, Khalid Jamaledine <sup>b,\*,</sup>,  
Mounir Bouali <sup>c</sup>, Khalid Elhattabi <sup>d</sup>, Fatimazahra Bensardi <sup>a</sup>  
and Abdelaziz Fadil <sup>a</sup>

<sup>a</sup> Department of Visceral Surgery, University Hospital Center Ibn Rochd, Faculty of Medicine and Pharmacy, Hassan II University, Casablanca, Morocco.

<sup>b</sup> Emergency Department, University Hospital Center Ibn Rochd, Faculty of Medicine and Pharmacy, Hassane II University, Casablanca, Morocco.

<sup>c</sup> Department of General Surgery, University Hospital Center Ibn Rochd, Faculty of Medicine and Pharmacy, Hassan II University, Casablanca, Morocco.

<sup>d</sup> Department of Visceral Surgical Emergencies, University Hospital Center Ibn Rochd, Faculty of Medicine and Pharmacy, Hassan II University, Casablanca, Morocco.

## Authors' contributions

This work was carried out in collaboration among all authors. All authors read and approved the final manuscript.

## Article Information

### Open Peer Review History:

This journal follows the Advanced Open Peer Review policy. Identity of the Reviewers, Editor(s) and additional Reviewers, peer review comments, different versions of the manuscript, comments of the editors, etc are available here: <https://www.sdiarticle5.com/review-history/92549>

Case Study

Received 19 August 2022  
Accepted 21 October 2022  
Published 28 October 2022

## ABSTRACT

Pancreatic pseudocyst during pregnancy is a rare pathology whose management lacks of hindsight, with only 10 cases reported in the literature since 1980. Spontaneous resolution in 11 to 16% of cases has been described in the literature.

We report a case of giant pseudocyst of the pancreas during pregnancy spontaneously resolving. A 19-year-old pregnant female presented with giant pancreatic pseudocysts which was managed conservatively, evolving towards a spontaneous resolution after delivery.

**Keywords:** Pancreatic pseudocyst; pregnancy; resolution.

<sup>o</sup>General Surgery Resident;

\*Corresponding author: E-mail: drkhalidjamaledine@gmail.com;

## 1. INTRODUCTION

Pancreatic pseudocysts are liquid collections without a distinct epithelial wall, developed at the edge of or in contact with the pancreas, containing pure pancreatic fluid or mixed with necrotic debris; following an inflammatory process such as Pancreatitis (mainly from an unknown etiology) or Trauma [1].

Pancreatic pseudocysts are common complication of pancreatitis. However, few cases of giant pancreatic pseudocysts, which measure 10 cm or more in widest diameter, have been described. During pregnancy, the management of this rare condition is not standardized [2].

## 2. CASE REPORT

A 19-year-old female in the 24th week of her first twin pregnancy with a past medical history of undocumented abdominal trauma within the last 7 months, presented a one week of intermittent epigastric abdominal gravity-type pain with radiation to her back and nausea. The clinical examination found a conscious patient, hemodynamically and respiratory stable, without clinical cholestasis.

The abdominal examination shows a hard, slightly tender epigastric mass, fixed in relation to the deep plane measuring 20 cm in diameter. The rest of the somatic examination, including cardiovascular and pleuropulmonary examination, was normal.

An ultrasound scan was performed showing large cystic formations occupying all portions of the pancreas, communicating with each other, containing thickened partitions and walls. They measure 120\*90 mm and 50\*48 mm. It also showed a monochorionic biamniotic intrauterine pregnancy.

MRI revealed a large cystic formation measuring 19 cm in diameter at the expense of the whole pancreas which only the distal part of the tail remains, with homogeneous content. Nothing else was reported on this scanner. The tracing of the electrocardiogram was normal.

Tumor markers noted an elevated CA19.9 at 79, 4 IU/ml and a normal ACE at 0,9ng/ml. The lipasemia was normal.

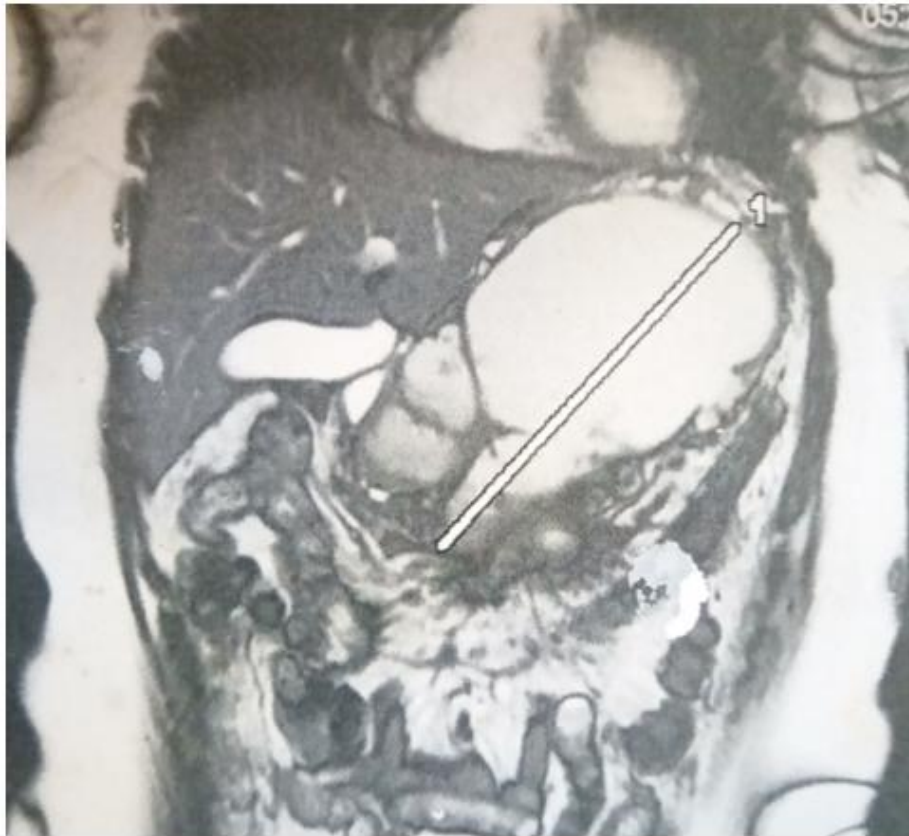
A cytological and biochemical study of the fluid from the ultrasound-guided puncture of the pancreatic cyst was performed, showing an inflammatory fluid without tumor cells, with amylase level at 4921IU/L and lipase level at 349IU/L.

After the disappearance of the symptoms following digestive rest and parenteral feeding as well as symptomatic treatment, the patient benefited from a regular follow-up until the delivery.

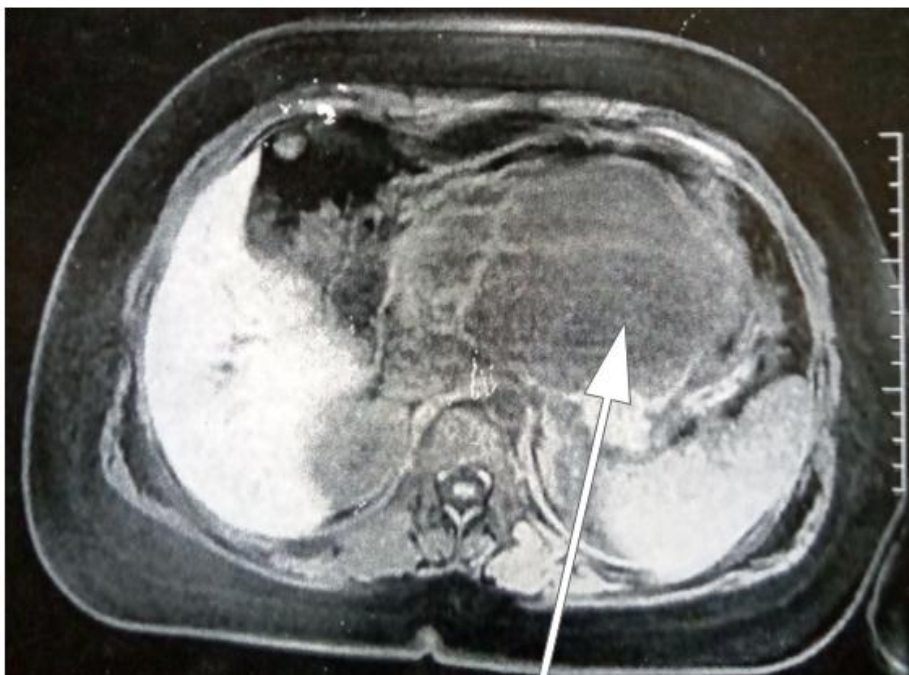
6 months later, an abdominal CT scan was performed, showing a normal-looking pancreas.

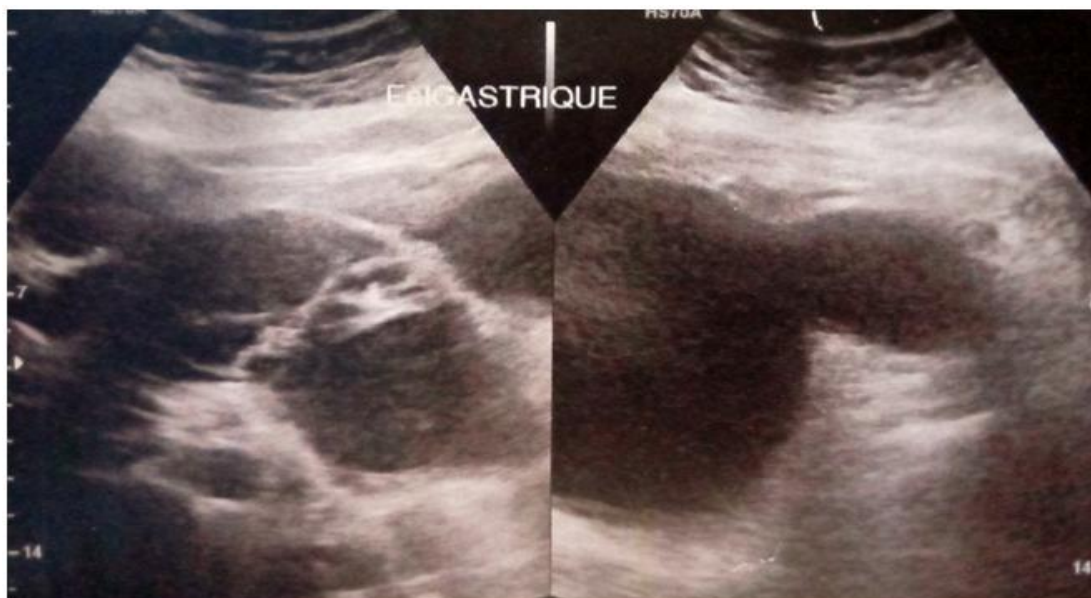

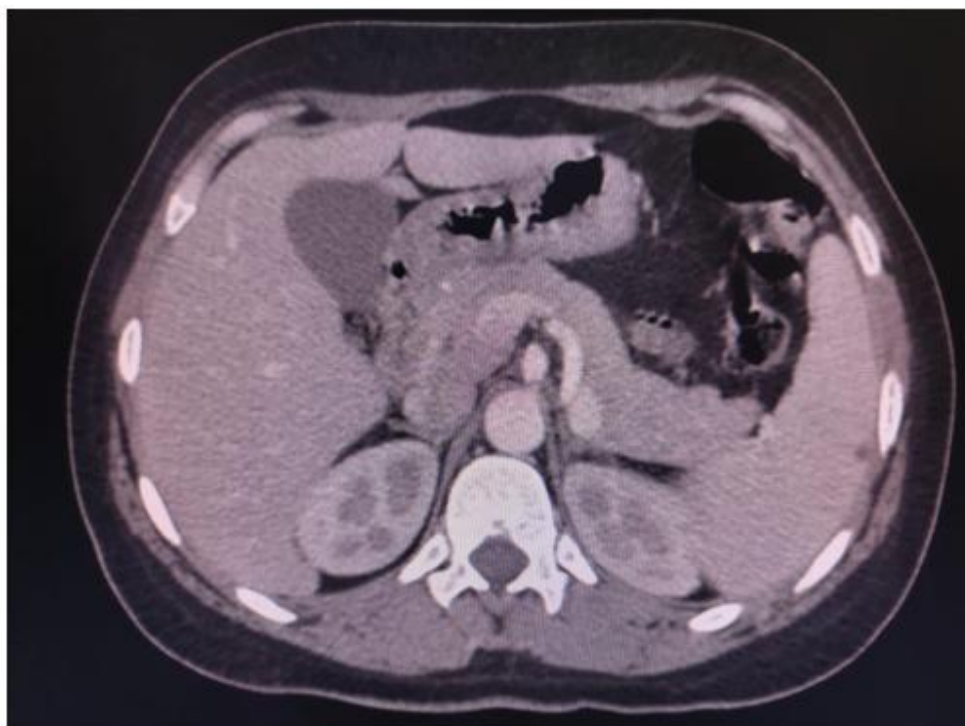Fig. 1. Large cystic formations occupying all portions of the pancreas



**Fig. 2. T2 coronal slice MRI showing large pancreatic cystic formation**



**Fig. 3. Diffusion axial slice MRI showing large pancreatic cystic formation**



**Fig. 4. Axial slice MRI showing a normal pancreas**

### 3. DISCUSSION

“Pancreatic secretions accumulate in the peri-pancreatic tissues when the main duct of the pancreas or one of the ductal branches is ruptured. Most of these accumulations resolve spontaneously. However, in some cases, the accumulation of fluid persists, and the inflammatory process forms a fibrous wall around the fluid that does not have normal epithelialization, so it is called a pseudocyst” [2-3]. “The synonyms of huge or large are used in the scientific reports of giant pseudocysts” [4].

“The incidence of pancreatic pseudocysts is low at 0.5–1/100 000 adults per year, with spontaneous resolution in 11% to 16% of cases is reported in the literature [5]. Approximately 30%-40% are complicated by infection, rupture, hemorrhage or obstruction of the stomach, small bowel, colon, or bile duct” [6].

“The natural history of pancreatic pseudocysts in pregnancy appears similar to nonpregnant patients. Pancreatic pseudocysts present a clinical polymorphism. Some may be completely asymptomatic while others may present with features of biliary tract obstruction. The most common clinical manifestations are abdominal

swelling, pain, nausea and vomiting. Others include early satiety and weight loss” [7].

“Diagnostic modalities are mainly imaging. In our case; ultrasound and MRI were the examinations of choice over CT because of their non-irradiating nature. Confirmation is by finding cystic wall devoid of epithelial lining on pathologic specimen” [7-8].

Previous reports have noted that pancreatic pseudocysts larger than 6 cm in diameter and persisting for more than 6 weeks are unlikely to resolve spontaneously [9]. But in our case, a spontaneous resolution was the evolution, despite the giant volume and duration of persistence.

“The management of pancreatic pseudocysts during pregnancy is poorly clarified. However, surgical treatment can be of two approaches closed (percutaneous drainage or laparoscopic approach); and open with internal or external drainage. Most surgeons adhere to the ‘Rule of 6’ for the management of pancreatic pseudocysts (that is cysts >6 cm or duration >6 weeks). This was based on the expectations that 6 weeks is sufficient time for the pseudocyst to resolve spontaneously and the pseudocyst wall to mature to be tough enough to hold sutures” [10].



“An Endoscopic retrograde cholangiopancreatography is advisable as pancreatic duct disruption is associated with a decreased rate of pseudocyst resolution following drainage. The reference treatment modality consists of transmural drainage guided by endoscopic ultrasound” [11].

#### 4. CONCLUSION

Giant pseudocysts of pancreas may not be as rare as they were thought to be, but in pregnancy they can create a great problem of therapeutic management. The conservative attitude can be a choice, but when the impact is obvious, the appeal to therapeutic modalities must be standardized by creating decisional algorithms for the different clinical presentations.

#### CONSENT

As per international standard or university standard, patient(s) written consent has been collected and preserved by the author(s).

#### ETHICAL APPROVAL

As per international standard or university standard written ethical approval has been collected and preserved by the author(s).

#### COMPETING INTERESTS

Authors have declared that no competing interests exist.

#### REFERENCES

1. Gumaste VV, Pitchumoni CS. Pancreatic pseudocysts; In Brandt LJ (ed). Clinical Practice of Gastroenterology. Philadelphia, Current Medicine Inc. 1999;1219–1224.
2. De Socio GV, Vispi M, Fischer MJ, et al. A giant pancreatic pseudocyst in a patient with HIV infection, J. Int. Assoc. Physicians AIDS Care (Chic). 2012;11:227–229.
3. Elkhatib I, Savides T, Fehmi SMA. Pancreatic fluid collections: physiology, natural history, and indications for drainage, Tech. Gastrointest. Endosc. 2012;14:186–194.
4. Oria A, Ocampo C, Zandalazini H, et al. Internal drainage of giant acute pseudocysts—the role of video-assisted pancreatic necrosectomy. Arch. Surg. 2000;135:136–410.
5. Wang GC, Misra S. A giant pancreatic pseudocyst treated by cystogastrostomy. BMJ Case Rep. 2015;24:130–142.
6. Habashi S, Draganov PV. Pancreatic pseudocyst. World J Gastroenterol. 2009; 15(1):38-47.
7. Lankisch PG, Weber-Dany B, Maisonneuve P, Lowenfels AB. Pancreatic pseudocysts: prognostic factors for their development and their spontaneous resolution in the setting of acute pancreatitis. Pancreatology. 2012;12(2): 85-90.
8. Tyberg A, Karia K, Gabr M, Desai A, Doshi R, Gaidhane M, et al. Management of pancreatic fluid collections: A comprehensive review of literature, World J. Gastroenterol. 2016;22(7):2256–2270.
9. Igwe PO, Ray-Offor E, Karibi EN, Okeke UF, Ugwa OC, Jebbin NJ. Giant pseudocyst of the pancreas: A report of three cases. International Journal of Surgery Case Reports. 2020;77:284-297.
10. Cannon JW, Callery MP, Vollmer Jr. CM. Diagnosis and management of pancreatic pseudocysts. J. Am. Coll. Surg. 2009;3: 385–390.
11. Lu X, Uchida E, Yokomuro S, Nakamura Y, Aimoto T, Tajiri T. Features and choice of treatment of acute and chronic pancreatic pseudocysts—with special reference to invasive intervention. Pancreatology. 2008; 8(1):30-35.

© 2022 El Bakouri et al.; This is an Open Access article distributed under the terms of the Creative Commons Attribution License (<http://creativecommons.org/licenses/by/4.0>), which permits unrestricted use, distribution, and reproduction in any medium, provided the original work is properly cited.

*Peer-review history:*  
The peer review history for this paper can be accessed here:  
<https://www.sdiarticle5.com/review-history/92549>