



Miliary Tuberculosis with Cutaneous Affectations and SARS-CoV-2 Coinfection in Infant: Case Report in Mexico

**Ivonne Juarez Reyes ^a, Jose Alfredo Vidal Vidal ^{b*},
Virginia Lora Tellez ^c, Ma. Fabiola Del Carmen Lara Hernandez ^d,
Magdalena Molina Macip ^e, Alejandra Silva Hernandez ^{ft},
Patricia Daniela Gogeochea Guillen ^{fr},
Brenda Mariel Valerdi Zepeda ^{fr}, Angie Giovanna Velasco Peraza ^{fr},
and Froylan Eduardo Hernandez Lara González ^{fr}**

^a Infectology Area, Hospital Para el Niño Poblano, Puebla, Mexico.

^b Critical Medicine Department, Hospital Para el Niño Poblano, Puebla, Mexico.

^c Microbiology Laboratory, Hospital Para el Niño Poblano, Puebla, Mexico.

^d Anatomic Pathology, Hospital Para el Niño Poblano, Puebla, Mexico.

^e Pediatric Allergy and Immunology, Hospital Para el Niño Poblano, Puebla, Mexico.

^f Hospital Para el Niño Poblano, Puebla, Mexico.

Authors' contributions

This work was carried out in collaboration among all authors. Authors IJR, JAVV, VLT, MFDCLH and MMM collected the case data and was involved in writing the manuscript. Authors IJR, JAVV, ASH and FEHLG were involved in writing and editing the manuscript. Authors ASH, PDGG, BMVZ and AGVP wrote the discussion and participated in literature searches. All authors read and approved the final manuscript.

Article Information

DOI: 10.9734/JAMMR/2022/v34i131247

Open Peer Review History:

This journal follows the Advanced Open Peer Review policy. Identity of the Reviewers, Editor(s) and additional Reviewers, peer review comments, different versions of the manuscript, comments of the editors, etc are available here: <https://www.sdiarticle5.com/review-history/78560>

Case Report

Received 21 November 2021

Accepted 24 December 2021

Published 07 January 2022

^r Head of Resident;

^y Pediatrics Resident;

^z Teaching and Research Coordinator;

*Corresponding author: E-mail: vidal_vidal18@hotmail.com;

ABSTRACT

Aims: To describe an infant presenting with miliary tuberculosis with cutaneous affectations and SARS-CoV-2 coinfection.

Presentation of Case: 10 month old boy, with incomplete vaccination. Low Socio-economic status. The parents indicated, that lesion began with a single small, erythematous, non-pruritic, papule-type skin lesion on the left side of the infralabial region, with no other constitutional. During the following three months, the lesions became generalized. On June 23, 2020, he was admitted to the "Hospital para el Niño Poblano" in emergency area with mild malnutrition, lethargic state, fluid and electrolyte imbalance, metabolic acidosis, oral candidiasis, and septic shock, requiring endotracheal intubation. Besides, innumerable acid fast bacilli in skin biopsy and bronchial aspirate with diagnosis cutaneous TB was, identified. Immunodeficiency based on immunoglobulin profile and T and B cell markers. RT-PCR was performed for SARS-CoV-2 in bronchial aspirate, with a positive result. On June 25, 2020 died of cardiorespiratory arrest, secondary to septic shock and cutaneous tuberculosis.

Discussion: Miliary TB in infants is difficult to diagnose in addition the cutaneous manifestation has added onto the long list of differentials, and downplay others, generating inappropriate and delayed treatment. Additionally, SARS-CoV-2 can intensify the clinical manifestations of miliary tuberculosis and directly influencing the mortality of this type of patients.

Conclusion: The case described is rare, which reveals the importance to perform a differentiated diagnosis, considering Socio-economic and epidemiological context mainly in the first level of care. It is recommended to continue with research in order to generate information on the possible clinical pictures.

Keywords: COVID-19; immunodeficiency; miliary tuberculosis; mycobacterium tuberculosis.

1. INTRODUCTION

Tuberculosis (TB) is the infectious disease with the highest global mortality, causing 1.5 million deaths during 2020 [1]. Mycobacterium tuberculosis complex has the ability to grow within host cells and to be transmitted directly from one host to another [2]. The usual classification of TB is infiltrative, focal, tuberculoma, miliary, and fibrocavitary [3]. Miliary tuberculosis is a lethal form of TB with massive lymphohaematogenous spread from a Mycobacterium tuberculosis laden focus [4] with cutaneous manifestation being rare [5]. Low Socio-economic status has been associated with a greater risk of exposure to TB due to unfavorable conditions food, access to health services, education and housing. Once the infection has occurred, there is greater susceptibility in people with comorbidities such as, human infection virus (HIV), extremes of age, diabetes, silicosis or rheumatoid arthritis and other chronic or immunosuppressive diseases [6]. SARS-CoV-2 appears to induce cytokine storm, and therefore, generate immunomodulatory effects. Different studies have shown, TB status could influence the development, but not the mortality of severe acute respiratory syndrome in coinfection by SARS-CoV-2, finding a risk of 2.1 times greater

for critical illness owing to COVID-19; contributing to worsen the prognosis and increase the mortality of TB patients [7]. The objective of this paper is to describe a case of miliary tuberculosis with cutaneous affectations and SARS-CoV-2 coinfection in an infant in Mexico.

2. PRESENTATION OF CASE

10 month old boy patient, native and resident from Central Region of the state of Puebla, Mexico. Weight at birth of 2.5 kg and 50 cm in length. Breastfed for six months, incomplete national vaccination schedule for age (administered BCG), without significant family and personal antecedents and Low Socio-economic status with overcrowding. The parents indicated that during the last week of February 2020, he began with a single, small, erythematous, non-pruritic, papule-type skin lesion on the left side of the infralabial region, no other symptoms. For the next three months, the lesions became generalized (face, neck, anterior and posterior thorax, abdomen and upper extremities), increasing in size, being confluent, pustular, non-suppurative, with an erythematous base, as well as, color changes to violaceous from the center to periphery and painful. He received, exclusively topical treatment with

betamethasone for four weeks with no improvement and progression of lesions.

On June 11, 2020, he developed a persistent and continuous fever of 38.5°C with increased temperature at nights, temporarily improved. Accompanied by a non-productive cough and in accesses, presenting mainly in the mornings, being taken to private medical services. Started treatment with ambroxol and ceftriaxone (dose unknown). On June 21, 2020, he presented a productive cough in short accesses, with hyaline expectoration in moderate quantity. Adding respiratory difficulty with nasal flaring, expiratory whimper and intercostal drawing. The skin lesions disseminated with some punched out ulcers, some as suppurative papules / blebs. He admitted to private medical services without knowing the treatment granted. Lack of improvement made the parents to voluntarily discharge from that center and brought to our facility.

On June 23, 2020, he was admitted to the "Hospital para el Niño Poblano" in the Emergency Area with mild malnutrition, lethargic state, oral candidiasis, and septic shock, requiring endotracheal intubation (Fig. 1). He was treated with antibiotics intravenously based on meropenem (40 mg / kg / 24 h) and vancomycin (15 mg / 24 h), in addition to fluconazole (6 mg / kg / 24 h) and erythrocyte transfusion. He was transferred to the Pediatric Intensive Care Area. He was assessed by pediatric infectious disease specialist, with a probable diagnosis of ecthyma gangrenosum vs staphylococcal toxic shock, adjusting the doses of antibiotics (meropenem 120 mg / kg / 24 h; vancomycin 60 mg / kg / 24 h) already started, adding clindamycin (40 mg / kg / 24 h) to increase the inhibitory effect (synergism), and coverage with liposomal amphotericin B (1 mg / kg / 24 h), due to suspected superinfection by fungal agents according to the time of evolution.

On June 25, 2020, the pediatric dermatologist performed a skin biopsy fullstop histopathological results, tiny fragments of corneal material, without giant cells or granuloma formation (Fig. 2.1). In the Ziehl-Neelsen stain, innumerable acid-fast bacilli (AFB) seen and a diagnosis of cutaneous TB (Fig. 2.2). Periodic Acid-Schiff and Gram stains were negative.

On the same date, a real-time Reverse Transcriptase Polymerase Chain Reaction assay detected *Mycobacterium tuberculosis* Complex,

(RT-PCR-RT, Xpert MTB / RIF system) in skin biopsy samples and bronchial aspirate, without detection of mutation in the *rpoB* gene associated by resistance to rifampicin. The Ziehl-Neelsen staining technique showed positive AFB smear microscopy (+++), skin culture (+++) (Fig. 3), and bronchial aspirate (+). This corroborated that the disease was extensive.

In addition, Löwenstein-Jensen culture medium, both material from skin aspirate and bronchial aspirate showed growth in 34 days. In the first, abundant, rough, pale yellow colonies were identified. In the second, smooth yellow confluent colonies were observed, contrasted by the color of the culture medium (Fig. 4). Identification and confirmation of *Mycobacterium tuberculosis* was carried out through molecular methods.

Table 1 shows the evolution of the blood count parameters and acute phase reactants and coagulation factors, during the length of stay. Progressive secondary cytopenias to infectious process and elevated levels of acute phase reactants and procalcitonin were observed. Diagnosis of immunodeficiency. Severe combined immunodeficiency was arrived on the basis of hypogammaglobulinemia (IgA < 2 mg / dL; IgG = 127 mg / dL; IgM < 10 mg/dL; and IgE < 4.56 UI / mL), and total depletion of T lymphocytes (CD3⁺ = 0.12 cell / μ L; CD3⁺ / CD4⁺ = 0.0 cell / μ L; CD3⁺ / CD8⁺ = 0.22 cell / μ L) with normal production of B (CD20⁺ = 170.45 cell / μ L) and NK (CD3⁻ / CD16⁺ / CD56⁺ = 0.79 cell / μ L). HIV status was negative.

Additionally, the Culture of mycobacteria was performed on a solid Löwestein-Jensen medium, with a positive result (+++) of abundant and uncountable AFB colonies by skin biopsy sample; and a positive result (+) of confluent colonies of AFB in number <100, at bronchial aspirate sample. Anti tuberculous treatment was started through isoniazid, rifampin, pyrazinamide, and ethambutol. On June 25, 2020 considering these results and due to COVID-19 pandemic, RT-PCR was performed to SARS-CoV-2 in bronchial aspirate, with a positive result. The patient presented an inappropriate clinical evolution, by septic shock refractory to inotropics, requiring an increase in the mechanical ventilation parameters. Chest radiographs showed a consolidation in the entire left lung (Fig. 5). This day, he died of cardiorespiratory arrest, secondary to septic shock. The epidemiological follow-up was carried out by the health authorities, so the hospital does not have the information in this regard.

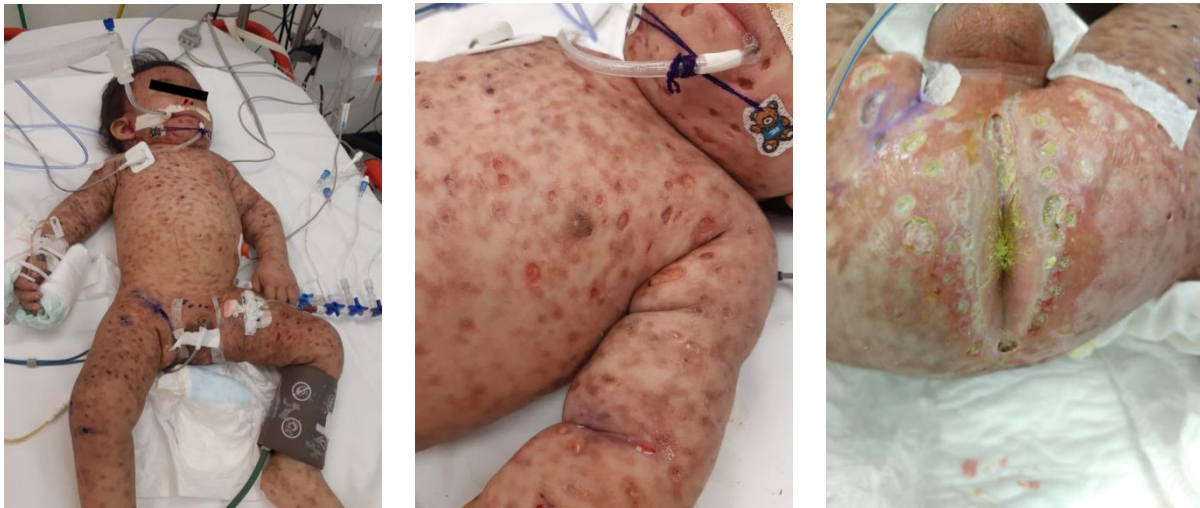

Fig. 1. Clinical appearance of ulcerative, punched-out, suppurative and disseminated dermal lesions upon admission

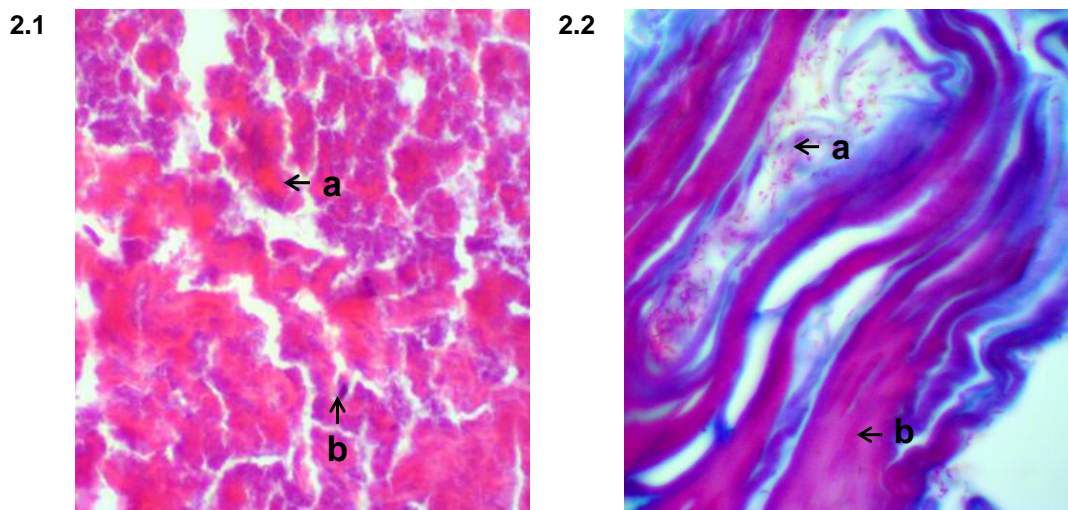


Fig. 2. Skin biopsy. Simple light microscopy. 2.1 Objective magnification 40x; Hematoxylin and eosin staining technique. Tissue showing total loss of skin histology, replaced by cellular debris with granular cytoplasm (a) and polymorphonuclear leukocytes (acute inflammation) (b). 2.2 Objective magnification 100x. Ziehl-Neelsen technique. Visualization of the bacilli of the Mycobacterium tuberculosis complex in red (a); contrasting with the cellular debris and laminated keratin of the stratum corneum of the skin (b)

3. DISCUSSION

The reported case shows how significant, is social protection (food, health, education and housing) to prevention, diagnosis and adequate management of TB in all its variants, and hence, its future incidence [8]. In this sense, exposure to TB is intensified in collective living environments, homes of people with active tuberculosis and crowded places not, poverty adds on to these above factors [9]. The host's immune system stops the progression of TB,

whereas immunodeficient conditions and malnutrition being important risk factors for developing its active form. Active TB is responsible nearly half of deaths in untreated people, so that early diagnosis and effective treatment is determinant [10].

TB is usually acquired through the lungs and intestines with, cutaneous TB being a manifestation of systemic involvement. The add common agents are generally Mycobacterium tuberculosis and rarely Mycobacterium bovis,

and the Calmette-Guérin bacillus [11]. Cutaneous TB represents a very small proportion of all TB cases, classified by the type of dissemination (exogenous and endogenous), route of infection (autoinoculation, direct inoculation, hematogenous, lymphatic, BCG vaccine), as well as, by the bacterial load (multibacillary, paucibacillary). The clinical

manifestations in exogenous infection can be Lupus vulgaris, Tuberculosis verrucosa cutis and Tuberculous chancre. In endogenous group common to rare presentation are Lupus vulgaris (most cases), Scrofuloderma, Miliary tuberculosis, orificial tuberculosis, tuberculosis abscess and papulonecrotic tuberculosis [12,13].

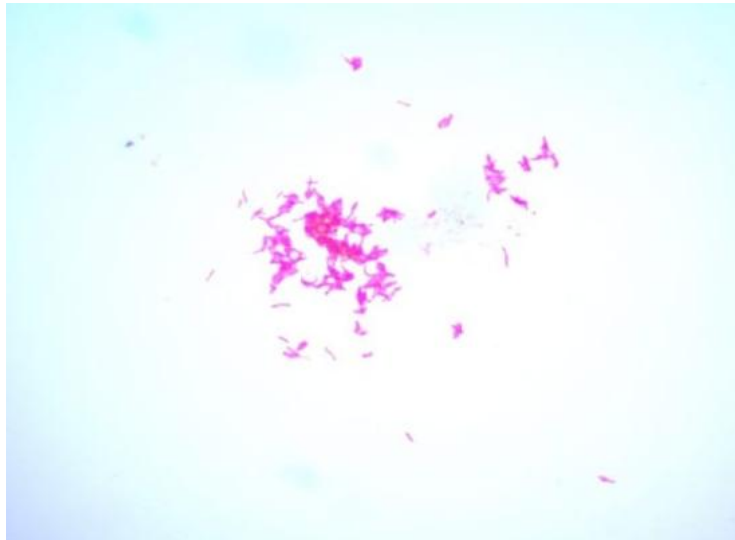


Fig. 3. Skin biopsy culture. Simple light microscopy in an immersion objective, magnification 100x; Ziehl-Neelsen staining technique; Large conglomerates of AFB are observed in a “bead effect” exhibiting a spotty appearance

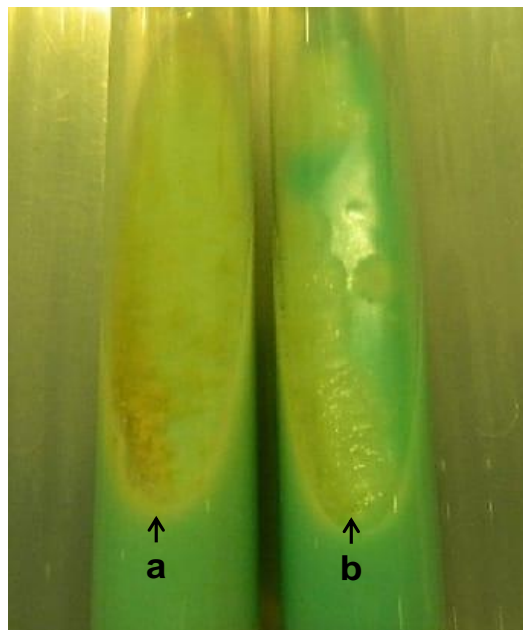


Fig. 4. Skin cultures and bronchial aspirate; Löwestein – Jensen culture medium. Growth rate in 34 days; Incubation conditions: 37 ° C temperature in ambient atmosphere. Skin biopsy culture: abundant, confluent, rough, faint yellow colonies (a). Culture of bronchial aspirate: confluent, smooth, pale yellow colonies (b)

Table 1. Evolution of blood count parameters and acute phase reactants and coagulation factors

Parameter	Date of sampling			
	23-06-2020	24-06-2020	25-06-2020	26-06-2020
Hemoglobin (g/dL)	5.40	6.60	-	7.80
Hematocrit (%)	18.60	21.50	-	25.30
Leukocytes (10 ³ /μL)	7.21	0.45	-	1.95
Neutrophils (10 ³ /μL)	6.49	0.36	-	1.35
Band (10 ³ /μL)	3.76	0.12	-	0.04
Lymphocytes (10 ³ /μL)	0.72	0.08	-	0.29
Eosinophils (10 ³ /μL)	-	0.0045	-	0.058
Platelets (mm ³)	84,000	4,000	-	9,000
ESR* (mm/h)	-	2	-	-
CRP** (mg/L)	-	>96	-	-
Procalcitonin (ng/mL)	-	-	242.7	-
Ferritin (ng/mL)	-	1207.27	-	-
D-dimer (ng/mL)	2578	3723	-	-
Fibrinogen(mg/dL)	553	300	-	-

*ESR: erythrocyte sedimentation rate; **CRP: C-reactive protein

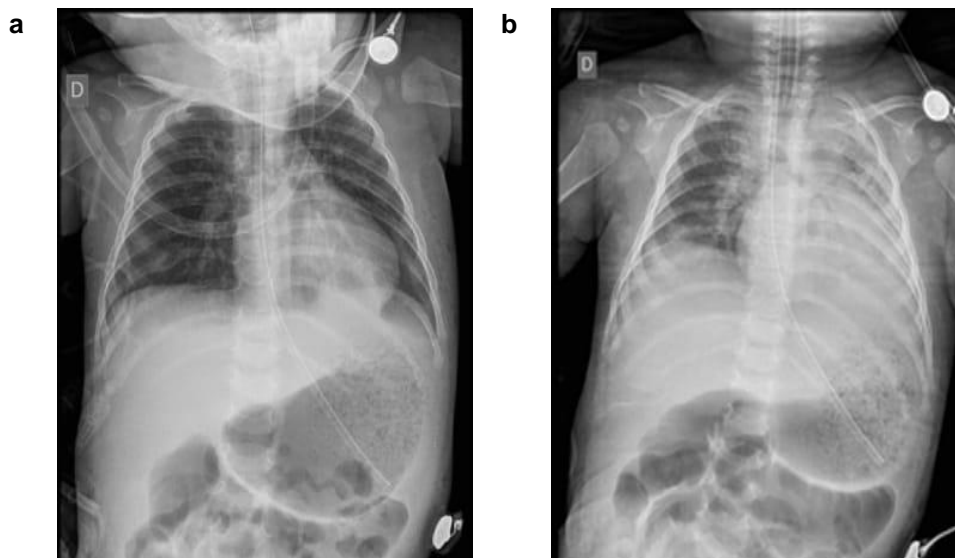


Fig. 5. Plain anteroposterior chest radiographs. X-ray on admission, observing right parahilar infiltrates with air bronchogram (a). Chest X-ray 48 hours after admission, with consolidation in the entire left hemithorax, loss of the contour of the cardiac silhouette and the ipsilateral costo-diaphragmatic angle (b)

Any disease coinfection with TB can lead on to clinical dilemmas, and diagnostic and therapeutic challenges, as the case report presented [14]. Co-infections of any origin during COVID-19 pandemic need an effective strategy in the diagnostic and therapeutic approach, and even more in miliary TB with skin affectations, due to their clinical manifestations they may represent an obstacle in the prioritization of the medical care [15]. The co-infection of miliary TB with skin involvement and SARS-CoV-2, mainly in first-time patients, probably results in the lack of

identification of either disease, due to nonspecific clinical characteristics of both, coupled with scarcity of clinical resources [14,15].

The most prevalent primary immunodeficiency is common variable immunodeficiency, which is a heterogeneous disorder characterized by hypogammaglobulinemia and a wide variety of infectious (fungal and bacterial) and non-infectious complications [16,17]. Various immunological and genetic defects are involved in the pathogenesis. In most cases of genetic

origin, the disease remains unidentified [16,17] as was possibly this case report, in which socio-economic factors and first contact medical care were determining factors in the result.

Immunodeficiency or the use of immunomodulators can lead to the intensification and reactivation of TB, which in turn can be a predisposing factor to manifestations of SARS-CoV -2 [18,19]. Miliary tuberculosis with cutaneous affectations is difficult to diagnose because, its clinical manifestations can be confused with various diseases, and downplay others, generating inappropriate and delayed treatment. SARS-CoV-2 can intensify the clinical manifestations of miliary tuberculosis and if unnoticed can, directly influencing the mortality of this type of patients [20]. In the current epidemiological context, the suspicion of co-infections with TB in addition to COVID-19 in patients with respiratory tract infections, nonspecific clinical characteristics and an unexplained or prolonged clinical course must be contemplated [14].

4. CONCLUSION

The case study described is rare, which reveals the importance of differential diagnosis based on the Socio-economic status and epidemiological context, mainly in the first level of care, from human, material and technological resources which are usually insufficient, reflecting a lower quality and opportunity in medical services, and resulting in higher morbidity and mortality in this type of patients. More research is needed on the knowledge gap as to why SARS-CoV-2 increases mortality and morbidity in those with pre existing disease including TB.

CONSENT

All authors declare that written informed consent was obtained, from the patient's parents for publication, of this case report and accompanying images.

ETHICAL APPROVAL

The research work was examined and approved by the hospital research and ethics committee.

COMPETING INTERESTS

Authors have declared that no competing interests exist.

REFERENCES

1. World Health Organization (WHO). Tuberculosis. [Consulted December 8, 2021]. Available: <https://www.who.int/news-room/fact-sheets/detail/tuberculosis>.
2. Gagneux S. Ecology and evolution of Mycobacterium tuberculosis. *Nature Reviews Microbiology*. 2018; 16(4):202-213. DOI: 10.1038/nrmicro.2018.8
3. Cid YD, Liauchuk V, Kovalev V, Müller H. Overview of Image CLEF tuberculosis 2018-Detecting Multi-Drug Resistance, Classifying Tuberculosis Types and Assessing Severity Scores. In CLEF;2018.
4. Sharma SK, Mohan A. Miliary tuberculosis. *Tuberculosis and Nontuberculous Mycobacterial Infections*. 2017;491-513. DOI: 10.1128/9781555819866.ch29
5. Chen Q, Chen W, Hao F. Cutaneous tuberculosis: a great imitator. *Clinics in dermatology*. 2019; 37(3):192-199. DOI: 10.1016/j.clndermatol.2019.01.008
6. Duarte R, Lönnroth K, Carvalho C, Lima F, Carvalho ACC, Muñoz-Torrico M, Centis, R. Tuberculosis, social determinants and co-morbidities (including HIV). *Pulmonology*. 2018; 24(2):115-119. DOI: 10.1016/j.rppnen.2017.11.003
7. Crisan Dabija R, Grigorescu C, Pavel CA, Artene B, Popa IV, Cernomaz A, Burlacu A. Tuberculosis and COVID-19: lessons from the past viral outbreaks and possible future outcomes. *Canadian Respiratory Journal*; 2020. DOI: 10.1155/2020/1401053
8. Carter DJ, Glaziou P, Lönnroth K, Siroka A, Floyd K, Weil D, Raviglione M C, Houben R, Boccia D. The impact of social protection and poverty elimination on global tuberculosis incidence: a statistical modelling analysis of Sustainable Development Goal 1. *The Lancet Global Health*. 2018; 6(5):e514-e522. DOI: 10.1016/S2214-109X(18)30195-5
9. Dowdy DW, Raviglione MC. Basic and Descriptive Epidemiology of Tuberculosis. In *Essential Tuberculosis*. Springer, Cham. 2021;29(36). DOI: 10.1007/978-3-030-66703-0_4
10. Koch A, Cox H, Mizrahi V. Drug-resistant tuberculosis: challenges and opportunities for diagnosis and treatment. *Current Opinion in pharmacology*. 2018;42:7-15. DOI: 10.1016/j.coph.2018.05.013

11. Franco PC, Marcos LA, Henao MAF, Rodríguez MAJ, Villamil GWE, Gotuzzo E, Bonifaz A. Cutaneous mycobacterial infections. *Clinical microbiology reviews*. 2018;32(1):e00069-18. DOI: 10.1128/CMR.00069-18.
12. Murry WT, Sharma S, Arora VK, Bhattacharya SN, Singal A. Cytomorphological spectrum and immunochemistry of cutaneous tuberculosis. *Diagnostic cytopathology*. 2019;47(5):458-468. DOI: 10.1002/dc.24138.
13. Kumar B, Kumar S. Pediatric cutaneous tuberculosis: Indian scenario. *Indian Journal of Paediatric Dermatology*. 2018; 19(3):202. DOI: 10.4103/jiaomr.jiaomr_33_17
14. Kumar R, Bhattacharya B, Meena V, Soneja M, Wig N. COVID-19 and TB co-infection-'Finishing touch'in perfect recipe to'severity'or 'death'. *Journal of Infection*. 2020;81(3):e39-e40. DOI: 10.1016/j.jinf.2020.06.062
15. Molgó M, Cárdenas C, Ramonda P, Salinas MP. Scrofuloderma, cutaneous and pulmonary tuberculosis associated with COVID-19. Report of one case. *Revista Medica de Chile*. 2021; 149(4), 630-634. DOI: 10.4067/s0034-98872021000400630
16. Yazdani R, Habibi S, Sharifi L, Azizi G, Abolhassani H, Olbrich P, Aghamohammadi A. Common variable immunodeficiency: epidemiology, pathogenesis, clinical manifestations, diagnosis, classification, and management. *Journal of investigational allergology & clinical immunology*, 2020; 30(1):14-34. DOI: 10.18176/jiaci.0388
17. Gereige JD, Maglione PJ. (2019). Current understanding and recent developments in common variable immunodeficiency associated autoimmunity. *Frontiers in immunology*. 2019; 10:2753. DOI: 10.3389/fimmu.2019.02753
18. Freij BJ, Gebara BM, Tariq R, Wang AM, Gibson J, El-Wiher N, Krasan G, Patek PM, Levasseur AH, Amin M, Fullmer JM. Fatal central nervous system co-infection with SARS-CoV-2 and tuberculosis in a healthy child. *BMC pediatrics*. 2020; 20(1):1-7. DOI: 10.1186/s12887-020-02308
19. Zagoya MP, Limon FJA, Vidal VJA. Survival in Patients with Acute Lymphoblastic Leukemia and COVID-19 in Mexico. *International Blood Research & Reviews*. 2021;32-39. DOI: 10.9734/ibr/2021/v12i330153
20. Stochino C, Villa S, Zucchi P, Parravicini P, Gori A, Raviglione MC. Clinical characteristics of COVID-19 and active tuberculosis co-infection in an Italian reference hospital. *European Respiratory Journal*. 2020; 56(1). DOI: 10.1183/13993003.01708-2020

© 2022 Reyes et al.; This is an Open Access article distributed under the terms of the Creative Commons Attribution License (<http://creativecommons.org/licenses/by/4.0>), which permits unrestricted use, distribution, and reproduction in any medium, provided the original work is properly cited.

Peer-review history:

The peer review history for this paper can be accessed here:
<https://www.sdiarticle5.com/review-history/78560>