



Canalicular Adenoma in the Parapharyngeal Space: A Rare Case Report

Mohamed Amine Karmouch ^a, Hamza BENGHALEB ^{a*},
Walid Bijou ^a, Youssef Oukessou ^a, Sami Rouadi ^a,
Redallah Abada ^a, Mohamed Roubal ^a
and Mohamed Mahtar ^a

^a Otorhinolaryngology and Head and Neck Surgery Department, Faculty of Medicine and Pharmacy, IBN ROCHD University Hospital, Hassan II University, Casablanca, Morocco.

Authors' contributions

This work was carried out in collaboration among all authors. All authors read and approved the final manuscript.

Article Information

Open Peer Review History:

This journal follows the Advanced Open Peer Review policy. Identity of the Reviewers, Editor(s) and additional Reviewers, peer review comments, different versions of the manuscript, comments of the editors, etc are available here: <https://www.sdiarticle5.com/review-history/113254>

Case Study

Received: 07/12/2023

Accepted: 12/02/2024

Published: 27/04/2024

ABSTRACT

Canalicular adenoma (CA) is an exceedingly uncommon and unique benign neoplasm of the salivary glands. This particular neoplasm characteristically affects the minor salivary glands located in the upper lip, buccal mucosa, and palate. It is most frequently observed in individuals of middle age or those who have reached an older age, displaying a predilection for the female gender. Clinically, it typically manifests as a painless, gradually enlarging, non-ulcerated nodule or swelling. The standard approach to managing this neoplasm involves the utilization of surgical techniques such as excision or enucleation. Remarkably, within the confines of this case report, we present the details of a rather exceptional occurrence of CA, which was encountered within the left parapharyngeal space of a young woman aged 25, thereby potentially constituting the initial documented instance of such a lesion occurring within the parapharyngeal space.

*Corresponding author: E-mail: benghaleb.hamza@gmail.com;

Keywords: Canalicular adenoma; mucosa; salivary gland neoplasm; parapharyngeal space.

1. INTRODUCTION

“The utilization of the term 'Canalicular Adenoma' (CA) was initially employed by Bauer WH and Bauer JD in the year 1953 [1]. “Previously, Canalicular adenoma (CA) was grouped under the category of monomorphic adenoma alongside other uncommon benign salivary gland neoplasms such as basal cell adenoma, oncocytoma, and Warthin’s neoplasm. The term monomorphic adenoma was utilized to differentiate these neoplasms from pleomorphic adenoma. Initially, it was hypothesized that CA originated from terminal duct cells. The ongoing debate surrounding the cell of origin has resulted in numerous modifications in the nomenclature and classification of CA throughout the years. Nonetheless, in the most recent two editions of the World Health Organization (WHO) classification, CA has been distinguished from other monomorphic adenomas and is considered to be a distinct salivary gland neoplasm” [1]. “It accounts for approximately 1-3% of all salivary gland neoplasms and tends to occur predominantly in the minor salivary glands. From a clinical perspective, CA typically manifests as a well-defined, painless, slow-growing, mobile nodule, which may exhibit either firm or fluctuant characteristics upon palpation”. [2] According to the WHO histological classification of head and neck neoplasms, "the CA is defined as a benign salivary gland neoplasm comprising monomorphous epithelial ductal cells arranged in anastomosing cords within a cell-poor vascular stroma" [3]. “Based on the findings derived from immunohistochemistry and ultrastructural analysis, it has been determined that the cells of

origin for CA are the intercalated duct luminal cells” [4,5]. The purpose of this paper is to present a unique case of CA in a female patient, which occurred in the left parapharyngeal space.

2. CASE REPORT

We report the case of a 25-year-old woman, with no pre-existing medical conditions, who sought consultation in our department for a two-year history of progressive swelling in the left submandibular region. The patient was initially asymptomatic and without signs of pain or compression. She experienced a shift in the last 6 months marked by pharyngeal discomfort, particularly during the ingestion of solid food. Initial examination revealed a mass in the upper laterocervical region of the left side. It was firm, indolor, mobile to the superficial layer and fix to deep planes with no skin changes overlaying the lesion. The oropharyngeal examination was marked by a medialisation of the left tonsil region and a bulge in the lateral wall of the nasopharynx. Neurological examination was normal. CT scan imaging revealed a well-defined oval tissue lesion, located within the left parapharyngeal space, measuring 5 x 3.1 centimeters. In spontaneous contrast, it demonstrated isodensity and exhibited heterogeneous contrast enhancement following injection. The mass exerts pressure on both the nasopharynx and oropharynx, resulting in a slight medial deviation. It was in proximity with deep parotid lobe externally, the medial pterygoid muscles anteriorly and remained at a distance from the sub mandibular gland inferiorly. (Fig. 1).

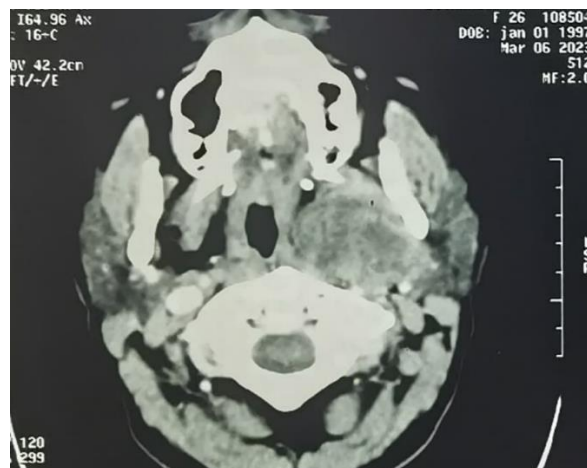

Fig. 1. CT scan with contrast showing an isodense mass

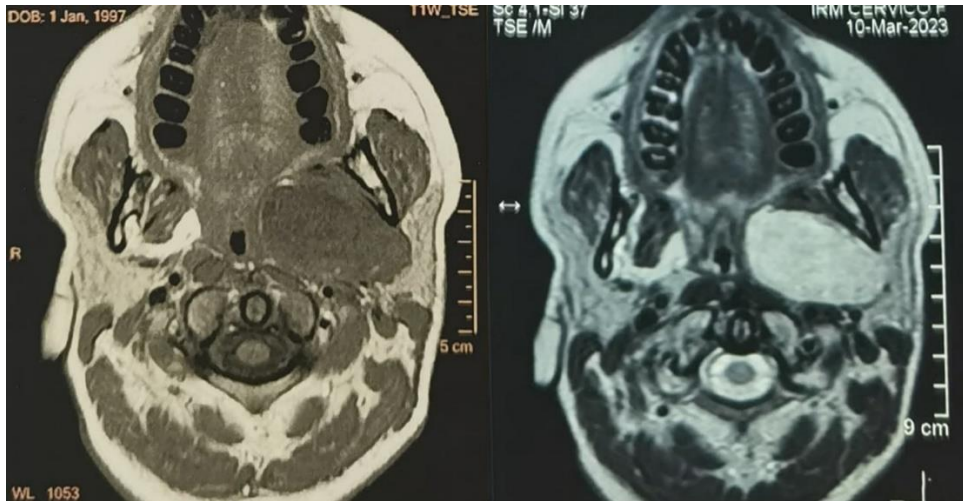


Fig. 2. Axial MRI cuts showing a parapharyngeal mass, isointense T1 and hyper intense T2

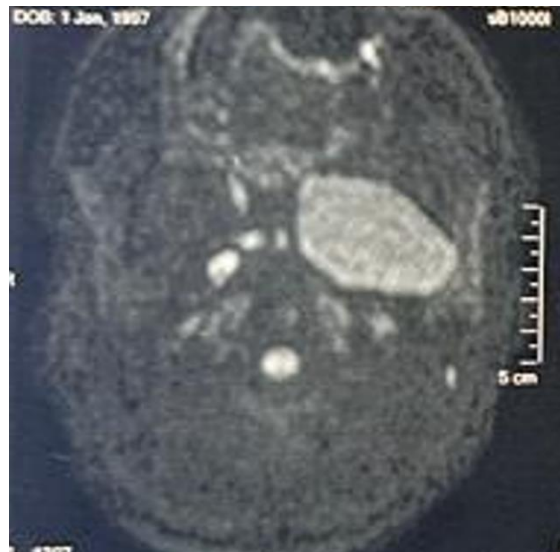


Fig. 3. Diffusion weighted sequence showing a hyper intense lesion

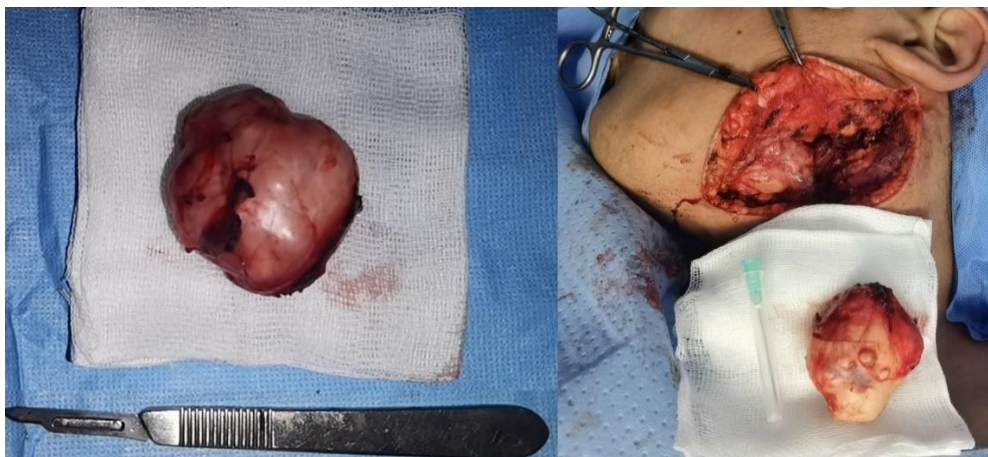

Fig. 4. Preoperative picture of the nodular mass after complete excision

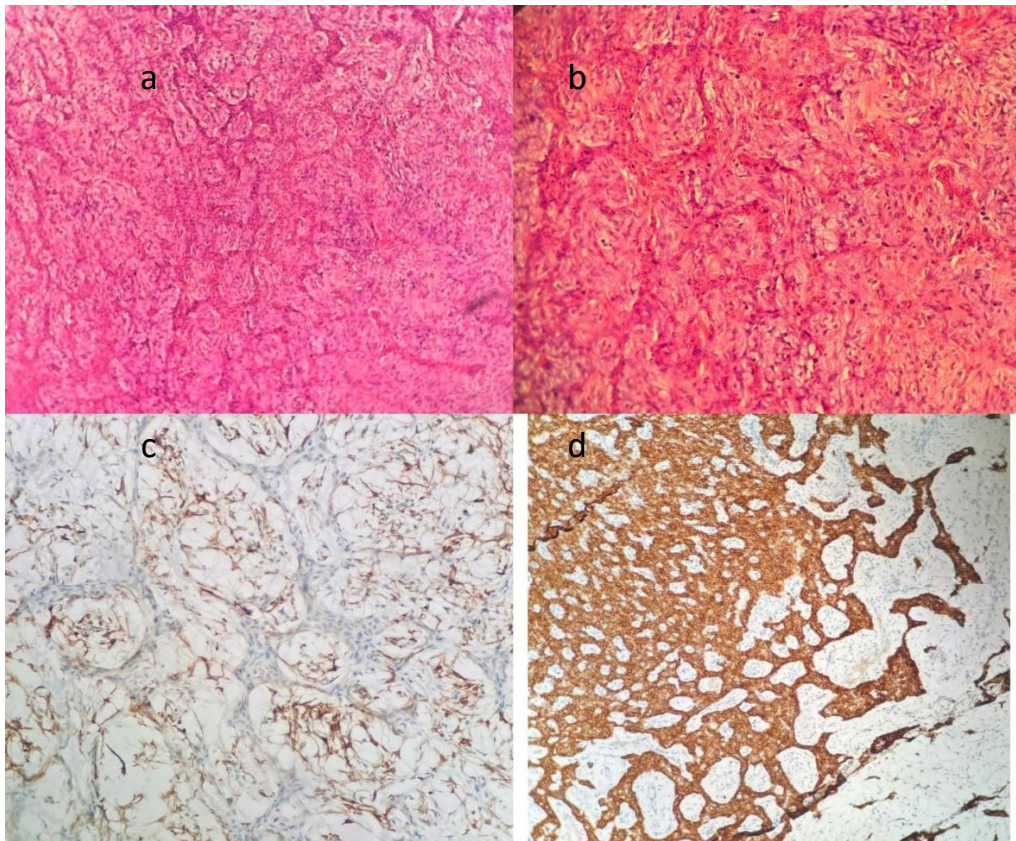


Fig. 5. a and b: H&E stained section of the biopsy a(x10) and b (x40) : canalicular pattern with cords and ribbons showing connections between opposing columnar cells within spaces formed by cuboidal to columnar basaloid cells
c: Immunostained section of the biopsy c (x10) : stromal cells are positive for GFAP
d: (x20) :CKAE1/AE3 is positive in tumoral cells

The MRI showed that the mass was located medially to the carotid arteries, in hypersignal T2 and in Diffusion-weighted sequence. It presents intimate contact with adjacent muscles, the parotid and the cortex of the left mandible with no additional cervical abnormalities. A paraganglioma was initially evoked. (Figs. 2,3).

Following a Sebilleau incision, the mass was successfully exposed by a senior surgeon through the sectioning of the posterior belly of the digastric muscle. Careful dissection ensued, leading to the total excision of the mass (Fig. 4). Subsequent histological examination identified a nodular fibromyxoid lesion, with an immunohistochemistry study revealing diffuse expression of Pankeratin AE1/AE3 and PS100. Negative results were obtained for CD34, AML, Chromogranin, synaptophysin, CD56, P63, and CD10. The Ki-67-labeling index was less than 2%, favoring a diagnosis of canalicular adenoma (Fig. 5). The postoperative course was uneventful, with the patient discharged the

following day. A 6-month follow-up revealed no signs of recurrence, and the wound exhibited good healing.

3. DISCUSSION

Canalicular adenoma is a rare salivary neoplasm that accounts for 1-3% of all salivary gland tumors [1-5,6-9]. "CA accounts for about 2% of more than 12 000 salivary gland neoplasms registered in AFIP since 1970. In a clinicopathological analysis of 493 salivary gland tumors", Fonseca et al (2012) reported 11 Cas [10]. In a large review of 3988 tumors, Pires et al (2007) reported "15 CA, representing 3.2% of all salivary gland neoplasms" [8].

The specific cause of the lesion is uncertain [11]. "CA is distinguished by asymptomatic slow development and a significant preference for the upper lip, followed by the buccal mucosa and hard palate" [4,12-20]. "It is one of the monomorphic adenomas with a stable

architectural structure” [21]. It is frequently encapsulated and composed of columnar cells in a stroma of loose connective tissue [22; 23-30].

Historically, canalicular adenoma was thought to be part of the spectrum of morphologic changes seen in basal cell adenoma. However, because of its distinct clinical, morphologic, immunohistochemical (IHC), and ultrastructural properties, it is now regarded to be a different entity [29].

We reported the case of a canalicular adenoma, in the parapharyngeal space, which is a very rare localization. The most common histological type of benign salivary gland tumors, in the parapharyngeal space is pleomorphic adenoma [31,32-34].

Canalicular adenoma typically affects individuals between the fourth and ninth decades of life. The average age of occurrence is in the seventh decade. It is often female-dominated [12;35], with a male-to-female ratio of 1:1.8 [35;36].

The present case was diagnosed in a 25-year-old female, and occurred in the parapharyngeal space. The age of our patient doesn't fall within the age gap previously described for CA. However, a literature search did not reveal any previous case of CA reported to occur in the parapharyngeal space, thus making the present case possibly the first case of canalicular adenoma to be reported involving the parapharyngeal space.

Canalicular adenoma lesions are characterized by a well-defined, non-tender swelling or nodular mass that can have a solid or fluid-filled consistency [7;37]. The most common presentation is a solitary nodule; however, it can also present as multiple nodules separate from the main tumor [7,37,38]. These lesions typically exhibit a slow growth rate and are indolor, mobile, and compressible, affecting the mucosal and submucosal tissues. In our case, the swelling was observed in both the submucosal tissue and the upper cervical region due to the extent of the mass. The color of the overlying mucosa is usually normal, but it may have a blue hue resembling a mucocele [19]. Microscopic analysis reveals that the neoplasm consists of a single layer of cuboidal or columnar cells, which can arrange themselves in parallel, elongated tubes, columns, or cords [35]. Similarly, the histopathologic examination of our case demonstrated the presence of a tubular structure

composed of a single layer of columnar cells. The cell rows are closely positioned to one another and may appear as double cell rows [35].

The preferred method for treating CA is surgical excision, which has long been regarded as the ultimate approach of choice in the medical community. This procedure involves the removal of the affected tissue, ensuring that a modest margin of seemingly normal tissue is also excised, even if no biopsy is conducted beforehand. It has been established that this conservative approach with a modest margin is sufficient in achieving favorable outcomes [12]. In our specific case, the CA following the excision appeared as light tan to brown lesions, which were nicely confined within the excised area. This containment is a positive sign, indicating that the surgical excision was successful in removing the affected tissue without any spread or infiltration. Recurrence of CA is an uncommon occurrence, with only a few recorded cases in medical literature. It is noteworthy to mention that our patient has been under careful monitoring for the past six months, and no signs of recurrence have been observed during this period. This is an encouraging finding that reassures us about the effectiveness of the surgical excision. However, it is important to note that multifocal lesions, which involve the presence of multiple CA lesions, are known to have a higher likelihood of reoccurrence. Although rare, these cases necessitate close surveillance and follow-up examinations to ensure early detection of any potential recurrence. In general, CA is primarily characterized by its benign behavior, with no instances of malignant change documented in medical literature [18,39]. This benign nature of CA is a reassuring aspect that provides further support for the effectiveness of surgical excision as the treatment of choice.

4. CONCLUSION

Canalicular adenoma is a distinctive neoplasm of the minor salivary glands, originating from the luminal cells of the intercalated duct. The incidence of this tumor is higher in women compared to men, particularly in individuals in their seventh decade of life. Predominantly affecting the upper lip, but also involving the buccal mucosa and palate, these tumors typically manifest as small masses (with an average size of 1.2 cm) that gradually increase in size and are devoid of pain or ulceration. Approximately 9% of cases exhibit multifocality. Histologically, the

presence of tumor cell beading and intraluminal squamous balls/morules is a distinguishing feature, while the myxoid stroma, cystic appearance, and microliths represent characteristic histologic findings. The application of a relevant immunohistochemical panel consisting of S100 protein, p63, CK5/6, and GFAP can effectively exclude other tumors in the histologic differential diagnosis, yielding results that are both distinctive and discriminatory.

CONSENT

As per International Standards or University Standards, Patient written consent has been collected and preserved by the authors.

ETHICAL APPROVAL

As per International Standard or University Standards written ethical approval has been collected and preserved by the authors.

COMPETING INTERESTS

Authors have declared that no competing interests exist.

REFERENCES

1. Rauch S, Seifert G, Gorlin RJ: Diseases of the salivary glands: tumors. In: Gorlin RJ, Goldman HM (eds), Thoma's oral pathology, 6th ed. St. Louis: CV Mosby Company. 1970;997e1003.
2. Yadav N, Khorate M, Figueiredo N. Canalicular adenoma of the tongue: Report of a unique case. Pan African Medical Journal. 2021 Apr 7;38(1).
3. Suarez P, Hammond HL, Luna MA, Stimson PG: Palatal canalicular adenoma: report of 12 cases and review of the literature. Ann Diagn Pathol. 1998;2: 224e228.
4. El-Naggar AK, Chan JKC, Grandis JR, Takata T, Slootweg PJ eds: World Health Organization: Classification of Tumours. Pathology and Genetics of Head and Neck Tumours. ARC Press 194, Lyon; 2017.
5. Yih WY, Kratochvil FJ, Stewart JC: Intraoral minor salivary gland neoplasms: review of 213 cases. J Oral Maxillofac Surg. 2005;63:805e810.
6. Furuse C, Tucci R, Machado de Sousa SO, Rodarte Carvalho Y, Cavalcanti de Araújo V: Comparative immunoprofile of polymorphous low-grade adenocarcinoma and canalicular adenoma. Ann Diagn Pathol. 2003;7:278-80.
7. Nelson JF, Jacoway JR: Monomorphic adenoma (canalicular type). Report of 29 cases. Cancer. 1973;31:1511-3.
8. Pires FR, Pringle GA, de Almeida OP, Chen SY: Intra-oral minor salivary gland tumors: A clinicopathological study of 546 cases. Oral Oncol. 2007;43:463-470,
9. Batsakis JG: Oral monomorphic adenomas. Ann Otol Rhinol Laryngol. 1991;100:348e350.
10. Fonseca FP, Carvalho Mde V, de Almeida OP, Rangel AL, Takizawa MC, Bueno AG, Vargas PA: Clinicopathologic analysis of 493 cases of salivary gland tumors in a southern Brazilian population. Oral Surg Oral Med Oral Pathol Oral Radiol Oral Endod. 2012;114:230-9.
11. Puttaswamy KA, Subramanya JB, Shashidara R, Gopalakrishna AH. Canalicular adenoma of the parotid gland: a case report. Journal of Advanced Clinical and Research Insights. 2014;2:61–63.
12. Smullin SE, Fielding AF, Susarla SM, Pringle G, Eichstaedt R: Canalicular adenoma of the palate: case report and literature review. Oral Surg Oral Med Oral Pathol Oral Radiol Endod. 2004;98:32e36.
13. Werder P, Altermatt HJ, Zbären P, Bornstein MM: Canalicular adenoma of a minor salivary gland on the palate: A case presentation. Quintessence Int. 2009;40: 623e626,
14. Yüce S, Uysal İEO, Dogan M, Ersin T, Müderris S: Canalicular adenoma of the palate. J Craniofac Surg. 2012;23: e396ee398,
15. McFarland J: The histopathologic prognosis of salivary gland mixed tumors. Am J Med Sci. 1942;203:502e519.
16. Yoon AJ, Beller DE, Woo VL, Pulse CL, Park A, Zegarelli DJ: Bilateral canalicular adenomas of the upper lip. Oral Surg Oral Med Oral Pathol Oral Radiol Endod. 2006;102:341e343.
17. Handley TPB, Markose G, Hunter K, Currie WJR: Ulcerated palatal canalicular adenoma: A case series and review of the literature. Oral Surg. 2009;1:162e166.
18. Stramandinoli-Zanicotti RT, Cesa TS, Giustina JD, Bahr JA, Schussel JL, Sassi LM: Canalicular adenoma of the minor salivary gland in the upper lip: case report. J Oral Diag. 2012;1:4e6.

19. Dayisoylu EH, Pampu AA, Mungan S, Taskesen F: Intra-mandibular canalicular adenoma: Report of a rare case. *J Pak Med Assoc.* 2012;62:1239e1241.
20. Cassoni A, Terenzi V, Della Monaca M, Bartoli D, Battisti A, Rajabtorik Zadeh O: Parapharyngeal space benign tumours: Our experience. *J Craniomaxillofac Surg.* 2014;42:101e105.
21. Samar ME, Avila RE, Fonseca IB, Anderson W, Fonseca GM, Cantín M. *Int J Clin.* 2014;15:8205e8210.
22. Huebner TA, Almubarak H, Drachenberg CB, Papadimitriou JC. Canalicular Adenoma-search for the cell of origin: Ultrastructural and immunohistochemical analysis of 7 cases and review of the literature. *Ultrastruct Pathol.* 2014 Apr;38(2):74–82.
23. Daley TD, Gardner DG, Smout MS: Canalicular adenoma: Considerations on differential diagnosis and treatment. *J Oral Maxillofac Surg.* 1984a;42:728e730
24. Daley TD, Gardner DG, Smout MS: Canalicular adenoma: not a basal cell adenoma. *Oral Surg Oral Med Oral Pathol Oral Radiol Oral Endod.* 1984b;57:181e188.
25. Matsuzaka K, Murakami S, Shimono M, Inoue T: Canalicular adenoma arising in the upper lip: Review of the pathological findings. *Bull Tokyo Dent Coll.* 2004; 45:229e233.
26. Grimm EE, Rulyak SJ, Sekijima JH, Yeh MM: Canalicular adenoma arising in the esophagus. *Arch Pathol Lab Med.* 2007; 131:1595e1597.
27. Jones AV, Craig GT, Speight PM, Franklin CD: The range and demographics of salivary gland tumours diagnosed in a UK population. *Oral Oncol.* 2008;44: 407e417.
28. Tyralik D, Dzierwa-Gawron A, Ryś J: Canalicular adenoma of the upper lip. Metachronous (multifocal) canalicular adenoma of the upper lip: A case report of an unusual finding. *Pol J Pathol.* 2013; 64:71e74.
29. Siqueira CS, Fernandes KS, Vivas AP, Pinto Ddos Jr S, de Sousa SC: Clinical and histological features of multifocal canalicular adenomas of the upper lip. *Braz Dent J.* 2013;24:542e546.
30. Thompson LD, Bauer JL, Chiosea S, McHugh JB, Seethala RR, Miettinen M, et al: Canalicular adenoma: A clinicopathologic and immunohistochemical analysis of 67 cases with a review of the literature. *Head Neck Pathol.* 2015;9:181e195.
31. Olsen KD. Tumors and surgery of the parapharyngeal space. *Laryngoscope.* 1994;104:1–28.
32. Carrau RL, Myers EN, Johnson JT. Management of tumors arising in the parapharyngeal space. *Laryngoscope.* 1990;100:583–589. DOI: 10.1288/00005537199006000-00006
33. John DG, Carlin WV, Brown MJ. Tumour of the parapharyngeal space. *JR CollSurgEdinb.* 1988;33:56–60.
34. Mendelsohn AH, Bhuta S, Calcaterra TC, et al. Parapharyngeal space pleomorphic adenoma: a 30-year review. *Laryngoscope.* 2009;119:2170–2174. DOI:10.1002/lary.20496
35. Rajendran R, Shivapathasundharam B. New Delhi: Elsevier. Shafer's Textbook of oral pathology, Seventh edition; 2017.
36. Phore S, Singh R. Canalicular adenoma: A rare case report. *CHRISMED J Health Res.* 2018;5(2):152–3.
37. Peraza AJ, Wright J, Gómez R. Canalicular adenoma: A systematic review. *J Craniomaxillofac Surg.* 2017 Oct;45(10): 1754–1758.
38. Rousseau A, Mock D, Dover DG, Jordan RC. Multiple canalicular adenomas: A case report and review of the literature. *Oral Surg Oral Med Oral Pathol Oral Radiol Endod.* 1999 Mar;87(3):346–50.
39. Azevedo LR, Dos Santos JN, De Lima AA, Machado MA, Gregio AM: Canalicular adenoma presenting as an asymptomatic swelling of the upper lip: A case report. *J Contemp Dent Pract.* 2008;1:91e97.

© Copyright (2024): Author(s). The licensee is the journal publisher. This is an Open Access article distributed under the terms of the Creative Commons Attribution License (<http://creativecommons.org/licenses/by/4.0>), which permits unrestricted use, distribution, and reproduction in any medium, provided the original work is properly cited.

Peer-review history:

The peer review history for this paper can be accessed here:

<https://www.sdiarticle5.com/review-history/113254>