



Adolescent Female with Acute-onset Abdominal Pain

**Parwaiz Rashidzada ^{a++*}, Rolando Guevarra ^{b#}
and Cornelia Muntean ^c**

^a PGY-4, Good Samaritan University Hospital, USA.

^b Good Samaritan University Hospital, USA.

^c Pediatric Emergency Medicine, Good Samaritan University Hospital, USA.

Authors' contributions

This work was carried out in collaboration among all authors. All authors read and approved the final manuscript.

Article Information

DOI: 10.9734/IJMPCR/2024/v17i1362

Open Peer Review History:

This journal follows the Advanced Open Peer Review policy. Identity of the Reviewers, Editor(s) and additional Reviewers, peer review comments, different versions of the manuscript, comments of the editors, etc are available here: <https://www.sdiarticle5.com/review-history/108912>

Case Study

Received: 22/11/2023
Accepted: 27/01/2024
Published: 01/02/2024

ABSTRACT

Background: Sigmoid volvulus is a more common cause of abdominal pain in geriatric patients. It is an uncommon cause for a pediatric patient, especially when dealing with an adolescent patient. Here we discuss an uncommon presentation of sigmoid volvulus.

Case Description: A 14-year-old female presents with sudden-onset abdominal pain found to have sigmoid volvulus on CT imaging. She eventually underwent sigmoidoscopy for reduction and was monitored for 24 hours post-procedure.

Conclusion: This case demonstrates the importance of having a high index of suspicion when a patient presents with volvulus, especially with adolescence. Although rare, it should always be on the differential due to its high rate of mortality if diagnosed late.

Keywords: *Sigmoid volvulus; abdominal pain; pediatric population.*

⁺⁺ Pediatric Emergency Medicine Fellow;

[#] Pediatric Gastroenterologist;

^{*}Corresponding author: E-mail: parwaiz.rashidzada@gmail.com;

1. INTRODUCTION

Abdominal pain is one of the most common complaints in the Emergency Department. Volvulus of the colon may arise in the sigmoid colon, caecum, splenic flexure, and transverse colon, in descending order of frequency [1,2]. Sigmoid volvulus is an uncommon cause of abdominal pain in pediatric patient, let alone adolescent patients. Sigmoid volvulus is a rare source of intestinal obstruction in the pediatric population. Volvulus occurs when a loop of intestine twists around itself along with the mesentery resulting in bowel obstruction. Here, we discuss a case that initially had us thinking of a different diagnosis and were caught by surprise.

2. CASE DESCRIPTION

2.1 ED Course

A previously healthy 14-year-old female presented to the pediatric emergency department (PED) with acute onset abdominal pain that occurred approximately 2 hours prior to arrival. She endorsed a cramping-like sensation earlier that morning while at school that intensified throughout the day. Along with abdominal pain, she complains of nausea, non-bloody diarrhea, and hot flashes. She was hemodynamically stable on arrival to the PED. Upon evaluation, she was noted to be uncomfortable in appearance, laying in the fetal position and experiencing intermittent episodes of lower abdominal pain. On physical examination, there was notable tenderness to palpation in the periumbilical and lower abdomen without distension. Involuntary guarding was noted during pain episodes, but her abdomen was soft and nontender in between the painful episodes. During her pain-free periods she was well-appearing, smiling, and able to stand, whereas when in pain, she is lying in the knee-to-chest position and ill-appearing, a very uncommon presentation. Complete blood count (CBC), comprehensive metabolic panel (CMP), and a urinalysis were sent and she was given intravenous (IV) analgesics, as well as IV fluids. Initial blood work demonstrated an elevated glucose (204) and leukocytosis with a neutrophilic predominance. Also notable that although a urinalysis was obtained that showed a glucosuria (>1000), she struggled to urinate due to pain on initiation secondary to abdominal pain. Ultrasounds of the pelvis and abdomen were unremarkable, however were suboptimal due to

increased bowel gas. Computer Tomograph (CT) of the Abdomen and Pelvis with oral and IV contrast (Figs. 1,2) was performed and demonstrated marked distension of the sigmoid colon with a swirled appearance of bowel mesentery concerning for volvulus. At that time, both pediatric gastroenterology and surgery were consulted. The patient was taken to the operating room for surgical intervention, undergoing sigmoid decompression (Fig. 3). Patient was then admitted to the pediatric service for monitoring.

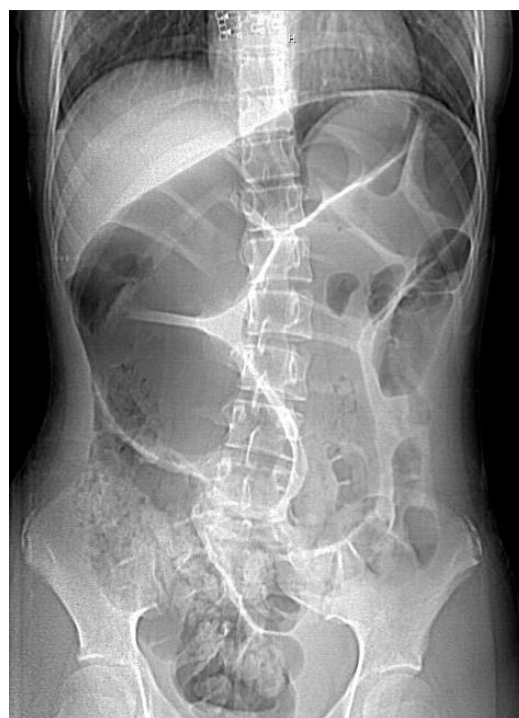

Fig. 1. Abdominal radiograph demonstrating distended bowel

2.2 Hospital Course

Patient underwent an uncomplicated successful reduction of sigmoid volvulus with sigmoidoscopy. In the operating room the site found to be easily reducible, however noted to be more hyperemic than normal with minimal loss of vascular markings, but no bleeding, ulcerations, or sign of bowel necrosis (Fig. 4). She was monitored overnight in the pediatric ward. On re-evaluation the following day, she appeared comfortable with minimal abdominal pain and passing flatus. Two days later she was taken to the operating room for a laparoscopic sigmoidectomy with primary anastomosis. Procedure was uncomplicated and successful. A single Jackson-Pratt (JP) drain was placed,

which drained small amounts of serosanguinous fluid. Labs and urinalysis were repeated during hospitalization and were normalizing. Patient was

discharged on post-operative day (POD) 5 (hospital course day 7) with close follow up with Pediatric Gastroenterology and Surgery.

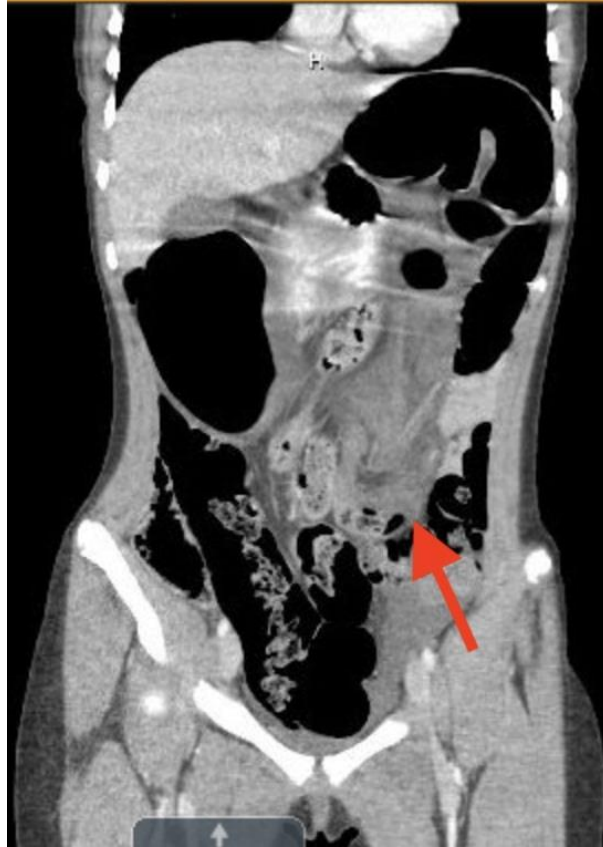

Fig. 2. CTAP coronal view; Whirl Sign

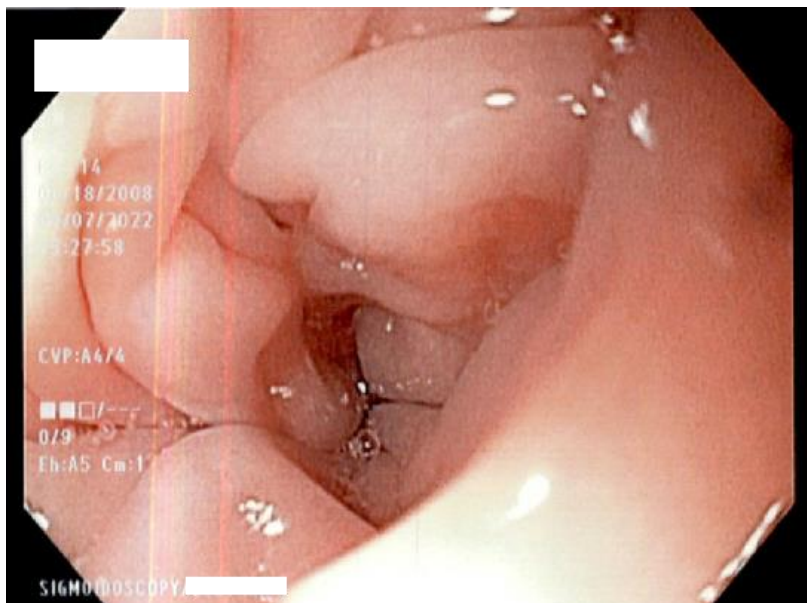


Fig. 3. Initial twisted segment of sigmoid colon

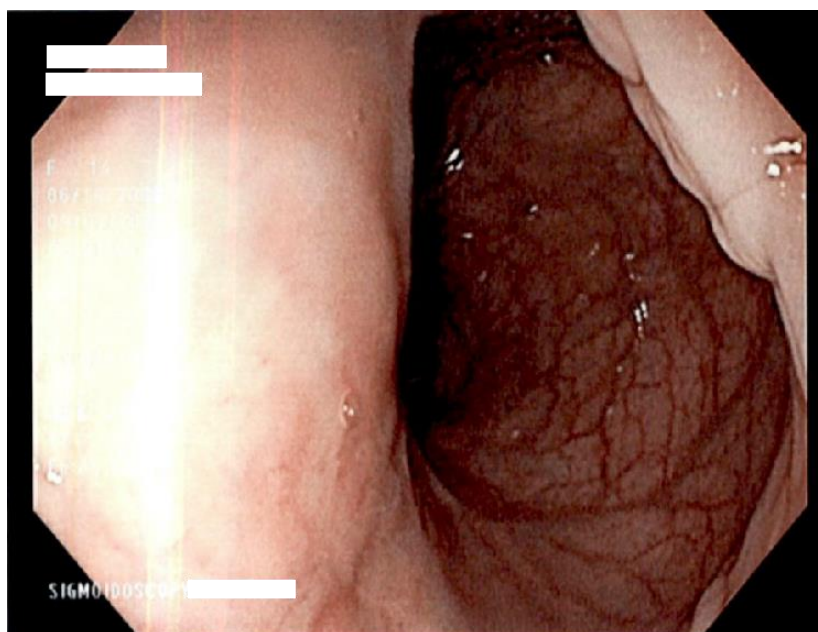


Fig. 4. Untwisting segment of sigmoid colon

3. DISCUSSION

Pediatric abdominal pain is one of the most common reasons patients present to the emergency department. Abdominal pain etiologies vary greatly depending on the site of pain. Sigmoid volvulus is a more common cause of abdominal pain in elderly geriatric patients. It is an uncommon cause of abdominal pain in pediatric patient, let alone adolescent patients. Sigmoid volvulus is a rare source of intestinal obstruction in the pediatric population. Volvulus occurs when a loop of intestine twists around itself along with the mesentery resulting in bowel obstruction. Typical symptoms upon presentation are abdominal distension, pain, vomiting, hematochezia, and/or constipation. Symptoms could be gradual or sudden in onset. In volvulus, the most worrisome complication is bowel ischemia secondary to poor perfusion due to twisting of bowel resulting in necrotic bowel. One thing to always be cognizant about is sepsis. Despite our patient being slightly tachycardic, likely due to pain, she was afebrile on arrival with normal blood pressure, so sepsis was lower on our differential initially.

Volvulus is associated with intestinal malrotation, long mesentery, Hirschsprung disease, pregnancy, abdominal adhesions, chronic laxative use, muscle myopathies, and/or chronic constipation, none of which were present in our patient. Emeka et. al noted that the occurrence of

sigmoid volvulus with intestinal malrotation is more commonly seen in the neonate/infant age usually in the setting of Hirschsprung disease [3]. Median age was found to range from 7 to 12 years and more commonly seen in male patients with a ratio of 3.5:1. Interestingly with our patient, she had sudden-onset intermittent lower abdominal pain, initially having us worry about ovarian torsion due to the intermittent nature. Sonograms were negative for ovarian torsion and inconclusive for acute appendicitis. Once the CT scan was completed, it was surprising to see the marked colonic dilation and volvulus. At this time, pediatric gastroenterology and surgery were consulted and patient was taken for endoscopic decompression. This marked distension is likely what led to her urinary complaints of dysuria. It was likely that the distended sigmoid colon was compressing her bladder and/or urethra preventing urination. Due to the pain from the sigmoid volvulus, her glucosuria and hyperglycemia were secondary to a stress response, as they were repeated prior to discharge and were within normal limits. For our patient, no identifiable etiology was found as a cause of her sudden volvulus.

Treatment of sigmoid volvulus is controversial in the pediatric population. Some studies have shown that sigmoid volvulus have resolved spontaneously with just fluid resuscitation, antibiotics, and pain control. However, the initial treatment for sigmoid volvulus is sigmoidoscopy,

which can also aid in the diagnosis [4]. The success rate of reduction with an endoscopic approach can range from 50-100%. At times, a flatus tube ("red rubber" tube) is inserted into the rectum following endoscopic reduction to assist in preventing early recurrence of the volvulus. Despite these efforts, sigmoid volvulus does have a high recurrence rate, therefore the definitive management is operative. With conservative management, recurrence rates range between 40-60% [5]. It is recommended that surgical intervention take place within 48 hours of endoscopic reduction. Sigmoidectomy with either primary anastomosis or colostomy. At this time, there are no reports of recurrence of sigmoid volvulus when sigmoidectomy is performed [6]. After discussion with the surgeon and patients' family and shared decision making, family opted to undergo sigmoidectomy with primary anastomosis in order to avoid colostomy placement [7].

A high index of suspicion is always needed when a patient presents with volvulus, especially if presenting in adolescence. Although uncommon in pediatric patients, it is more common in infants and younger patients as previously stated. Usually this can be seen with plain films of the abdomen. When patients present with vague chief complaints such as abdominal pain, headache, respiratory distress, etc., the differential is broad. Again, our patients' presentation was unique as she did not have vomiting, nor abdominal distension and her pain was intermittent. Although rare, it should always be on the differential due to the high rate of mortality if not caught early due to its dire complications.

4. OUTCOME

Our patient was safely discharged to home. It was noted that patient presented to the PED 5 days after she was discharged with abdominal pain over the site of the JP drain. On physical examination, her abdomen was noted to be soft, non-distended, with mild tenderness over the JP drain site. The JP drain site was clean, dry, and intact with no bleeding or discharge noted. She had laboratory tests done, such as complete blood count (CBC) and comprehensive metabolic panel (CMP), were unremarkable. Two-view abdominal x-ray showed non-specific bowel gas pattern with the catheter in place along with mild constipation. Her pain was improved with acetaminophen and was discharged from the

PED stable. She continues to follow up in surgery clinic and is doing well.

5. CONCLUSION

A high index of suspicion is needed when a patient presents with volvulus, especially if during the adolescent period. Although rare, it should always be on the differential due to its high rate of mortality if diagnosed late.

ETHICAL APPROVAL

As per international standards or university standards written ethical approval has been collected and preserved by the author(s).

CONSENT

As per international standards, parental written consent has been collected and preserved by the author(s).

COMPETING INTERESTS

Authors have declared that no competing interests exist.

REFERENCES

1. Madiba TE, Thomson SR. The management of sigmoid volvulus. *Journal of the Royal College of Surgeons of Edinburgh*. 2000 Apr 1;45(2).
2. Northeast ADR, Dennison AR, Lee EG. Sigmoid volvulus: New thoughts on epidemiology. *Dis Colon Rectum*. 1984;27:260-1.
3. Emeka CK. Sigmoid volvulus in a teenager. *Journal of Pediatric Surgery Case Reports*. 2022;76:102119. Available: <https://doi.org/10.1016/j.epsc.2021.102119>
4. Madhavnarayan Totadri V, Vetri R, Sainath S. Pediatric sigmoid volvulus: A report on two cases. *Cureus*; 2022. Available: <https://doi.org/10.7759/cureus.28400>
5. O'Keefe LM, Hu YY, Thaker S, Finck C. Sigmoid volvulus: A pediatric case report and Review of management. *Journal of Pediatric Surgery Case Reports*. 2016;7:4-7. Available: <https://doi.org/10.1016/j.epsc.2016.02.003>
6. Esmat HA. Sigmoid volvulus in a teenager, successfully managed with endoscopic detorsion: An unusual case report and

- review of the literature. International Journal of Surgery Case Reports. 2020;77:875–879. Available: <https://doi.org/10.1016/j.ijscr.2020.11.152>
7. Patel RV, Njere I, Campbell A, Daniel R, Azaz A, Fleet M. Sigmoid volvulus in an adolescent girl: Staged management with emergency colonoscopic reduction and decompression followed by elective sigmoid colectomy. Case Reports. 2014aug. Available: <https://doi.org/10.1136/bcr-2014-206003>

© 2024 Rashidzada et al.; This is an Open Access article distributed under the terms of the Creative Commons Attribution License (<http://creativecommons.org/licenses/by/4.0>), which permits unrestricted use, distribution, and reproduction in any medium, provided the original work is properly cited.

Peer-review history:
The peer review history for this paper can be accessed here:
<https://www.sdiarticle5.com/review-history/108912>