



# Laser Excision of a Focal Fibrous Hyperplasia: A Case Report

**Nida Shaikh<sup>a++\*</sup>, Sonia Sodhi<sup>b#†</sup>, Lata Kale<sup>a†</sup>,  
Firdous Shaikh<sup>c#†</sup> and Rayyan Hashmi<sup>a++</sup>**

<sup>a</sup> Department of Oral Medicine and Radiology, CSMSS Dental College & Hospital, Aurangabad, India.

<sup>b</sup> Consultant Oral Physician and Radiologist, Senior Dentist, Sodhi Dental Clinic, Aurangabad, Maharashtra, India.

<sup>c</sup> Consultant Oral Physician and Radiologist, Senior Dentist, Alfa Dental Clinic, Nagpur, Maharashtra, India.

## **Authors' contributions**

*This work was carried out in collaboration among all authors. Author NS designed the study, contributed to conception and design drafted manuscript and revised the manuscript. Authors SS, LK, FS and RH critically revised manuscript, gave final approval and contributed to analysis and interpretation. All authors read and approved the final manuscript.*

## **Article Information**

### **Open Peer Review History:**

This journal follows the Advanced Open Peer Review policy. Identity of the Reviewers, Editor(s) and additional Reviewers, peer review comments, different versions of the manuscript, comments of the editors, etc are available here: <https://www.sdiarticle5.com/review-history/110141>

**Case Report**

**Received: 07/10/2023**

**Accepted: 11/12/2023**

**Published: 28/12/2023**

## **ABSTRACT**

**Background:** The fibroma most commonly appears as a nodular growth mainly on buccal mucosa along the occlusal plane. Other sites involved are gingiva, palate, lips, and tongue. The conservative surgical approach is best for management of this lesion. The effects of chronic local irritation have been seen commonly in the form of fibroma or mucocele in children.

**Case presentation:** A 12-year-old girl with the chief complaint of swelling in the lower lip reported to our department which was diagnosed as fibroma both clinically and histologically. Diode laser excision was done under local anesthesia (LA). Post-operative complications were not evident. The wound healing was satisfactory.

<sup>++</sup> Postgraduate Student;

<sup>#</sup> MDS;

<sup>†</sup> HOD & Dean;

<sup>‡</sup> Private Practitioner;

<sup>\*</sup>Corresponding author: Email: [sk.nida98@gmail.com](mailto:sk.nida98@gmail.com);

**Conclusion:** The fibromas are benign and self-limiting conditions which are diagnosed based on clinical and pathological examination. Diode laser treatment is highly effective and is a simple and safe method.

**Keywords:** Focal fibrous hyperplasia; traumatic fibroma; diode laser.

## 1. INTRODUCTION

Inflammatory hyperplastic lesion may be defined as "an increase in the size of an organ or tissue due to an increase in the number of constituent cells, as a local response of tissue to injury [1].

It is also known as a traumatic fibroma, fibrous nodule, focal fibrous hyperplasia (FFH), or an oral polyp, or an irritational fibroma. The growth has a smooth surface, normal-coloured mucosa, a sessile or pedunculated base, and a firm consistency. Due to decrease vascularity, the lesion appears as a round or oval, sessile, broad-based swelling that is painless and has a lighter colour than the surrounding tissue. A smooth-surfaced, hard, asymptomatic nodule with a pink or flesh-coloured tint is the outward manifestation of a clinically traumatic fibroma [2].

The treatment plan includes firstly removal of the cause of irritation and complete excision of the lesion. Excision can be done by the scalpel, electrocautery or Laser. The term LASER is an acronym for "Light Amplification by Stimulated Emission of Radiation." Miamian introduced the laser in dentistry in 1960. Diode lasers have a high affinity for melanin and hemoglobin, enabling it to cut precisely and coagulate the target tissue providing excellent hemostasis, better field visibility, and better acceptance by the patients [3-6].

Studies that have comprehensively reported the incidence of oral soft tissue lesions are as follows:

In a year 2014 study done by Thiago de Santana Santos et al., from Brazil in a review study cases concluded that of the 1290 soft-tissue reactive lesions of the oral cavity, histologically 193 were confirmed as FFH with a prevalence of 15%. Buccal mucosa, lower lip and dorsal tongue were the most common affected sites [7].

Mohammad Raza Zarie et al., from Iran in a review of 172 cases done in a year 2006 evaluated a total of 412 records, reactive hyperplasia were 197 (48%) of the lesions. Of these, females cases (mean age,  $39.35 \pm 18.37$ )

were 124 (62.8%) and males cases were 73 (37.2%) [8].

In 2016 case reports done by Kshitij Vipin Pardeshi et al., from India states that the peak occurrence in the second decade with high predilection for females and after the third decade of life declining incidence were suggestive of the possibility that in the presence of a chronic injury female hormones contribute to an increased production and accumulation of collagen by fibroblasts [9].

## 2. CASE REPORT

A 12-year-old girl visited to Oral Medicine and Radiology Department with the complaint of small painless overgrowth in the lower lip on left side. Patient also complained of discomfort associated with overgrowth. Patient complains that initially swelling was small in size and was gradually increasing.

Clinically - Solitary, nodular, pink colored swelling seen on lower left labial mucosa around the size of  $1 \times 1$  cm approximately.

On palpation - nodular, movable, soft in consistency, pedunculated, nontender, compressible, absence of discharge. Lymph nodes were non palpable [Fig. 1].

The differential diagnosis of irritation fibroma was made depending upon history and clinical findings.

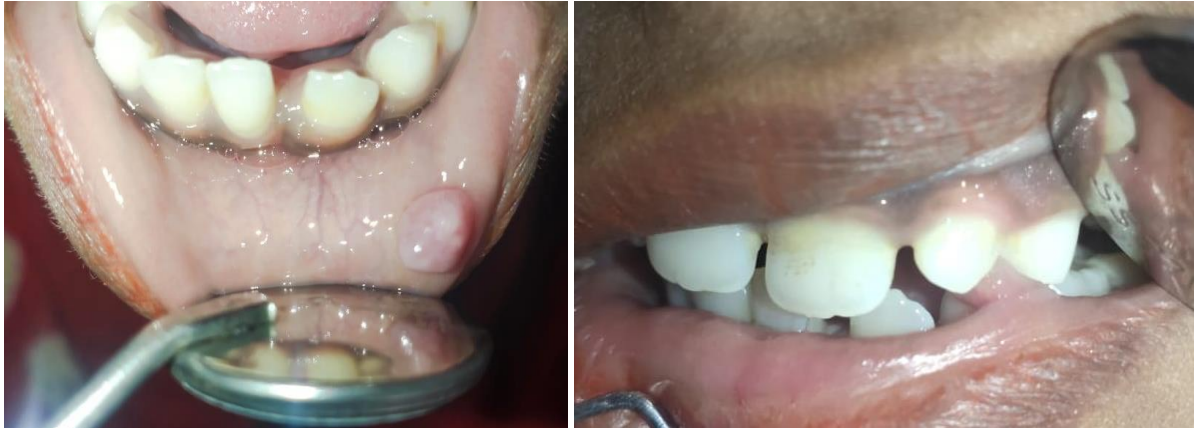All blood counts were in normal limits when preop CBC was done. Then An excision biopsy was planned with patient's consent.

Management - laser diode excision was done under LA in the Department of Periodontology at around 11:30 AM. With the help of tissue forceps lesion was held and was separated from the base with a diode laser. LX 16 laser (laser stop) with peak power 6 W, frequency 10 Hz, duty 50%, time 20S, valid power 3.0 W, energy 60J, 976 nm wavelength (fibroma excision mode) was used [Fig. 2, Fig. 3].

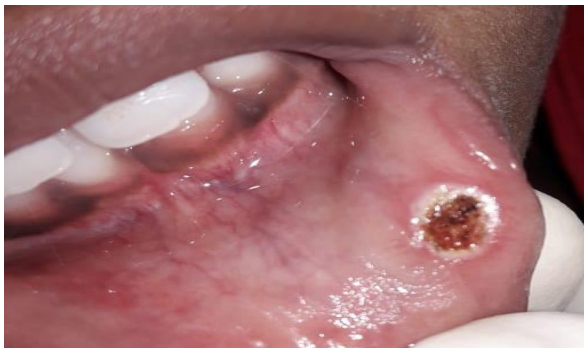Specimen was stored in formalin and sent to an oral pathology department for confirmation of diagnosis.

Histopathology – tissue reveals covering of stratified squamous epithelium along with shortening of stratified squamous epithelium and abundant of collagen fibers deposited in

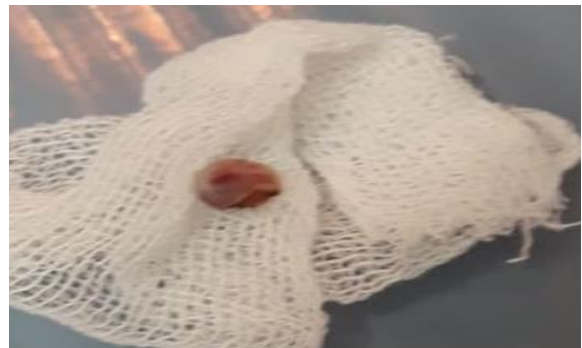connective tissue suggestive of fibro epithelial hyperplasia (fibroma). [Fig. 4] Follow up done after 1 week. [Fig. 5].



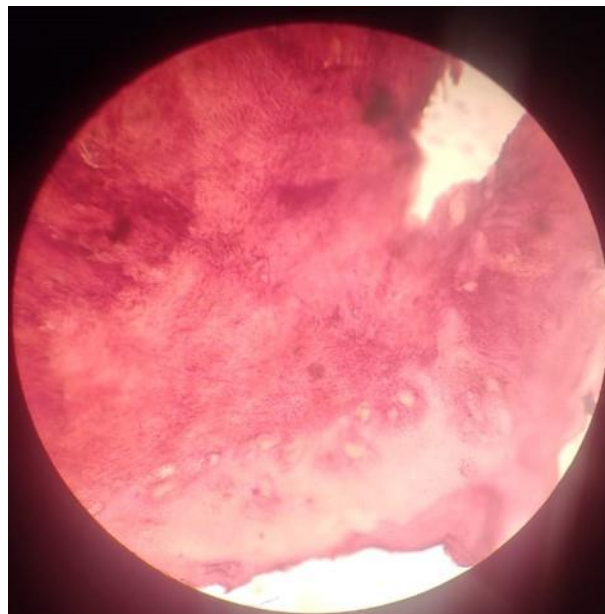
**Fig. 1. Preoperative pictures**



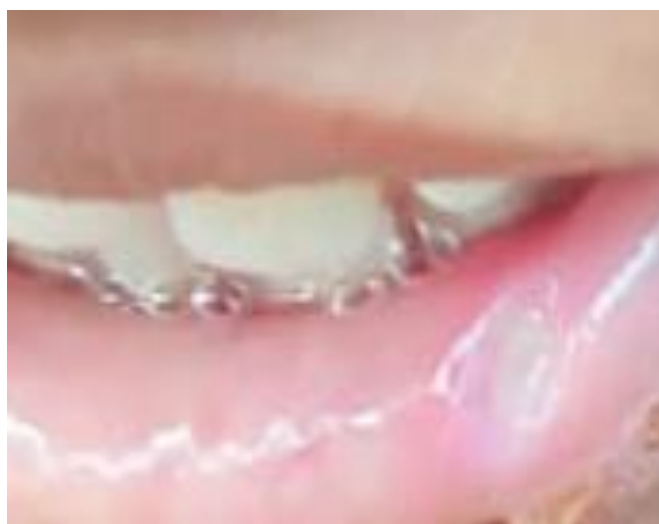**Fig. 2. Postoperative picture**



**Fig. 3. Excised tissue**



**Fig. 4. Histopathology**



**Fig. 5. 1 week follow up**

### **3. DISCUSSION**

Fibroma is the most common benign soft tissue tumor in the oral cavity. Due to trauma or local irritation most fibromas represent reactive FFH. Fibroma are microscopically similar to inflammatory hyperplasia but is a neoplasm of connective tissue origin. Hyperplasia is a self-limiting process unlike neoplasia and hyperplastic cells sometimes show regression after the removal of the stimulus. Neoplasm can also occur from chronic irritation as neoplastic tissue sometimes resembles that of hyperplastic tissue that do not regress [10]. The general literature have cited the reason for a few of the oral lesions like irritation fibroma and mucocele, arising as a result of oral habits such as lip biting/sucking [11]. Unhealthy habits become harmful when repeated excessively, contributing to an Oro facial muscular imbalance which is associated with alterations in bone growth, dental malposition, and dento facial abnormalities. Biting, licking, or sucking of lips and cheeks frequently are accompanied by chapping, dryness, erosion, irritation of one of both lips and/or vermilion borders [12]. Diode laser radiation is an excellent, simple, and safe form of treatment of oral lesions. This procedure is bloodless with postoperative edema, and discomforts along with better visibility and less damage to adjacent tissues. Compared to conventional methods, laser surgery is less time consuming, less painful, more precise in the treatment of soft tissue lesions, produces less scar-tissue contraction, and maintains the elastic tissue properties [13]. According to Zarie et al., gingiva is the most common location of the lesion. The lesion is usually asymptomatic,

occurs most common in the fourth to the sixth decade of life, and 1:2 is the male to female ratio. [11]. According to Thiago de et al., the development of FFH is closely related to mechanical trauma indicating that it is a true neoplasm. [7] According to Madhuri Alankar Sawai et al., Intraoral fibroma is a common lesion following trauma or tissue injury that develops in the oral cavity. It is more frequently seen in the third and fourth decades of life with a strong female predilection. The most common site of traumatic fibroma is buccal mucosa along the plane of occlusion. Diode laser has been found to be safe, less painful, and with better post-operative outcomes [14]. According to Bhashit Diwan et al., the simple, efficient, and affordable method for treating traumatic fibroma and giving aesthetic and functional clearance to the patient surgical excision of traumatic fibroma is with a scalpel and diode laser. In contrast, the removal using a diode laser demonstrates no bleeding and less discomfort and pain during surgery than the conventional scalpel technique [2]. Riddhi R Asundaria et al. concluded that although irritational fibroma are benign but they can be quite bothersome to the patient and requires surgical removal. Laser treatment remains the most effective for a variety of oral lesions, with greater patient acceptance and greater physician convenience [15].

### **4. CONCLUSIONS**

Fibroma are mostly diagnosed based on clinical and pathological examination. They are benign and self-limiting conditions in most of the cases. Complete excision has been the choice of

treatment. Our patient reported a good prognosis without any post-operative complications.

Diode laser treatment was highly effective and if used according to the protocol, is a simple and safe method.

## CONSENT

As per international standards or university standards, patient(s) written consent has been collected and preserved by the author(s).

## ETHICAL APPROVAL

As per international standards or university standards written ethical approval has been collected and preserved by the author(s).

## COMPETING INTERESTS

Authors have declared that no competing interests exist

## REFERENCES

1. Wood NK Goaz PW. Differential diagnosis of oral and maxillofacial lesions. 5th ed. Missouri: Mosby. 2006:136-8.
2. Diwan B, Shirbhate U, Bajaj P, Reche A, Pahade A. Conventional scalpel and diode laser approach for the management of traumatic fibroma. Cureus. 2023;27;15(10).
3. Jain PR, Jain S, Awadhiya S, Sethi P. Excision of traumatic fibroma by diode laser. Journal of Dental Lasers. 2018; 1;12(2):67.
4. Madan E Pati RC Kumar V. Management of lingual traumatic fibroma in an epileptic patient using diode laser. University Journal of Dental Sciences. 2023;9(1).
5. Tak MM, Chalkoo AH, Ahmad MB, Lone AI. Diode laser-assisted excision of oral soft-tissue lesions: A case series. Journal of Indian Academy of Oral Medicine and Radiology. 2023 Jul 1;35(3):449-51.
6. Wigdor HA, Walsh Jr JT, Featherstone JD, Visuri SR, Fried D, Waldvogel JL. Lasers in dentistry. Lasers in Surgery and Medicine. 1995;16(2):103-33.
7. de Santana Santos T, Martins-Filho PR, Piva MR, de Souza Andrade ES. Focal fibrous hyperplasia: A review of 193 cases. Journal of Oral and Maxillofacial Pathology: JOMFP. 2014;18(Suppl 1):S86.
8. Zarei MR, Chamani G, Amanpoor S. Reactive hyperplasia of the oral cavity in Kerman province, Iran: A review of 172 cases. British Journal of Oral and Maxillofacial Surgery. 2007;1;45(4): 288-92.
9. Pardeshi KV Mirchandani NM Agrawal AA Kale TM. Fibrous hyperplasia: Two case reports. Journal of Dental Lasers. 2016;10(1):23.
10. Shafer WG Hine MK Levy BM. A Textbook of oral pathology. 6th ed. Philadelphia: WB Saunders. 2009:126-7.
11. Barbería E Lucavechi T Cárdenas D Maroto M. An atypical lingual lesion resulting from the unhealthy habit of sucking the lower lip: clinical case study. Journal of Clinical Pediatric Dentistry. 2006;30(4):280-2.
12. Turgeon-O'Brien H Lachapelle D Gagnon PF Larocque I Maheu-Robert LF. Nutritive and nonnutritive sucking habits: A review. ASDC Journal of Dentistry for Children. 1996;63(5):321-7.
13. Pai JB Padma R Malagi S Kamath V Shridhar A Mathews A. Excision of fibroma with diode laser: A case series. Journal of Dental Lasers. 2014;1;8(1):34.
14. Romero-Reyes M Uyanik JM. Orofacial pain management: Current perspectives. Journal of Pain Research. 2014;21: 99-115.
15. Asundaria RR Tavargeri A. Excision of traumatic fibroma of the tongue in a pediatric patient: A Case Report. International Journal of Clinical Pediatric Dentistry. 2023;16(1):166.

© 2023 Shaikh et al; This is an Open Access article distributed under the terms of the Creative Commons Attribution License (<http://creativecommons.org/licenses/by/4.0>), which permits unrestricted use, distribution, and reproduction in any medium, provided the original work is properly cited.

Peer-review history:

The peer review history for this paper can be accessed here:

<https://www.sdiarticle5.com/review-history/110141>