



Non-surgical Treatment of a Non-vital, Immature Permanent Tooth with a Large Periapical Abscess: A Case Report with 8-month Follow-up

Mahima Panwar ^{a*}, Madhukar Yadav ^{a#}, Sonal Gupta ^{a†}, Riya Ojha ^{a#}
and Rushika Velaparambil ^{a#}

^a Department of Pediatric and Preventive Dentistry, Kanti Devi Dental College, Mathura, Uttar Pradesh, India.

Authors' contributions

This work was carried out in collaboration among all authors. All authors read and approved the final manuscript.

Article Information

DOI: 10.9734/ARRB/2022/v37i930534

Open Peer Review History:

This journal follows the Advanced Open Peer Review policy. Identity of the Reviewers, Editor(s) and additional Reviewers, peer review comments, different versions of the manuscript, comments of the editors, etc are available here: <https://www.sdiarticle5.com/review-history/91555>

Case Study

Received 04 July 2022
Accepted 09 September 2022
Published 15 September 2022

ABSTRACT

Aim: The purpose of this case report is to present a non-surgical treatment of a non-vital immature upper central incisor with a large periapical abscess within 8 months of follow-up.

Methods and Materials: A traumatic case was presented in which a paste of calcium hydroxide and iodoform (Metapex®) was placed in the root canal of an immature permanent tooth with a large periapical abscess. Affected teeth were radiographically evaluated periodically over 8 months after paste insertion. At the end of 8 months, this case showed persistent root growth and apexification with no evidence of periapical radiolucency. After that, a normal root canal treatment was performed.

Conclusion: In this clinical case, calcium hydroxide and iodoform paste (Metapex®) was found to induce apical closure radiographically and clinically. At 8 months, the periapical abscess was shown to have healed with continued root growth.

Keywords: Metapex; calcium hydroxide; apexification.

[#] Post Graduate Trainee;

[†] Head of the Department;

*Corresponding author: E-mail: mahimabds2017@gmail.com;

1. INTRODUCTION

Traumatic dental injuries involving anterior teeth is a relatively common occurrence during childhood resulting in inflammation or necrosis of the pulp and subsequent incomplete development of root apices [1]. Such teeth present with wide root canals and open apices cause the endodontic treatment technically more difficult and time-consuming [2]. "Due to the lack of an apical barrier to contain the root filling material, the obturation of the root canal with an open apex is difficult. The treatment of choice in such type of case is apexification, i.e. establishing an apical barrier" [3].

"Apexification is a technique responsible for induction of a calcific apical barrier in a root with an open apex or continued development of the apex of an incomplete root with non-vital pulp. Calcium hydroxide is widely used for the apexification process due to its biological and healing performances. Calcium hydroxide combined with other materials has been proved to be the most commonly used material for apex closure. Apexification with calcium hydroxide involves repeated stimulations, for at least 6- 24 months, until apical closure is achieved" [4]. "Metapex consist of iodoform (40.4 percent), calcium hydroxide (30.3percent), and silicone oil (22.4 percent) and has been used as a root canal filling material in primary teeth. It is a viscous paste mixture consisting of calcium hydroxide and iodoform with barium sulphate as an opacifier shown great success when used for pulpectomy in primary teeth" [5].

The superior antimicrobial effects of calcium hydroxide due to the combination with iodoform and to the viscous and oily vehicle, which may

prolong the action of the medicament. The present case report describes the successful non-surgical management of non-vital immature permanent maxillary central incisor with large periapical abscess with 8 months follow-up.

2. CASE REPORT

A 13-year-old patient presented to the Department of Pediatrics and Preventive Dentistry, K.D Dental College (Mathura, UP, India) with a chief complaint of swelling associated with the maxillary permanent right central incisor. Further examination showed no evidence of cavities or fractures, but it was found to be sensitive to ipercussion.

Electric Pulp Tester was used to check the vitality of the pulp, which gave a negative result.

A radiograph revealed an open apex associated with large periapical radiolucency to the right maxillary central incisor. A dental history revealed that the patient had undergone dental trauma with recurrent swelling 2 years earlier.

After local anesthesia, a rubber dam was applied and the access cavity was prepared. Working length was determined with a no. 15 k file and root canal preparation were done till no. 80 k file (DENTSPLY) using circumferential filing motion. The canal was then cleaned and irrigated with 2.5% sodium hypochlorite (Vishal Dentocare Pvt Ltd, Hyderabad) and saline. The canal was dried with the help of paper point, and triple antibiotic paste (metronidazole, minocycline, and ciprofloxacin in the ratio of 1:1:1) mixed with propylene glycol was placed as an intracanal medicament and the cavity was sealed with zinc oxide eugenol.

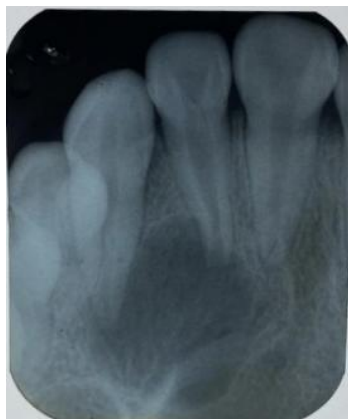

Fig. 1. Pre-operative

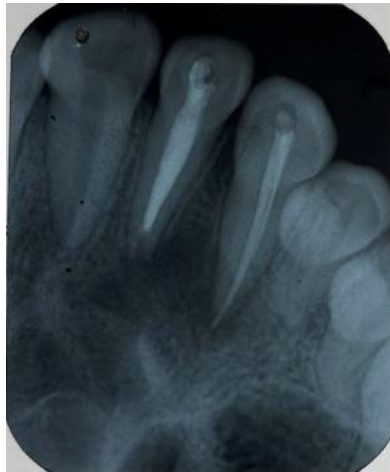

Fig. 2. 2 months follow up

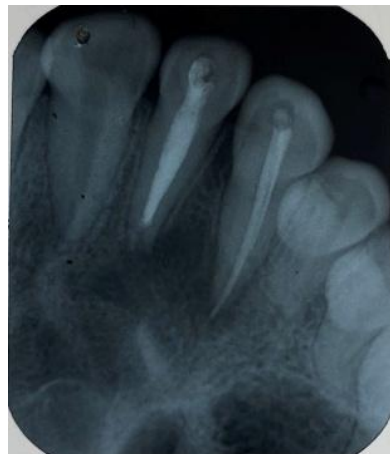

Fig. 3. 3 months follow up

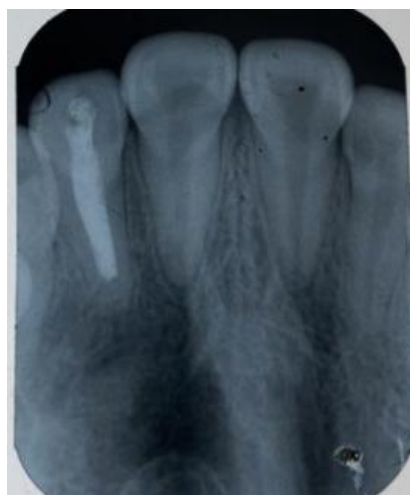

Fig. 4. 5 months follow up

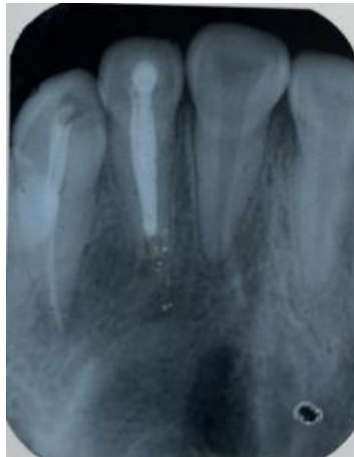


Fig. 5. 6 month follow up

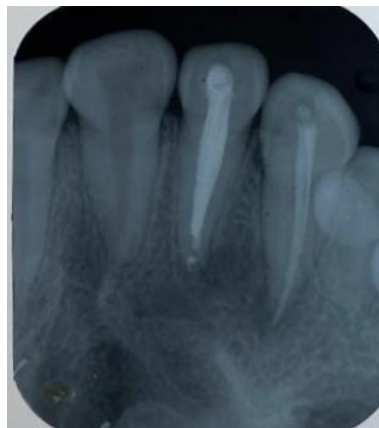

Fig. 6. 8 month follow up

At 14 days recall appointment, the intracanal medicament was replaced with metapex (Meta biomed Co. Ltd., South Korea) and the patient was recalled at 2, 3, 5, 6, and 8-month intervals. Metapex dressing was replaced on every subsequent visits i.e 2, 3, 5, 6, and 8 month. The patient was clinically asymptomatic and radiographic evaluation showed a reduction in the periapical lesion and disclosed significant apical development of the tooth at 3 months intervals. Her 6-month follow-up from this point revealed similar clinical findings and greater healing of the periapical lesion, but without apical closure. After 8 months, it was found radiologically that the apex was closed. Root canal treatment was then performed using gutta-percha cones (Dentsply) in two visits by conventional method.

3. DISCUSSION

“Apexification is the treatment of choice after immature permanent teeth with pulp necrosis is

identified. The procedure involves cleaning and shaping of a canal or removing all necrotic tissue and sealing the tooth with a suitable material placed at the tip to prevent bacterial invasion. The main importance of the apex formation procedure is to achieve an apex stop for compression of the occlusive material”. [6] “Various new materials have been introduced to induce apical barrier formation in devitalized permanent teeth, such as calcium hydroxide paste, lime powder mixed with different vehicles, tricalcium phosphate, collagen phosphate, osteogenic protein-1, bone protein, oxidized cellulose, Mineral trioxide aggregate, etc” [7].

“Metapex is an ideal material for apex formation due to its antibacterial effect on bacterial cell components, mainly lipopolysaccharide (LPS)” (Jiang et al. 2003), and “its high pH value leads to induction of hard tissue formation” (Javelet et al. 1985). “Calcium in contact with tissue in the

apical region appears to induce tissue reactions similar to those in the coronal pulp. The apical process usually takes 6-24 months, and it is recommended to replenish the roots every 3-6 months" [8].

Metapex Paste is an effective material for apicalization of young permanent teeth. Metapex releases lime slowly and tends to stay in the canal and remain effective for a considerable period of time. Using Metapex also has the drawback of being reabsorbed after passing the apex, causing tooth discoloration.

In this study, the access cavity was prepared using glass ionomer cement after Metapex was placed in the root canal. This was done to provide an adequate coronal seal and prevent microleakage.

"A study by Ghosh et al. showed 100% success with metapex in comparison with calcium hydroxide mixed with water and non-setting calcium hydroxide with water" [9].

"A similar finding was reported by Gu et al. for apexification where there was a complete root development and closed apex" [10].

"In another study, Weng estimated 64 young permanent teeth with undeveloped root apex and necrotic pulps. All the teeth was observed for atleast three years, and 24 teeth (37.5percent) successfully achieved the apexification, 37 teeth (57.81 percent) were in the process of root end closure, and only 3 teeth (4.69 percent) failed to achieve apexification. Weng concluded that Metapex paste was an effective material for achieving apexification for younger permanent teeth" [11].

"Lu & Qin compared an antibiotic paste and Metapex paste for their use in apexification. Over a follow-up period of 30 months, they concluded that both materials showed the same level of radiographic success. In cases of periapical inflammation, the antibiotic paste showed superior results" [12].

The present case indicates good results with metapex as an apexification agent taking into consideration the cost factors, simple placement, and radiographic interpretation. Our report noted that there is both clinical and radiographic success in achieving apex. Continued root growth was observed in treated teeth in contrast to barrier formation

4. CONCLUSION

Metapex has shown excellent clinical and radiographic success in promoting continued root growth, inducing apical closure and healing periapical lesions in immature and necrotic young permanent teeth.

CONSENT

As per international standard or university standard, parentals' written consent has been collected and preserved by the author(s).

ETHICAL APPROVAL

As per international standard or university standard written ethical approval has been collected and preserved by the author(s).

COMPETING INTERESTS

Authors have declared that no competing interests exist.

REFERENCES

1. Anantharaj A, Praveen P, Venkataraghavan K, Prathibha RS, Sudhir R, Murali Krishnan B. Challenges in pulpal treatment of young permanent teeth a review. *J Dent Scien Res.* 2011; 2:142
2. Moore A, Howley MF, O'Connell AC. Treatment of open apex teeth using two types of white mineral trioxide aggregate after initial dressing with calcium hydroxide in children. *Dent Traumatol.* 2011;27(3):166-173
3. Purra AR, Ahangar FA, Chadgal S, Farooq R. Mineral trioxide aggregate apexification: A novel approach. *J Conserv Dent.* 2016;19:377-380
4. Sheehy EC, Roberts GJ. Use of calcium hydroxide for apical barrier formation and healing in non-vital immature permanent teeth: A review. *Br Dent J.* 1997;183: 241-246
5. Vipin ahuja, Annapurna ahuja, jaya verma. Apexification with apical growth and closure using Metapex in a Necrotic Immature Permanent Tooth with Periapical abscess: A Case Report with 16 months follow-up. *University Journal of Dental Sciences, An Official Publication of Aligarh Muslim University, Aligarh. India*

6. Mohammadi Z, Dummer PMH. Properties and applications of calcium hydroxide in endodontics and dental traumatology. *International Endodontic Journal*. 2011; 44:697- 730.
7. Lu YM, Qin JN. A comparison of the effect between vitapex paste and antibiotic paste in apexification. *Shanghai Kou Qiang Yi Xue*. 2004;13:449-51.
8. Jiang J, Zuo J, Chen SH, Holliday LS. Calcium hydroxide reduces lipopolysaccharide stimulated osteoclast formation. *Oral Surgery, Oral Medicine, Oral Pathology, Oral Radiology and Endodontics*. 2003;95:348–54.
9. Weng QF. Clinical study on the effect of Vitapex paste in apexification. *Hua Xi Kou Qiang Yi Xue Za Zhi*. 2004;22(3): 214-215.
10. Gu HX, Xu Q, Liu LM, OuyangY. Treatment of chronic apical periodontitis teeth complicated by open apices with Vitapex in the adults. *Shanghai Kou Qiang Yi Xue*. 2007;16(2):140-143.
11. Lu YM, Qin JN. A comparison of the effect between Vitapex paste and antibiotic paste in apexification. *Shanghai Kou Qiang Yi Xue*. 2004; 13(5):449-451.
12. Sridhar N, Tandon S. Continued Root-Growth and Apexification Using a Calcium Hydroxide and Iodoform Paste (Metapex®): Three Case Reports. *J Contemp Dent Pract*. 2010;11(5):63-70.

© 2022 Panwar et al.; This is an Open Access article distributed under the terms of the Creative Commons Attribution License (<http://creativecommons.org/licenses/by/4.0>), which permits unrestricted use, distribution, and reproduction in any medium, provided the original work is properly cited.

Peer-review history:

The peer review history for this paper can be accessed here:
<https://www.sdiarticle5.com/review-history/91555>