



Post-Traumatic Pulmonary Pneumatoceles: A Case Report

Ghizlane Jaabouti ^{a*}, Soumia Bencchakroun ^a,
Chafiq Mahraoui ^a and Naima El Hafidi ^a

^a Division of Pediatric Immuno Allergology and Infectious Diseases, Children University Hospital, Ibn Sina University Hospital, Rabat, Morocco.

Authors' contributions

This work was carried out in collaboration among all authors. All authors read and approved the final manuscript.

Article Information

DOI: 10.9734/AJMAH/2023/v21i9862

Open Peer Review History:

This journal follows the Advanced Open Peer Review policy. Identity of the Reviewers, Editor(s) and additional Reviewers, peer review comments, different versions of the manuscript, comments of the editors, etc are available here: <https://www.sdiarticle5.com/review-history/99116>

Case Study

Received: 20/02/2023

Accepted: 21/04/2023

Published: 23/06/2023

ABSTRACT

Road accidents are the main cause of serious injuries worldwide, accounting for over 10% of trauma cases resulting in death or significant physical impairment. Thoracic injuries, on the other hand, are responsible for a quarter of all trauma-related deaths. In such cases, pneumothorax is the most common thoracic injury, affecting 30 to 40% of patients with thoracic trauma. This injury occurs twice as often in closed traumas as in penetrating traumas. However, post-traumatic pulmonary pneumatocele is a very rare condition that occurs mostly in children and young adults. It's often a sequelae of acute pneumonia or barotrauma resulting from alveolar hyperpressure in the context of closed glottis trauma.

Recognizing these injuries quickly can save lives, whether the patient is outside or in a modern intensive care unit.

The reported case is an 8-year-old female child with no medical history, no delayed growth or development, who was involved in a public road accident with a thoracic impact. She presented with hemoptysis and chest pain, and a thoracic CT scan revealed bilateral pulmonary parenchymal contusions predominantly on the right, with post-traumatic pneumatoceles on the right side and a

*Corresponding author: E-mail: ghiz.jaabouti@gmail.com;

right pneumothorax blade, with good progress under surveillance, oxygen therapy, and prophylactic antibiotic treatment.

Keywords: *Pneumothorax; pneumatocele; pulmonary contusion; pulmonary laceration.*

1. INTRODUCTION

Blunt thoracic trauma usually occurs as part of polytrauma resulting from a road accident, and thoraco-pulmonary injuries are a major cause of trauma-related deaths, responsible for 25% of all post-traumatic fatalities. The accumulation of air in the pleural cavity (pneumothorax) is the most common potentially life-threatening injury in cases of blunt thoracic trauma [1].

The correct diagnosis of post-traumatic injuries relies on a comprehensive understanding of the various clinical and radiological manifestations [2]. While the low sensitivity and specificity of chest radiography compared to CT scan are well known, a chest X-ray in dorsal decubitus position is still systematically performed upon patient admission to urgently identify any pleural or air effusion that requires drainage.

2. PRESENTATION OF CASE

The patient is an 8-year-old female child, with no consanguinity or significant medical history, who was the victim of a road traffic accident with thoracic impact (pedestrian hit by a vehicle).

The clinical examination revealed a conscious and well-oriented child, afebrile, with normal conjunctivas, tachypneic at 52 cycles per minute, tachycardic at 122 beats per minute, and a saturation of 91% on room air, with thoracic asymmetry due to right hemothorax distension, decreased right thoracic expansion, decreased transmission of vocal vibrations and vesicular murmurs on the same side, and tympany on percussion, while the rest of the examination was unremarkable.

The chest X-ray showed interstitial syndrome predominantly on the right side [Fig. 1], while the thoracic CT scan revealed bilateral pulmonary parenchymal contusions predominantly on the right side, with post-traumatic pneumatoceles on the right side and a right pneumothorax blade [Fig. 2].

The cerebral, thoracic, and abdomino-pelvic scan did not find any other lesions.

The patient was put on oxygen therapy with preventive antibiotic treatment to avoid infection

(amoxicillin protected for 10 days). After 72 hours of hospitalization, the patient's condition improved. A follow-up chest x-ray [Fig. 3] and CT scan [Fig. 4] conducted one month after the accident showed radiological improvement with the dissipation of lung lesions.

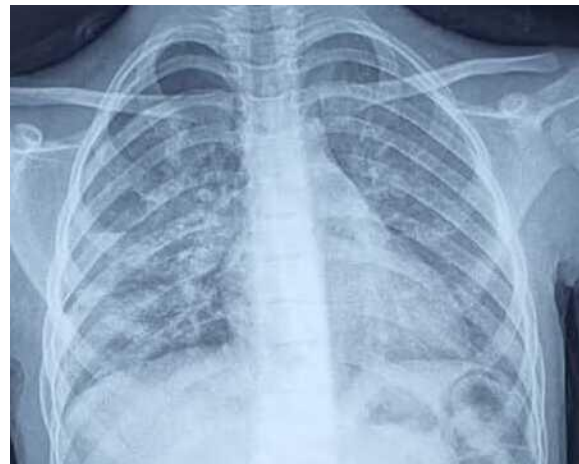


Fig. 1. The chest X-ray showed interstitial syndrome predominantly on the right side

3. DISCUSSION

Most thoracic traumas are related to road accidents. These injuries are closed in 90% of cases and are mainly related to deceleration forces during impact [3]. There is no correlation between the severity of parietal and visceral injuries, age plays a special role in the transmission of forces after trauma, the thoracic skeleton is flexible and deformable in children and young adults, so rib fractures are less frequent, with a higher frequency of associated visceral injuries [4]. On the other hand, in elderly people, rib fractures are frequent and absorb some of the energy of the trauma.

A chest X-ray in the supine position remains a routine procedure upon admission of the patient to detect any urgent need for draining air or pleural effusion. Thoracic computed tomography is indicated for a stable or stabilized patient as 30 to 50% of small pneumothorax in traumatized patients are missed on a frontal radiographic image, and it is by far the most sensitive technique for detecting small volume pneumothorax.

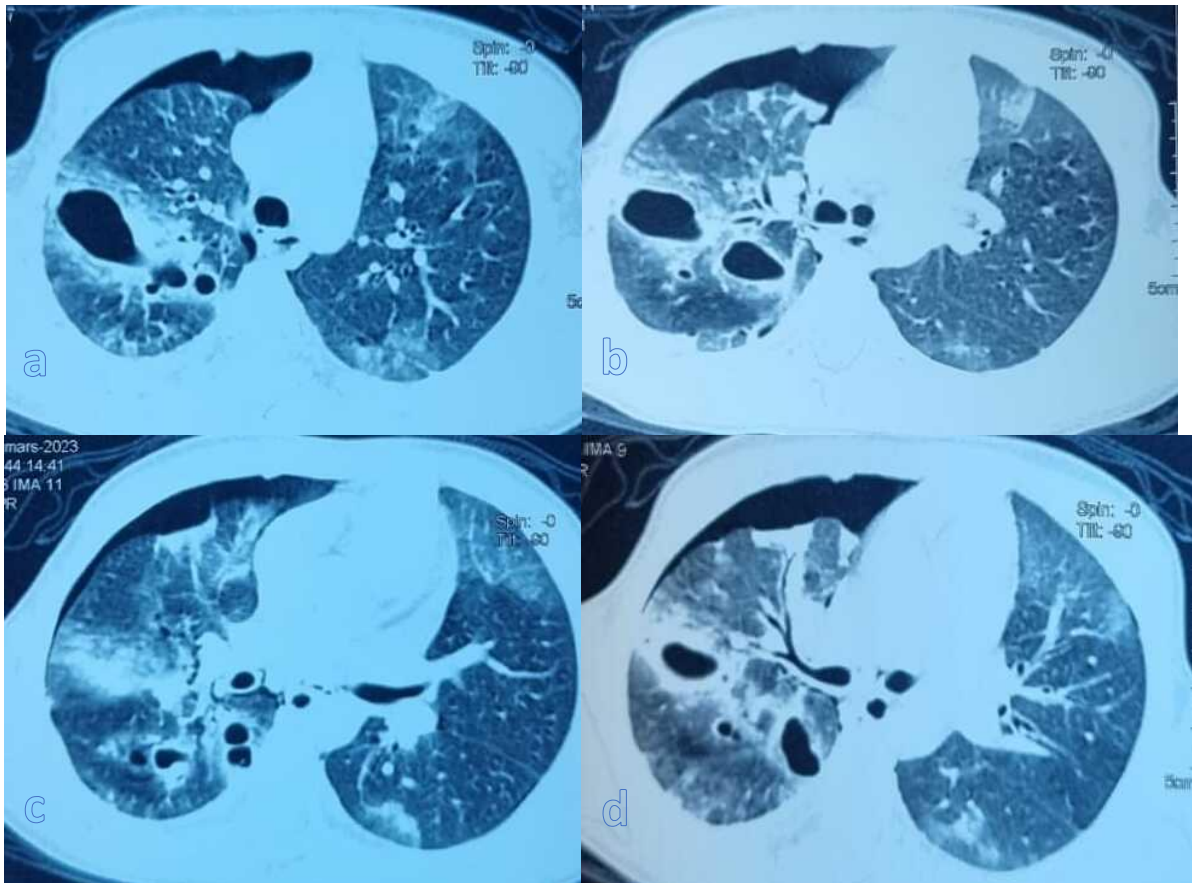


Fig. 2. (a,b,c,d). The thoracic CT scan revealed bilateral pulmonary parenchymal contusions predominantly on the right side, with post-traumatic pneumatoceles on the right side and a right small volume pneumothorax

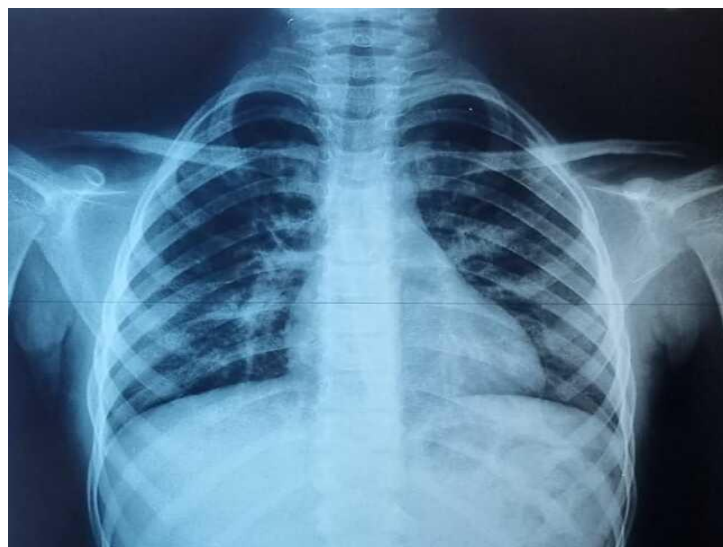

Fig. 3. The chest X-ray conducted one month after the accident showed radiological improvement

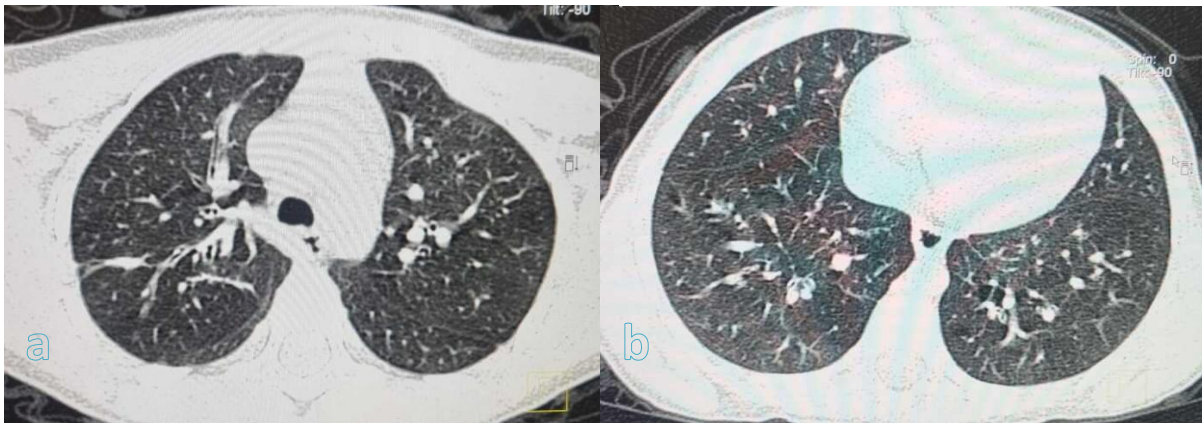


Fig. 4. (a,b). The chest CT scan performed one month after the accident showing the disappearance of pneumothorax and pneumatoceles

After thoracic trauma, several parenchymal lesions are possible, ranging from contusion, pulmonary laceration, pneumothorax or post-traumatic pneumatocele.

A pneumothorax occurs in 30 to 40% of patients with thoracic trauma. The clinical spectrum of pneumothorax varies from asymptomatic to life-threatening tension pneumothorax [5]. According to Advanced Trauma Life Support (ATLS) guidelines, all traumatic pneumothoraces should be treated with thoracostomy tube insertion as tension pneumothorax may develop [6]. In stable patients, conservative management may be safe and effective for a small pneumothorax (less than 15% of the lung field or less than 2.5 cm in size on chest radiography) [7-8]. They resolve by resorption at a rate of 1.25% per day. The rate can be multiplied by four with additional oxygen. In the case presented, the patient had a progressive resolution of the lesions under oxygen therapy.

Hemorrhagic pulmonary contusions are the most common lung injuries in closed trauma. They are present in 17 to 70% of patients with severe trauma and are a major factor in morbidity and mortality in thoracic trauma. The incidence of mortality ranges from 14 to 40%, depending on the severity of the injury and the presence of associated injuries. Clinical signs are variable, sometimes minimal, with classic initial underestimation of the injury. Abnormalities appear from 4 to 6 hours after trauma in over 70% of cases, and always within 24 hours. The rupture or damage of small vessels and the alveolo-capillary membrane leads to extravasation of blood and edema in the interstitium and alveolar spaces. The extent of

parenchymal lesions depends on the severity of the trauma. The resolution of simple contusions is rapid, greater than 72 hours in most cases, with restoration after 1-2 weeks. The absence of progressive regression after 7-8 days, or even worsening of the lesion, should suggest co-associated pathology such as infection, pulmonary edema or acute respiratory distress syndrome.

The presence of air or air-fluid cavities within the pulmonary parenchyma indicates a lung laceration. Lung lacerations are a consequence of more severe closed trauma. They result from a tear and can be caused by pleural or pulmonary perforation, rib fractures, or deceleration. They are usually associated with hemoptysis and hemothorax. Often associated with pulmonary contusions, they are often not recognized in initial radiographs due to peri-lesional bleeding. Lung lacerations are generally benign and resolve within 3-5 weeks. However, in case of mechanical ventilation, a post-traumatic pneumatocele can quickly become larger and persist for months. A direct connection of the laceration with a bronchus or pleura determines a bronchopleural fistula with a pneumothorax or hemothorax.

Post-traumatic pneumatocele (TP) is a rare condition in children and young adults that occurs a few days after a thoracic trauma, mainly due to vehicle collisions and falls. The theory of a two-stage injury is widely accepted to explain the underlying pathophysiological processes: [9] an explosive compressive force that tears the lung parenchyma [10], followed by a decompressive force on the soft thoracic wall that generates negative pressure, which lacerates the lung, and

after trapping air and/or blood, the lungs retract. Clinical manifestations are subtle or nonspecific, including chest pain, cough, hemoptysis, and dyspnea, and in rare cases, irritability and mental changes. Chest X-ray may show a pseudo-cystic image, single or multiple, located in an area of alveolar consolidation related to pulmonary contusion. The presence of other traumatic lesions (rib fractures, hemothorax, and pneumothorax) helps to orient the diagnosis. Computed tomography remains the reference examination for the detection of these lung lacerations and the evaluation of the extension of the lesion (bones, parenchyma, and cardio-mediastinal structures). This type of injury is often classified as "complicated TP" and "simple TP" depending on the presence or absence of blood inside the cavity [10]. Hemo-pneumatocele is characterized by oval hydro-air lesions with thick walls, confluent, surrounded by areas of ground-glass opacity (intra-alveolar bleeding) due to hemorrhagic lung lacerations.

Conservative treatment is usually recommended. Initial surgical management is also suggested for significant or complicated pneumatoceles to improve recovery after the accident and minimize complications [11-12].

The evolution of pneumatoceles is generally favorable with symptomatic treatment between four and twelve weeks, with a return to the previous parenchymal state. Simple radiological monitoring is sufficient in the absence of complications, which are dominated by superinfection. Systematic antibiotic prophylaxis has been discussed [13] but appears ineffective. Treatment with CT-guided drainage is indicated in the case of a single infected pseudocyst, while surgical excision should be considered if the pseudocysts are multiple or non-drainable.

The reported case is a child who presented with right unilateral pneumatoceles located in areas of alveolar consolidation related to pulmonary contusions, which were complicated by a low-volume pneumothorax on the same side, without associated fractures, following a road traffic accident. Symptomatic treatment and oxygen therapy were administered for four weeks with good clinical outcome.

4. CONCLUSION

Thoracic trauma accounts for approximately 25% of post-traumatic deaths, with many thoracic

injuries causing death within the first few minutes or hours after trauma. However, many of these injuries can be treated at the patient's bedside with definitive or temporary measures that do not require advanced surgical training. The CT management of thoracic trauma is part of a broader approach to polytrauma. A technical and interpretive rigor ensures a comprehensive study, preventing potentially serious injuries from being overlooked in this context.

Understanding the diagnostic assumptions of various possible lung lesions is essential in assessing patients with chest trauma, as accurate diagnosis can help guide appropriate treatment and improve outcomes.

CONSENT

As per international standard, parental written consent has been collected and preserved by the author(s).

ETHICAL APPROVAL

As per international standard or university standard written ethical approval has been collected and preserved by the author(s).

COMPETING INTERESTS

Authors have declared that no competing interests exist.

REFERENCES

1. Wilson H, Ellsmere J, Tallon J, Kirkpatrick A. Occult pneumothorax in the blunt trauma patient: Tube thoracostomy or observation, *Injury*. 2009;40:928-931.
2. Zinck SE, Primack SL. Radiographic and CT findings in blunt chest trauma. *J Thorac Imaging*. 2000;15:87-96.
3. Groskin SA. Selected topics in Chest trauma. *Radiology*. 1992;183: 605-17.
4. Balci AE, Kazez A, Eren S, Ayan E, Ozalp K, Eren MN. Blunt thoracic trauma in children: review of 137 cases. *Eur J Cardiothorac Surg*. 2004;26:387-92.
5. Papagiannis G, Lazaridis, Zarogoulidis K, Papaiwannou A, Karavergou A, Lampaki S, Baka S, Mpoukovinas I, Karavasilis V, Kioumis I, Pitsiou G, Katsikogiannis N, Tsakiridis K, Rapti A, Trakada G, Karapantzou I, Karapantzou C, Zissimopoulos A, Zarogoulidis P.

- Pneumothorax: An up to date introduction, Ann. Transl. Med. 2015;3(4):53.
6. American College of Surgeons Committee on Trauma, ATLS Advanced Trauma Life Support Program for Doctors American College of Surgeons, 9th Ed., American College of Surgeons, Chicago, IL; 2012.
 7. Johnson G. Traumatic pneumothorax: Is a chest drain always necessary? J. Accid. Emerg. Med. 1996;13:173–174.
 8. Symington L, McGugan E. Towards evidence based emergency medicine: Best BETs from the Manchester Royal Infirmary. Bet 1: Is a chest drain necessary in stable patients with traumatic pneumothorax? Emerg. Med. J. 2008;25: 439–440.
 9. Kato R, Horinouchi H, Maenaka Y. Traumatic pulmonary pseudocyst. Report of twelve cases. J. Thorac. Cardiovasc. Surg. 1989;97(2):309–312.
 10. Chon S-H, Lee CB, Kim H, et al. Diagnosis and prognosis of traumatic pulmonary pseudocysts: A review of 12 cases. Eur. J. Cardiothorac. Surg. 2006;29(5):819–823.
 11. Van Hoorebeke E, Jorens PG, Wojciechowski M, et al. An unusual case of traumatic pneumatocele in a nine-year-old girl: A bronchial tear with clear bronchial laceration. Pediatr. Pulmonol. 2009;44:826–828.
 12. Kaira K, Ishizuka T, Yanagitani N, et al. Pulmonary traumatic pneumatocele and hematoma. Jpn. J. Radiol. 2009;27:100–102.
 13. Armstrong LB, Mooney DP. Pneumatoceles in pediatric blunt trauma: common and benign. J. Pediatr. Surg. 2018;53(7): 1310–1312.

© 2023 Jaabouti et al.; This is an Open Access article distributed under the terms of the Creative Commons Attribution License (<http://creativecommons.org/licenses/by/4.0>), which permits unrestricted use, distribution, and reproduction in any medium, provided the original work is properly cited.

Peer-review history:

The peer review history for this paper can be accessed here:
<https://www.sdiarticle5.com/review-history/99116>