



Advanced Physical Rehabilitation in Hairline Coccyx Fracture: A Case Report

Shrushti Jachak^{1*} and Snehal Samal¹

¹*Department of Neuro Physiotherapy, Ravi Nair Physiotherapy College, Datta Meghe Institute of Medical Sciences, Wardha, Maharashtra, India.*

Authors' contributions

This work was carried out in collaboration between both authors. Both authors read and approved the final manuscript.

Article Information

DOI: 10.9734/JPRI/2021/v33i37A32002

Editor(s):

(1) Dr. Giuseppe Murdaca, University of Genoa, Italy.

Reviewers:

(1) Jamal Ahmad Saleem Alshorman, Huazhong University of Science and Technology, Jordan.

(2) Benhmida Saida, University of Tunis El Manar, Tunisia.

Complete Peer review History: <https://www.sdiarticle4.com/review-history/71139>

Case Report

Received 10 May 2021

Accepted 14 July 2021

Published 15 July 2021

ABSTRACT

Background: The fracturing of Coccyx is an injury normally caused by trauma. A fall on the buttocks can cause a coccyx fracture that may go radiographically unnoticed. There is substantial discomfort in the patient that can persist for months. Coccygectomy is suggested in cases that, after more than 2 months of conservative treatment, demonstrate coccydynia. There is little evidence available on the feasibility of this technique, though, and it is considered to have a high complication rate. As such, it requires other treatment techniques. Here, in order to effectively minimize coccydynia in a coccyx fracture patient, we report our experience using another conservative treatment option. The care consists largely of resting, physiotherapy and analgesics.

Presenting Symptoms and Diagnosis: : A 21-year-old girl had increased pain i.e. coccydynia after a traffic accident (RTA) induced by coccyx fracture. She visited physiotherapy department with complaints of pain in coccyx area, tenderness, difficulty in mobility (pain while standing from sitting position) and difficulty in performing activities of daily living (ADL). Patient gives history of road traffic accident 2 months ago, a autorickshaw dashed the patient from behind. She went to orthopedic department where X-ray was performed and she diagnosed with hairline coccyx fracture. On inspection, patient was in pain, her NPRS score was 8. Her pain was aggravated by movements and relieved at rest. Patient came with slight stooping posture. On palpation we did found that the swelling and tenderness was present with tightness. Whereas on musculoskeletal

*Corresponding author: E-mail: shrushtijachak@gmail.com;

assessment, we found that there was decreased range of motion, hypomobile joints, increased tone and muscle spasm.

Therapeutic Intervention and Outcomes: Patient was on medical treatment and bed-rest, treated with the analgesic and use of ring cushion was advised. She was also advised to reduce the weight bearing on buttocks. Cross-strapping of buttocks was done. After the completion of bed-rest, her condition was improved but she was having pain and could not perform squatting activities and other activities of daily living. Physiotherapy treatment was planned for the same.

Conclusion: Timely physiotherapy treatment is quite helpful to perform her everyday activities independently. This case study reveals the patient with hairline coccyx fracture experience full recovery after conservation management.

Keywords: Coccyx fracture; physical rehabilitation; coccyx injuries; coccydynia; tailbone.

1. INTRODUCTION

The spine's terminal section is the coccyx. Owing to the similarities in appearance as the latter is seen from the side, The name coccyx derives from the Greek word for cuckoo bird's beak [1]. The coccyx is a triangular bone consisting of 3 to 5 parts fused together, the highest of which, is articulated with the lowest sacral segment. Furthermore, primitive articular processes called the coccygeal cornua that articulate with the sacral cornua are contained in the first coccygeal section. This first section is inserted into the lower portion of the filum terminale, also known as the coccygeal ligament. The muscle of the levatorani and the sacrococcygeal ligament border the coccyx anteriorly. The lateral margins, going from anterior to posterior, act as insertion sites for the coccygeal muscles, sacrospinal ligament, sacrotuberous ligament, and muscle gluteus maximus fibres. Inferiorly, the muscle tendon of the iliococcygeus is inserted at the top of the coccyx.

Exact prevalence of coccyx fracture is not known but the study states that Coccyx fracture was diagnosed in a total of 238,906 cases, with an annual estimate of 26,545 patients. 1:2.6 was the male to female ratio. The average occurrence of coccyx fracture in 2018 was 119.75/100,000 individuals; in males, 33.44/100,000 and in females, 86.30/100,000. The occurrence rate was highest in males at puberty (age 10-14) and in females at menopause (age 50-54). The incident in winter followed by summer was frequent. The frequency of coccyx fracture was negatively associated with winter temperature (Pearson correlation factor=-0.67, $P<0.01$) while summer temperature (Pearson correlation coefficient=0.66, $P<0.01$) was positively correlated. Old age, female gender, late year, summer and winter, low temperature and high volume of precipitation emerged as risk factors

for coccyx fracturing in the generalized linear model [2].

The coccyx has many essential roles, despite its tiny size. In addition to being the insertion site for numerous muscles, ligaments, and tendons, it also acts as one leg of the tripod, along with the ischial tuberosities, providing a person in the seated position with weight-bearing support [3].

Causes of coccyx fracture can vary widely, but are most often limited to dropping into the seated position or giving birth. Lack of decreased muscle mass, old age, osteoporosis and being of female sex (because of the larger pelvis normally seen in women) are risk factors for coccyx fractures. A fall on the buttocks can cause a coccyx fracture that may go radiographically unnoticed. Fall in the sitting position can be stated as the route cause for the coccyx fracture. There is substantial discomfort in the patient that can persist for months.

Signs of Coccyx fracturing provide pain that rises in magnitude when a chair is sitting or standing up or when bowel movement is encountered. Discomfort increases as the weight is applied on the buttock or on the fractured bone. Provoked tailbone pain and swelling in the vicinity of the tailbone.

2. PATIENTS INFORMATION

A 21-year-old female student with right hand dominance visited the physiotherapy department with complaints of pain in coccyx area, tenderness, difficulty in mobility (pain while standing from sitting position and getting up from sitting position) and difficulty in performing activities of daily living (ADL). Patient could not sit for prolonged duration, long sitting position was difficult for patient. Patient gives history of road traffic accident 2 months ago, a

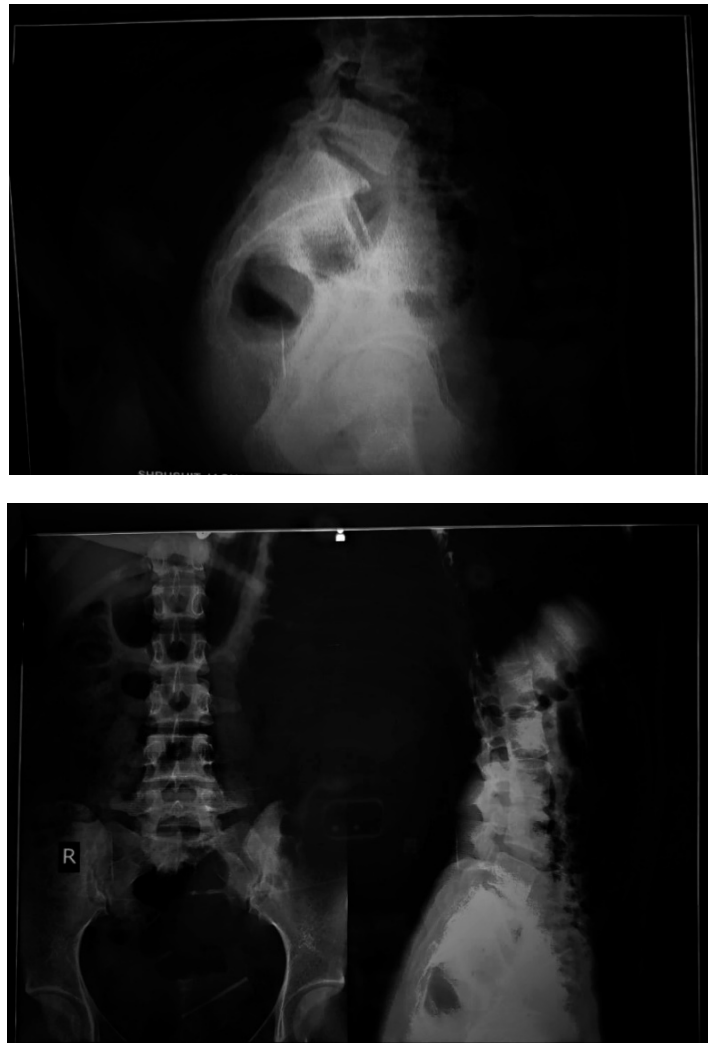


Fig. 1. X-RAY images

autorickshaw dashed the patient from behind. She went to orthopedic department where X-ray was performed and she diagnosed with hairline coccyx fracture.

3. CLINICAL FINDINGS

On inspection, patient was in pain, her NPRS score was 8. Her pain was aggravated by

movements and relieved at rest. Patient came with slight stooping posture. On palpation we did find that the swelling and tenderness was present. Whereas on musculoskeletal assessment, we found that there was decreased range of motion, hypomobile joints, increased tone and muscle spasm.

Table 1. MMT & ROM CHART

Joint	Muscles	Grade
Lumbar	Extensors	Not
Hip	Flexor	3
	Extensor	2
	Adductors	2
	Abductors	2

Table 2. Clinical findings

Joint			
Lumbar	Flexion	50	
	Extension	NOT	
		Rt	Lt
Hip	Flexion	30	35
	Extension	Not	Not
	Abduction	30	35
	Adduction	25	25
	Lateral Rotation	15	20
	Medial Rotation	33	30

4. TIMELINE

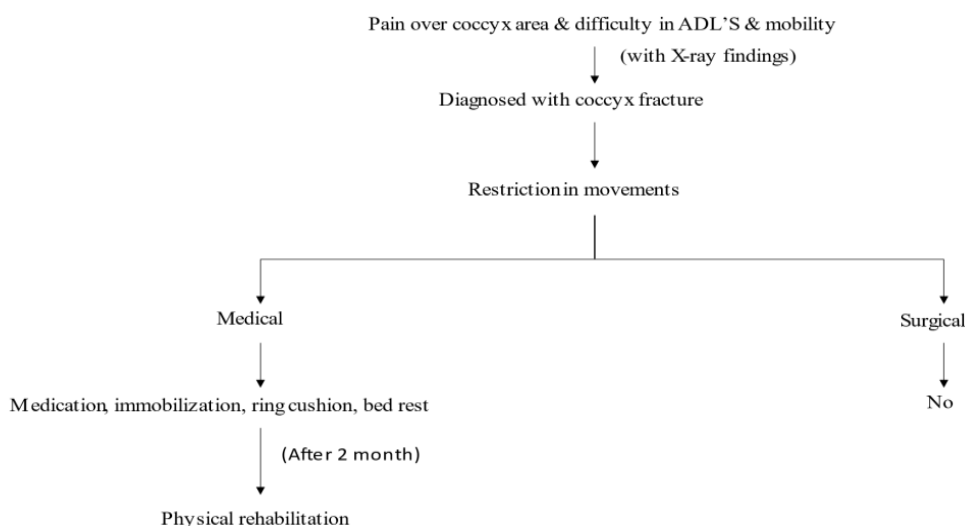


Fig. 2. Schematic diagram

5. MANAGEMENT

Patient was on medical treatment and bed-rest. She was treated with the analgesic and use of ring cushion was advised to her. She was also advised to reduce the weight bearing on buttocks, sitting on alternate buttocks was advised. Cross-strapping of buttocks was done. After the completion of bed-rest, her condition was improved but she was having pain and could not perform squatting activities and other activities of daily living (ADL'S) properly. Her pain use to aggravate when she sits on both the buttocks. Patient was advised physiotherapy after fracture healing and she visited physiotherapy department late by one week. Patient came with the complains of pain (coccydynia, which was fracture induced), difficulty in activities of daily living (ADL'S).

5.1 Week 1

Application of hot pack for 10-15 min duration at start of treatment session every time as that helps to reduce the pain, swelling and relaxation of muscles. Application of ultrasound (phonophoresis) was done. Range of muscle exercises were started, active assisted exercises were given with 10 repetitions. To maintain the ROM of adjacent joints active movements of knee and ankle joint were given. Sitz bath was advised to the patient as it also helps in muscle relaxation and pain reduction. All the ergonomic advises were given to the patient which can reduce the weight on the buttocks and ring cushion use.

5.2 Week 2

Application of hot pack at the start of treatment was given, as it reduces the pain and promote

relaxation of muscle and swelling. Sitz bath was continued as it promotes relaxation of the glutes muscles. Use of ring cushion was continued. As the active assisted exercises of hip joint were given in the previous week the range of motion hip joint was increased to 50 degrees, patient was able to perform the movement till 50 degrees later from 50-75 degrees patient needed assistance. PNF for lower limb was given. As the active range of motion of knee and ankle joints were presents and exercises were given for the maintenance of range of motion in the previous week, strengthening exercises of quadriceps and hamstrings were started. Isometrics of glutes.

5.3 Week 3

Thermotherapy discontinued as the pain and swelling were subsequently reduced. Range of motion exercises continued. Hip flexion was increased upto 75-80 degrees but could not do more, so piriformis tightness was assessed and patient had piriformis tightness. As the pain was reduced all the range of motions of the hip joint were possible and the strengthening of knee was started and active hip extension was possible. Piriformis stretching was given to reduce the piriformis tightness in the patient.

5.4 Week 4

Hip active range of motion was possible and as the pain and spasm subsided, lumbar spine motions were also possible so strengthening was started at this stage for reducing difficulty in daily living. Follow up was taken weekly once for one month.

6. FOLLOW-UP AND OUTCOME

Follow up was taken weekly once for one month.

There was significant reduction of pain on NPRS scale. The post treatment NPRS score was 3. Patient was able to perform her everyday activities independently.

Table 3. Follow up outcome and grade

Joint	Muscles	Grade
Lumbar	Extensors	4
Hip	Flexor	5
	Extensor	4
	Adductors	4
	Abductors	5

Table 4. Post treatment NPRS score

Joint				
Lumbar	Flexion	65		
	Extension	20		
		Rt	Lt	
Hip	Flexion	85	90	
	Extension	20	20	
	Abduction	40	40	
	Adduction	30	30	
	Lateral rotation	35	35	
	Medial rotation	40	40	

7. DISCUSSION

In this case, patients with symptoms of pain, spasm, decreased range of motion, diminished strength and trouble with everyday life tasks (ADL'S) was presented to the physiotherapy unit. A plan of treatment was created following clinical assessment, which included sitz bath and phonophoresis. Sitz bath and phonophoresis both help in reduction of pain [4]. As sitz bath provide heat which produces muscle relaxation and increase in blood circulation which causes flow of increases metabolites and hence reduces pain also. Phonophoresis is the method of introducing drug through ultrasound, drugs used are generally analgesics(ointments), which reduces the pain. Thermal effects of ultrasound accelerate healing as well as reduces muscle spasm. Ultrasound can provide temporary relief, and so we continued with the other interventions [5]. Range of motion exercises were started to advance passively towards free exercises [6]. Improving range of motion is necessary to make patient functionally independent. Range of motion exercises should started from passive exercises progressing to the resisted exercises.

Thermotherapy is useful in the patients with pain [7] as it causes physiological changes in the body by increasing the blood flow and draining out the toxins. It causes short term relief from pain but is helpful for the patient. Strengthening and resistive exercises can improve patients condition remarkably in fracture cases, as it reduces difficulty in activities of livin [8]. Weight bearing exercises also promotes proprioception [9]. Physical therapy or conservation treatment helps in reducing muscle spasms and musculoskeletal conditions [10-13]. Rehabilitation after musculoskeletal injuries is must to perform day-to-day activities independently [14-17].

8. CONCLUSION

The patient has been provided with comprehensive plan that helped her by pain reduction (coccydynia), reducing muscle spasm, increasing the range of motion (ROM) and strength. Significant change in the patient was seen after the treatment. Patient was able to perform her everyday activities independently. In summary, this case study reveals the patient with hairline coccyx fracture experience full recovery after conservation management.

ETHICAL APPROVAL & CONSENT

As per international standard or university standard guideline patients consent and ethical approval has been collected and preserved by the authors.

COMPETING INTERESTS

Authors have declared that no competing interests exist.

REFERENCES

1. Sarmast AH, Kirmani AR, Bhat AR. Coccygectomy for Coccygodynia: A Single Center Experience Over 5 Years. *Asian J Neurosurg.* 2018;13(2):277–82.
2. Won H, Moon S-Y, Park JH, Kim J-K, Kim HS, Baek S-H, et al. Epidemiology and risk factors of coccyx fracture: A study using national claim database in South Korea. *Injury.* 2020 Oct 1;51(10):2278–82.
3. Lirette LS, Chaiban G, Tolba R, Eissa H. Coccydynia: an overview of the anatomy, etiology, and treatment of coccyx pain. *Ochsner J.* 2014;14(1):84–7.
4. Mohanty PP, Pattnaik M. Effect of stretching of piriformis and iliopsoas in coccydynia. *J Bodyw Mov Ther.* 2017 Jul;21(3):743–6.
5. Fogel GR, Cunningham PYI, Esses SI. Coccygodynia: Evaluation and Management. *JAAOS - J Am Acad Orthop Surg.* 2004 Feb;12(1):49–54.
6. Jr BFP, Federico R. Tewes. What attorneys should understand about Medicare set-aside allocations: How Medicare Set-Aside Allocation Is Going to Be Used to Accelerate Settlement Claims in Catastrophic Personal Injury Cases. *Clinical Medicine and Medical Research.* 2021; 2(1):61-64.
7. Shah PA, Nemade SV, Naqvi WM. Advance Physiotherapeutic Rehabilitation Approach for Hand Functions in a Giant Cell Tumour Patient- A Case Report on Palliative Physiotherapy. *J Evol Med Dent Sci.* 2020 May 25;9(21):1675–8. DOI:https://doi.org/10.52845/CMMR/2021v1i1a1
8. Malanga GA, Yan N, Stark J. Mechanisms and efficacy of heat and cold therapies for musculoskeletal injury. *Postgrad Med.* 2015 Jan 2;127(1):57–65.
9. Darda PP, Mishra SA, Naqvi WM, Sahu A. Rehabilitation of compound elbow fracture, brachial artery injury with median and ulnar nerve neuropathy: A case report. 2020;8.
10. Daniel V, Daniel K. Diabetic neuropathy: new perspectives on early diagnosis and treatments. *Journal of Current Diabetes Reports.* 2020;1(1):12–14. DOI:https://doi.org/10.52845/JCDDR/2020v1i1a3
11. Dhankar. A case of fracture shaft femur in a patient with transtibial amputation [Internet]. [cited 2021 Feb 23]. Available: <http://www.journaldmims.com/article.asp?issn=0974-3901;year=2019;volume=14;issue=4;spage=394;epage=396;aulast=Dhankar>
12. Jachak S, Phansopkar P, M WN. Impact of COVID-19 in India, a disastrous pandemic outbreak. *Int J Res Pharm Sci.* 2020 Aug 6;11(SPL1):399–402.
13. Jachak SP, Phansopkar PA, Naqvi WM, Kumar K. Great Awakening--Telerehabilitation in Physiotherapy during Pandemic and Impact of COVID-19. *J Evol Med Dent Sci.* 2020 Nov 9;9(45):3387–94.
14. Daniel V, Daniel K. Perception of nurses' work in psychiatric clinic. *Clinical Medicine Insights.* 2020;1(1):27-33. DOI:https://doi.org/10.52845/CMI/2020v1i1a5
15. Khanam N, Wagh V, Gaidhane AM, Quazi SZ. Assessment of work-related musculoskeletal morbidity, perceived causes and preventive activities practiced to reduce morbidity among brick field workers. *Indian Journal of Community Health.* 2019;31(2):213–19.
16. James SL, Castle CD, Dingels ZV, Fox JT, Hamilton EB, Liu Z, Roberts NLS, et al. Global injury morbidity and mortality from 1990 to 2017: Results from the Global Burden of Disease Study 2017." *Injury Prevention.* 2020;26(1): 196–114.

- DOI:<https://doi.org/10.1136/injuryprev-2019-043494>
17. Daniel V, Daniel K. Exercises training program: It's Effect on Muscle strength and Activity of daily living among elderly people. Nursing and Midwifery. 2020; 1(01):19-23.
DOI:<https://doi.org/10.52845/NM/2020v1i1a5>

© 2021 Jachak and Samal; This is an Open Access article distributed under the terms of the Creative Commons Attribution License (<http://creativecommons.org/licenses/by/4.0>), which permits unrestricted use, distribution, and reproduction in any medium, provided the original work is properly cited.

Peer-review history:
The peer review history for this paper can be accessed here:
<https://www.sdiarticle4.com/review-history/71139>