

Hepatic Metastasis in a Nigerian with Differentiated Thyroid Cancer- An Uncommon Presentation: Case Report

Olufunke Adeleye^{1*}, Aderemi Oluyemi², Muhammad Habeeb³, Adekunle Adeyomoye³ and Fatimah AbdulKareem³

¹Olabisi Onabanjo University Teaching Hospital, Sagamu, Ogun State, Nigeria.

²ReMay Consultancy and Medical Services, Opebi, Ikeja, Lagos State, Nigeria.

³Lagos University Teaching Hospital, Idi-Araba, Lagos, Nigeria.

Authors' contributions

This work was carried out in collaboration between all authors. Author OA evaluated the case, wrote the first draft of the manuscript with author AO. All authors read and approved the final manuscript.

Article Information

DOI: 10.9734/JCTI/2015/20790

Editor(s):

(1) Rafael Roesler, Cancer Research Laboratory, University Hospital Research Center, Federal University of Rio Grande do Sul, Brazil.

Reviewers:

(1) Pietro Giorgio Calò, University of Cagliari, Italy.

(2) Hildegard M. Schuller, University of Tennessee, USA.

(3) Tariq Namad, University of Cincinnati, USA.

Complete Peer review History: <http://sciencedomain.org/review-history/11818>

Case Study

Received 9th August 2015
Accepted 23rd September 2015
Published 13th October 2015

ABSTRACT

The papillary and follicular histological sub-types of thyroid cancer are referred to as differentiated thyroid cancers. When these tumors metastasize, they rarely do so to the liver. Hepatic metastasis is very uncommon in this group of cancers and has only been reported in a handful of cases. We present one such case in a Nigerian patient and note its unique presentation and with it, we highlight the need for careful attention to be paid to clinical and investigation findings when attempts are being made to arrive at a definitive diagnosis in cases of suspected primary liver cell cancers which are common in this part of the world.

Keywords: Follicular thyroid cancer; differentiated thyroid cancer; hepatic metastasis.

1. INTRODUCTION

Thyroid carcinomas constitute less than 1% of all human cancers. The annual incidence worldwide ranges from 0.5 to 10 cases per 100,000 populations with the median age at diagnosis being 45–50 years [1]. It is two to four times more frequent in women than men [1]. Papillary and follicular thyroid cancers, together, are referred to as differentiated thyroid cancer (DTC). Differentiated thyroid carcinomas are relatively rare despite common incidence of thyroid nodules [2]. DTC often run an indolent course and have a 10-year survival rate as high as 80–95% [1]. Distant metastases are seen in a minority of patients and the reported rates of occurrence range from 4 to 15% [3–7]. The common sites of distant metastasis are the lung and bone. [8]. Metastasis to other distant sites is relatively rare and involve the brain, breast, liver, muscle and skin. The presence of distant metastasis is the most significant poor prognostic factor for survival with only 50% metastatic patients surviving after 10 years [9]. Liver metastasis from DTC is quite unusual, with a reported frequency of 0.5% [10]. Metastatic liver involvement from DTC is nearly always multiple or diffuse and usually found along with other distant metastases including the lungs, bones and the brain [11]. DTC liver metastasis has a poor prognosis. Surgical resection of liver lesions has been reported to offer the best chance for prolonged survival [12]. What makes the case presented here an interesting one is the fact that thyroid cancer metastases to liver are rare, and this represents a novel documentation of same from our region of Africa.

2. CASE REPORT

A 56-year old Nigerian lady presented with complaints of a 6 month history of abdominal swelling and weight loss. She had felt malaise with a significant drop in appetite over the same period. Her past history was significant for a partial thyroidectomy which was carried out 7 years earlier on account of what was then thought to be a non-malignant thyroid mass.

Examination findings included non-tender hepatomegaly, with no obvious peripheral stigmata of chronic liver disease. She had a well healed scar of a previous thyroidectomy and there were palpable lymph nodes in the deep cervical lymph node group. The nodes were firm, immobile and none-tender. Investigations carried out revealed deranged thyroid function tests (elevated free T_3 , low free T_4 and Thyroid

Stimulating Hormone), markedly elevated alkaline phosphatase and gamma glutamyl transpeptidase (γ GT), with other liver function tests being normal. Screens for hepatitis B and C were negative.

A chest computed tomography (CT) scan showed suspected bilateral pulmonary metastatic lesions (Figure 1). An abdominal ultrasound (USS) and (CT) scan revealed a huge intrahepatic mass in segments 4a, 4b and 5 with lobulated margins and heterogeneous enhancement post contrast (Figure 2).

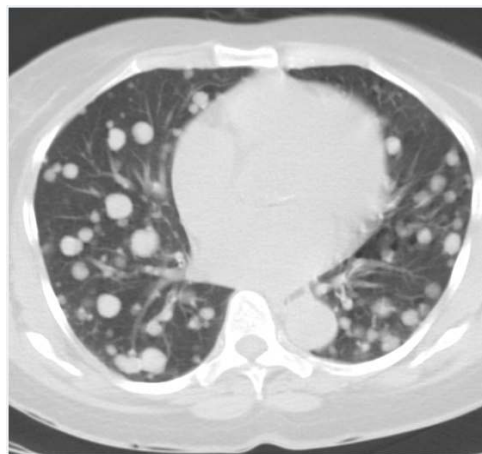

Figure 1. Computed tomography image of the thorax showing multiple “cannon ball” lesions of suspected lung metastasis

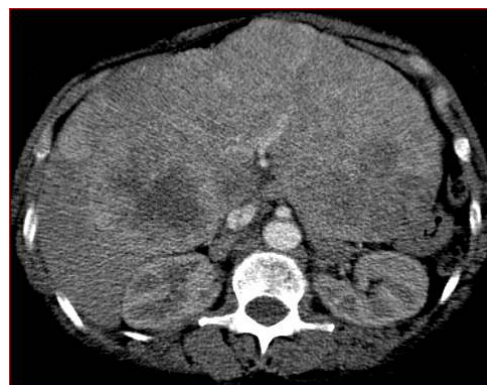

Figure 2. Computed tomography image of the abdomen showing a huge intra-hepatic mass in segments 4a, 4b and 5 with lobulated margins and heterogeneous enhancement post contrast

Normal α fetoprotein level and colonoscopy results were followed by a USS-guided biopsy of the liver mass which histology were reported as

sections containing thyroid and not hepatic tissue. It further revealed variously sized thyroid follicles lined by cuboidal cells (Figure 3). Thyroid Ultrasound scan showed the presence of hypervascular nodules in the thyroid and matted cervical nodes in the upper carotid sheath. A whole body scintigraphy revealed normal tracer bio-distribution in the thyroid gland with abnormal uptake in the lungs and liver indicative of multiple functioning metastases in these latter organs.

A diagnosis of distant (lungs and hepatic) metastasis from a thyroid cancer was made and the patient has since been referred for expert radio-oncologic assessment and management.

3. DISCUSSION

Liver metastasis from DTC is quite rare, with a reported frequency of 0.5% [10]. As of 2012, a review of literature by Hong-Jun Song et al. [11] reported that only ten cases have been documented in the literature. Three were males and seven females with an average age of about 63 years (range from 32 to 85 years). Histologically, the primary tumor was identified as papillary in four patients, follicular in five, and Hürthle cell thyroid cancer in one patient. Our patient presented herein, fits well the typical epidemiological descriptors as she is 56 years old. Unfortunately, the histology of the primary tumor of this patient is unknown as pathology was not carried out on the thyroid gland when it was removed 7 years ago. Hence, we cannot comment about the primary histological variant.

This is because transformation of histopathologic types may occur in liver metastases from DTC [11]. This phenomenon has been documented in two of the patients in the 2012 review where the primary tumors were follicular and papillary but their liver metastasis were a unique entity described as follicular variant of papillary thyroid carcinoma.

The indolent growth nature of DTC is reflected considering that metastasis occurred after 7 years of the primary thyroid mass been surgically excised. Similar occurrence has been reported in the literature in which a metastatic thyroid liver disease was detected 32 years after thyroidectomy was performed for a follicular thyroid tumor [13]. This underscores the need for a lifelong followup because of the long time risk of recurrence of the disease.

Metastatic liver involvement from DTC is nearly always multiple or diffuse and is usually found along with other distant metastases [11] as was in this index patient who had accompanying lung metastasis at presentation.

The patients seldom present with symptoms referable to the *de facto* liver involvement except when the masses were huge [11]. This was also mirrored in our report. The survival rate after liver metastases is poor; however, Song et al. [11] opines that this may not be attributable to the liver metastases alone as multiple other vital organs are concurrently involved by this time.

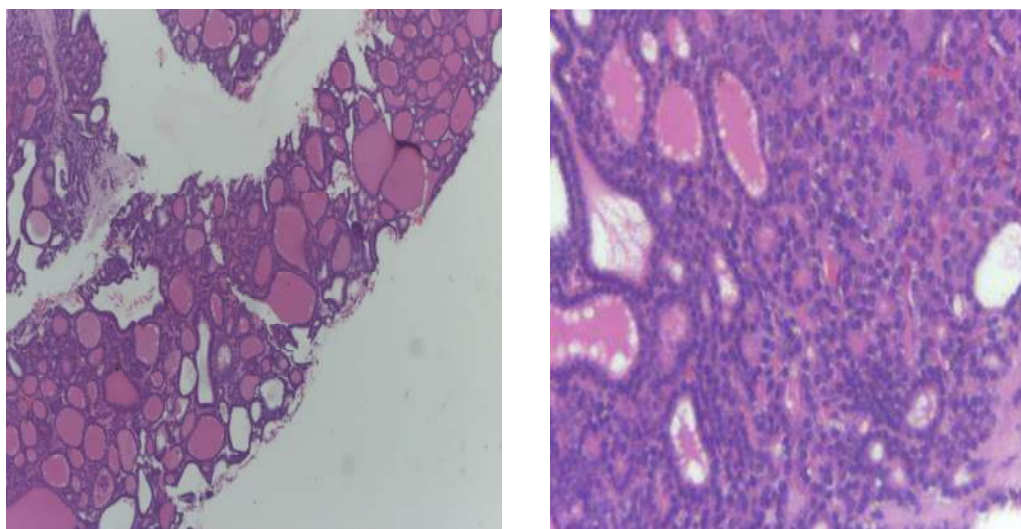


Figure 3. Photomicrographs of needle biopsy from liver mass showing tumor fragments consisting exclusively thyroid follicles lined by cuboidal epithelial cells with hyperchromatic nuclei (Left-H&E×100,Right×400)

4. CONCLUSION

The case report highlights the possibility of such rare occurrence of hepatic metastasis from DTC. To the best of our knowledge, this represents a novel documentation of this association from our environment. Because of the possible confusion with a primary liver cell carcinoma which is relatively common in our region of the world, the usefulness of histological diagnosis of doubtful intra-hepatic lesions is also highlighted.

CONSENT

All authors declare that written informed consent was obtained from the patient (or other approved parties) for publication of this case report and accompanying images.

ETHICAL APPROVAL

It is not applicable.

COMPETING INTERESTS

Authors have declared that no competing interests exist.

REFERENCES

1. Schlumberger MJ. Papillary and follicular thyroid carcinoma. *N Engl J Med.* 1998; 338:297–306.
2. Keeston Jones M. Management of papillary and follicular thyroid cancer. *J R Soc Med.* 2002;95(7):325–26.
3. Hoie J, Stenwig AE, Kullmann G, Lindegaard M. Distant metastases in papillary thyroid cancer. A review of 91 patients. *Cancer.* 1988;61:1–6.
4. Casara D, Rubello D, Saladini G, Masarotto G, Favero A, Girelli ME & Busnardo B. Different features of pulmonary metastases in differentiated thyroid cancer: Natural history and multivariate statistical analysis of prognostic variables. *J Nucl Med.* 1993; 34:1626–31.
5. Shaha AR, Shah JP, Loree TR. Differentiated thyroid cancer presenting initially with distant metastasis. *Am J Surgery.* 1997;174:474–76.
6. Clark JR, Lai P, Hall F, Borglund A, Eski S, Freeman JL. Variable predicting distant metastases in thyroid cancer. *Laryngoscope.* 2005;115:661–67.
7. Aggarwal V, Bhargav PR, Mishra A, Agarwal G. Clinico-pathological characteristics and long-term outcome in patients with distant metastases from differentiated thyroid carcinoma. *World J Surg.* 2007;31:246–47.
8. Mazzaferri EL, Massoll N. Management of papillary and follicular (differentiated) thyroid cancer: New paradigms using recombinant human thyrotropin. *Endocr-Relat Cancer.* 2002;9:227–47.
9. Elisei R, Molinaro E, Agate L, Bottici V, Masserini L, Ceccarelli C, et al. Are the clinical and pathological features of differentiated thyroid carcinoma really changed over the last 35 years? Study on 4187 patients from a single Italian institution to answer this question. *J Clin Endocrinol Metab.* 2010;95:1516–27.
10. Salvatori M, Perotti G, Rufini V, et al. Solitary liver metastasis from Hürthle cell thyroid cancer: A case report and review of the literature. *J Endocrinol Invest.* 2004; 27(1):52–6.
11. Song H-J, Xue YL, Qiu ZL, et al. Uncommon metastases from differentiated thyroid carcinoma. *Hell J Nucl Med.* 2012;15(3):233–240.
12. Niederle B, Roka R, Schemper M, Fritsch A, Weissel M, Ramach W. Surgical treatment of distant metastases in differentiated thyroid cancer: Indications and results. *Surgery.* 1986;100:1088–96.
13. Kouso H, Ikegami T, Ezaki T, Ishida T, Aimitsu S, Fujihara M, Mori M. Liver metastasis from thyroid carcinoma 32 years after resection of the primary tumor: Report of a case. *Surg Today.* 2005; 35(6):480-2.

© 2015 Adeleye et al.; This is an Open Access article distributed under the terms of the Creative Commons Attribution License (<http://creativecommons.org/licenses/by/4.0>), which permits unrestricted use, distribution, and reproduction in any medium, provided the original work is properly cited.

Peer-review history:

The peer review history for this paper can be accessed here:
<http://sciedomain.org/review-history/11818>