

Myofibroblastoma of Axillary Soft Tissue in a Child

Shubhangi V. Agale^{1*}, Bhushan M. Warpe¹, Geeta Kumari¹
and Arvind G. Valand¹

¹Department of Pathology, Grant Govt Medical College, Mumbai-400008, India.

Authors' contributions

This work was carried out in collaboration between all authors. Author SVA diagnosed the case, designed the study, wrote and rectified the manuscript draft to its perfection. Author BMW managed the literature searches and wrote the first draft of the manuscript with help of authors GK and AGV reviewed the manuscript. All authors have read and approved the final manuscript.

Article Information

DOI: 10.9734/JCTI/2015/20633

Editor(s):

(1) Nicole Riddle, Department of Pathology, The University of Texas Health Science Center (UTHSCSA), USA.

Reviewers:

- (1) Anonymous, Tzaneio General Hospital of Piraeus, Greece.
(2) Georgios Androutsopoulos, University of Patras, Rio, Greece.
(3) Anonymous, Tokyo School of Medicine Hachioji Medical Care Center, Japan.
(4) D. Agrawal, Hindu University Varanasi U.P, India.
Complete Peer review History: <http://sciencedomain.org/review-history/11382>

Case Study

Received 1st August 2015
Accepted 21st August 2015
Published 12th September 2015

ABSTRACT

Aims: Myofibroblastoma (MFB) is an unusual benign mesenchymal tumour which has neoplastic cells showing a variable myofibroblastic differentiation at morphologic, immunohistochemical and ultrastructural levels. MFB is commonly seen in adult population with age range of 36-67 years. This tumour is very rare in paediatric population with few reported cases below the age of 21 years. We report myofibroblastoma in a youngest female child which mimicked a malignant tumour.

Presentation of Case: A four-year-old female child with history of tender left axillary swelling since one year. The swelling was initially small and gradually increased to present 8 x 6 cm size. The lump was oval, firm to hard, mobile, tender with clear margins and smooth surface. MRI studies of the left shoulder and thorax revealed enhancing neoplastic mass in the left axilla inseparable from the subscapularis muscle measuring 8 x 5 x 6 cm. Grossly the tumour measured 8 x 5 x 6 cm, was well-circumscribed and partially encapsulated with solid, grayish-white to tan appearance. The overall features favoured the diagnosis of myofibroblastoma.

Discussion: Myofibroblastoma is a benign mesenchymal tumour commonly involving breast in

*Corresponding author: Email: shubhagale@hotmail.com;

elderly males. Extra-mammary location is very rare for this tumour with few reported cases. In English literature only six cases have been reported below 21 years of age and all were teenagers. The prior youngest reported case was in a nine-year-old girl with left groin swelling.

Conclusion: Extra-mammary myofibroblastoma is a rare entity and is uncommon in paediatric population below the age of five years.

Keywords: Benign mesenchymal tumour; myofibroblastoma (MFB); soft-tissue.

ABBREVIATIONS

MFB - Myofibroblastoma.

1. INTRODUCTION

Myofibroblastoma is a benign, prototypic tumour of the mammary stroma and was initially described as a typical tumour occurring in the breast of adult males [1-3]. MFB was first described in 1987 by Wargotz et al. [1,4] as a distinctive benign mesenchymal tumor of the breast. The tumour is comprised of spindle cells with a variable fibromyoblastic differentiation at morphologic, immunohistochemical and ultrastructural levels.

Extra-mammary location for this tumour is very rare. The extra-mammary sites are located mainly along the embryonic milk line [2,4,5,6].

Till date only 20 cases of extra-mammary MFB have been reported [4]. According to our knowledge, our case is the youngest reported 21st case of extra-mammary myofibroblastoma.

2. CASE PRESENTATION

A four-year-old female child with normal developmental milestones was brought by parents to Paediatric Surgery Unit with history of tender left axillary swelling since one year. The swelling was initially small and gradually increased to present 8 x 6 cm size. The lump was oval, firm to hard, mobile, tender with clear margins and smooth surface. The overlying skin was normal without any prominent veins or fixation to lump. There was no transmitted pulsation or bruit on auscultation. There was no palpable lymphadenopathy of cervical, supra-clavicular, axillary and internal mammary group of lymph nodes. The general and systemic examinations were unremarkable.

X-ray chest revealed it as a soft tissue tumor in left axilla measuring 8 x 5 x 6 cm (Fig.1a). MRI studies of the left shoulder and thorax revealed enhancing neoplastic mass in the left axilla

inseparable from the subscapularis muscle measuring 8 x 5 x 6 cm (Figs. 1b and 1c). The pectoralis major and pectoralis minor muscles were displaced peripherally. The axillary vessels and its divisions, the nerves of brachial plexus and ribs were not involved by the tumour.

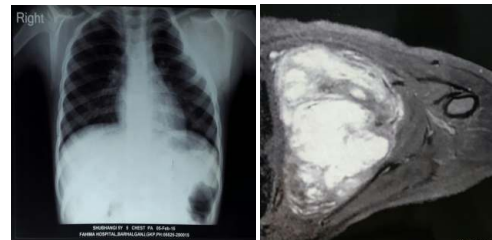

Fig. 1a

Fig. 1b

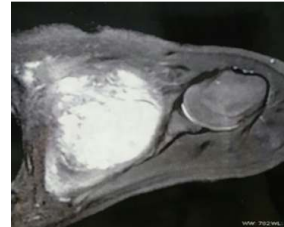


Fig. 1c

Fig. 1. A) 1a- X-ray chest revealed a soft tissue tumour in left axilla and both lungs are unremarkable; B) 1b & 1c- MRI studies of the left shoulder and thorax revealed enhancing neoplastic mass in the left axilla measuring 8 x 5 x 6 cm

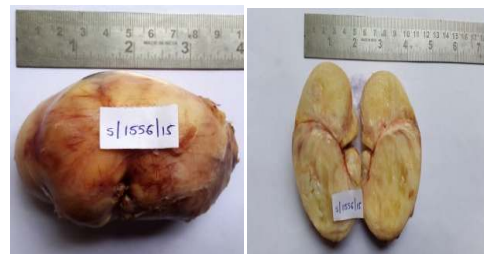

Fig. 2a

Fig. 2b

Fig. 2. A) 2a- Grossly well-circumscribed, partly encapsulated tumour measured 8 x 5 x 6 cm; B) 2b- Cut surface revealed solid, grayish-white to tan, firm tumor with myxoid areas without hemorrhage and necrosis

FNAC from the swelling was suggestive of spindle cell lesion. Intra-operatively the tumour was well-circumscribed without infiltration into the adjacent soft tissue. The excised specimen was sent for histopathology. Grossly the tumour measured 8 x 5 x 6 cm, weighed 400 grams and was well-circumscribed and partially encapsulated (Fig. 2a). The cut surface was solid, grayish-white to tan, firm with myxoid areas but no necrosis and haemorrhage (Fig. 2b).

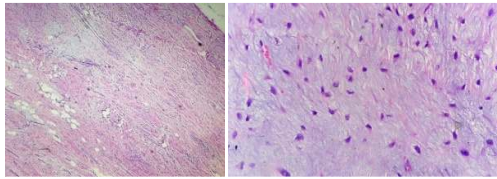


Fig. 3a

Fig. 3b

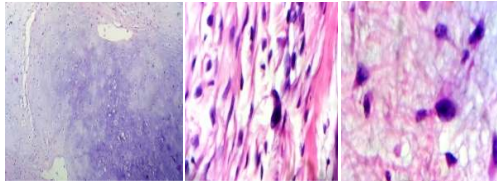


Fig. 3c

Fig. 3d

Fig. 3e

Fig. 3. A) 3a- Microphotograph showed an well-circumscribed, partly encapsulated, hypocellular, vaguely nodular myxoid tumour with foci of adipose tissue. No areas of hemorrhage and necrosis were seen. (H & E, x 40); B) 3b-Tumour cells were embedded in a myxoid stroma and were plump to spindle to stellate with plump ovoid pale nuclei. Occasional nuclear grooving was seen. (H & E, x 400); C) 3c-Tumour showed large areas of cartilaginous differentiation. (H & E, x 100); D) 3d-The stroma was characterized by coarse collagen formation with occasional giant cells. (H & E, x 1000); E) 3e- Few epithelioid cells were also seen in the stroma. (H & E, x 1000)

On microscopy, it was a well-circumscribed, partially encapsulated, hypocellular, vaguely nodular myxoid tumour with large areas of cartilage and foci of adipose tissue (Fig. 3a above). The tumour cells were embedded in a myxoid stroma and were plump to spindle to stellate with plump ovoid pale nuclei with occasional nuclear grooving (Fig. 3b). The stroma was characterized by coarse collagen formation with chondroid differentiation (Fig. 3c). Also occasional giant cells and epithelioid cells were seen (Figs. 3d and 3e). Areas of hemorrhage and necrosis were absent. Immuno-

staining showed diffuse positivity of the spindled tumour cells for CD34 and Desmin (Figs. 4a and 4b), however S-100 and cytokeratin were negative. The overall features favoured the diagnosis of myofibroblastoma. Our patient recovered well after surgery without any complications. No recurrence of the tumor was seen after complete surgical excision on follow-up duration of five months.

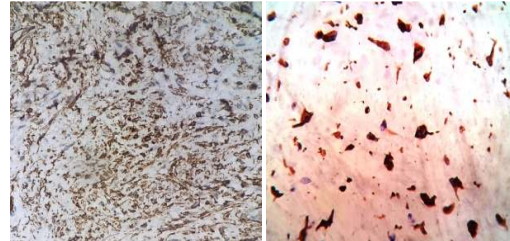


Fig. 4a

Fig. 4b

Fig. 4. A) 4a- Immuno-staining showed diffuse positivity of the spindled tumour cells for CD34; B) 4b- Immuno-staining showed diffuse positivity of the spindled tumour cells for Desmin

3. DISCUSSION

Myofibroblastoma is a benign mesenchymal tumour commonly involving breast in elderly males. The extra-mammary location is very rare for this tumour [4].

The literature review shows that extra-mammary MFB is rare with few reported cases and has male predilection and median age of 53 years (36-67 years). In English literature only six cases have been reported below 21 years of age and most were teenagers. The prior youngest reported case was in a nine-year-old girl with left groin swelling [7]. The extra-mammary MFB cases reported below 21 years of age are given in Table 1.

To our knowledge, there is no MFB case occurring below five years of age. Thus this is the youngest reported MFB case.

It has been extensively studied in literature that the location of extra-mammary MFB is mainly along the embryonic milk-line extending from mid-axilla to medial groin [2,4,6]. Nevertheless few cases have been reported outside milk-line sites like buttock, mid-back, para-testicular region, seminal vesicle, vulva, vaginal wall, popliteal fossa, thigh, liver and head-neck regions [3].

Among the extra-mammary location of MFB, the pelvic sites are more in number than extra-pelvic sites. The pelvic sites are five cases in inguinal area, three cases each in vulva and vagina, two cases each in para-testicular region and buttock, one case each in seminal vesicle, peri-anal region and supra-pubic area. None have been reported in axillary soft tissue [4]. The six cases reported outside the pelvis are mandibular area, popliteal fossa, abdominal wall, liver, back and thigh. There is only one MFB case in axilla which has been reported by Mackay et al. [2].

Most of the tumours are diagnosed incidentally and are of small size. The tumor size ranges from 2-13 cm with median size of 5.5 cm [2,4,5,6]. Recently Abdul-Ghafar et al. in 2015 [4] have reported a largest myofibroblastoma of 34 cm in medial aspect of thigh in a 50-year-old male.

Grossly this tumor is well circumscribed, and partly encapsulated. Cut surface is grayish white, pink with whirling or nodular appearance with no evidence of necrosis, hemorrhage. Microscopically mammary MFB shows variably sized fascicles of spindle to oval cells embedded in hyalinised and collagenous stroma with variable intra-lesional fatty component. Few cases have shown cartilaginous and smooth muscle differentiation [1]. In our case, macroscopic and microscopic features are similar to that of mammary-type MFB, but

characteristically cartilaginous differentiation was present with occasional giant cells and epithelioid cells. Other MFB variants which have been reported include collagenous/ fibrous, epithelioid, cellular and infiltrative types [1,2,4].

So far known, all the 20 cases of extra-mammary myofibroblastoma show both macro and microscopic features similar to mammary myofibroblastoma [4], except one case with mixed pattern of angiomyofibroblastoma and mammary-type myofibroblastoma of soft tissue [7]. On immunohistochemistry, MFB shows positivity for CD34 and Desmin [2,4,5,6].

The differential diagnosis of this tumor includes benign lesions such as spindle cell lipoma, angiofibroma, angiomyofibroblastoma, soft tissue perineuroma and nodular fasciitis. Few malignant tumours which should be taken into consideration include spindle cell liposarcoma, low grade malignant peripheral nerve sheath tumor and dermatofibrosarcoma protuberans [2,4]. As these tumours are benign, they have excellent prognosis. No recurrence or metastasis is seen after surgical excision in the reported cases [2,4,5,6].

Awareness about this tumour occurring in paediatric population amongst paediatric surgeons, oncologists and pathologists is essential for the management.

Table 1. Reported cases of extramammary myofibroblastoma below 21 years of age

Serial no.	Report	Year of report	Sex	Age in years	Site	Clinical presentation	Tumour size
1.	Current case	2015	Male	4	Left axillary soft tissue mass	Tender left axillary mass	8 x 5 x 6 cm
2.	Santos et al. [8]	2012	Female	12	Lymph node of inguinal region	Painless enlargement of lymph node	3 cm
3.	Chami et al. [7]	2012	Female	9	Left groin - lymph node mass	Painless mass	4 cm
4.	Magro et al. [9]	2012	Female	15	Oral cavity	Asymptomatic	3.5 cm
2.	Lee et al. [6]	2005	Female	12	Anterior chest wall mass	Painless mass	5 cm
5.	Montella et al. [10]	2004	Female	16	Vulva	Painless mass	3 cm
6.	Qublan et al. [11]	2002	Female	17	Vulva	Painless mass	8 cm

4. CONCLUSION

Extra-mammary myofibroblastoma is a rare entity and is uncommon in paediatric population below the age of five years.

CONSENT

All authors declare that written informed consent was obtained from the patient (or other approved parties) for publication of this case report and accompanying images.

ETHICAL APPROVAL

It is not applicable.

COMPETING INTERESTS

Authors have declared that no competing interests exist.

REFERENCES

1. Magro G. Mammary myofibroblastoma: A tumor with a wide morphologic spectrum. *Arch Pathol Lab Med.* 2008;132:1813-20.
2. Hox V, Vander Poorten V, Delaere PR, Hermans R, Debiec-Rychter M, Sciot R. Extramammary myofibroblastoma in the head and neck region. *Head Neck.* 2009;31:1240-4.
3. Arsenovic N, Abdulla KE, Shamim KS. Mammary-type myofibroblastoma of soft tissue. *Indian J Pathol Microbiol.* 2011; 54:391-3.
4. Abdul-Ghafar J, Din NU, Ahmad Z, Billings SD. Mammary-type myofibroblastoma of the right thigh: A case report and review of the literature. *J Med Case Rep.* 2015; 9:126.
5. McMenamin ME, Fletcher CD. Mammary-type myofibroblastoma of soft tissue: A tumor closely related to spindle cell lipoma. *Am J Surg Pathol.* 2001;25:1022-9.
6. Lee H, Lee OJ, Cho KJ, Ro HY. Epithelioid Myofibroblastoma of Mammary-type in Chest Wall - A Case Report. *The Korean Journal of Pathology.* 2005;39:130-3.
7. Chami R, Ertresvaag K, Azzie G, Thorner PS. Myofibroblastoma: report of a rare entity in the pediatric population. *Pediatr Dev Pathol.* 2012;15:499-506.
8. Santos MI, Salgado C. Intranodal myofibroblastoma: A case report. *Cir Pediatr.* 2012;25:117-9.
9. Magro G, Caltabiano R, Kacerovská D, Vecchio GM, Kazakov D, Michal M. Vulvovaginal myofibroblastoma: expanding the morphological and immunohistochemical spectrum. A clinicopathologic study of 10 cases. *Hum Pathol.* 2012;43:243-53.
10. Montella F, Giana M, Vigone A, Surico D, Surico N. Angiomyofibroblastoma of the vulva: Report of a case. *Eur J Gynaecol Oncol.* 2004;25:253-4.
11. Qublan HS, Fayyad LM, Al-Ghoweri AS. Angiomyofibroblastoma of the vulva occurring in a teenaged girl. *J Obstet Gynaecol.* 2002;22:562-3.

© 2015 Agale et al.; This is an Open Access article distributed under the terms of the Creative Commons Attribution License (<http://creativecommons.org/licenses/by/4.0>), which permits unrestricted use, distribution, and reproduction in any medium, provided the original work is properly cited.

Peer-review history:
The peer review history for this paper can be accessed here:
<http://sciedomain.org/review-history/11382>