

## **Sarcomatoid Carcinoma (Carcinosarcoma) of the Prostate Gland: A Review of the Literature**

**Anthony Kodzo-Grey Venyo<sup>1\*</sup>**

<sup>1</sup>*Department of Urology, North Manchester General Hospital, Delaunays Road Manchester, United Kingdom.*

### **Author's contribution**

*The sole author designed, analyzed and interpreted and prepared the manuscript.*

### **Article Information**

DOI: 10.9734/JCTI/2015/19516

#### Editor(s):

(1) Lingbing Zhang, Department of Surgery, Stanford School of Medicine, USA.

#### Reviewers:

(1) S. Sundaresan, SRM Medical College Hospital and Research Centre, India.

(2) Vincenzo Ravo, INT Pascale Hospital, Naples, Italy.

Complete Peer review History: <http://sciencedomain.org/review-history/10682>

**Review Article**

**Received 13<sup>th</sup> June 2015**  
**Accepted 31<sup>st</sup> July 2015**  
**Published 24<sup>th</sup> August 2015**

### **ABSTRACT**

**Background:** Adenocarcinomas of the prostate gland are commonly encountered globally but other uncommon variants of carcinoma of the prostate are sporadically encountered including primary sarcomatoid carcinoma of the prostate (PSCP).

**Aims:** To review the literature of PSCP.

**Methods:** Various internet search engines were searched for literature on PSCP.

**Literature Review:** About 100 cases of PSCP have so far been reported. PSCP may develop de novo or may emanate following hormonal treatment or radiotherapy for adenocarcinoma of prostate; PSCP may present with LUTS, haematuria, perineal/back pain. Histology of prostate biopsy tends to show a biphasic tumour which has an adenocarcinoma component as well as a second component which is a clearly recognizable type of sarcoma component which could be angiosarcoma, chondrosarcoma, leiomyosarcoma, osteosarcoma or rhabdomyosarcoma. With regard to immunohistochemistry Immunohistochemistry, the epithelial component of sarcomatoid carcinoma of prostate stains positively for cytokeratin and PAP, and negatively for PSA; the sarcoma component stains negatively for PSA, EMA and keratin. There is no consensus opinion on treatment. TURP has been performed for lower urinary tract obstruction symptoms and urinary retention, radical prostatectomy, pelvic exenteration, and chemotherapy are some of the treatments employed. A number of cases of PSCP had presented at advanced stages of the

\*Corresponding author: Email: [akodzogrey@yahoo.co.uk](mailto:akodzogrey@yahoo.co.uk);

disease. PCSP is aggressive with poor prognosis; however, early aggressive surgery in some cases had resulted in survival.

**Conclusions:** A multi-centre trial is required to determine the best treatment option for PSCP. Perhaps patients with progressing prostate cancer following radiotherapy of castrate resistant prostate cancer should have repeat prostate biopsies to determine if they have developed dedifferentiation into PSCP or other variants of prostate cancer and to try cases of PSCP on chemotherapy as a trial.

*Keywords: Sarcomatoid carcinoma of prostate; carcinosarcoma; immunohistochemistry; cytokeratin; PAP; EMA; PSA.*

## 1. INTRODUCTION

Sarcomatoid carcinoma (carcinosarcoma) of the prostate is a rare tumour which can occur, de novo or following hormonal treatment or radiotherapy. It may be that lots of cases of PSCP are not detected and reported because many patients with castrate resistant carcinoma of prostate and patients with progressive carcinoma of prostate despite having had radiotherapy do not undergo repeat prostate biopsies to further assess the carcinomas and thus missing dedifferentiation of adenocarcinoma into other variants of prostate cancer. The ensuing review of the literature on sarcomatoid carcinoma (carcinosarcoma) of the prostate gland is divided into two parts: (A) overview and (B) discussions and narrations from some reported cases.

### 1.1 Aim

To review the literature relating to primary sarcomatoid carcinoma (carcinosarcoma) of the prostate gland.

## 2. METHODS

Various internet data bases were searched including: Google, Google Scholar; PUB Med, Medline, and Educus. The search words used included sarcomatoid carcinoma of prostate; carcinosarcoma of prostate. Information obtained from 24 references was used for the literature review.

## 3. LITERATURE REVIEW

### 3.1 General Comment

- Sarcomatoid variant of carcinoma of the prostate gland is an uncommon malignancy and about 100 cases of the disease have so far been reported.

- PSCP is an aggressive and not well known disease with poor eventual outcome in majority of cases.
- This is a complete review of the literature on PSCP that underlines the necessity of early diagnosis and early aggressive surgical treatment.

### 3.2 Other Terminologies

- Other terminologies have been used for sarcomatoid variant carcinoma of the prostate and these include: sarcomatoid carcinoma, metaplastic carcinoma, spindle-cell carcinoma, and malignant mixed mesodermal tumour [1].

### 3.3 Aetiology

- Postulates relating to the aetiology of sarcomatoid carcinoma of the prostate gland include: it could either be representative of sarcomatoid transformation of prior adenocarcinoma of the prostate or it could be related to previous radiotherapy treatment or to previous hormonal therapy [1].

### 3.4 Presentation

Patients with sarcomatoid carcinoma of the prostate may present with:

- Lower urinary tract storage symptoms (frequency, urgency, urge incontinence) and voiding symptoms (poor stream, hesitancy, incomplete emptying of bladder) [2]
- Inability to void with retention of urine [2]
- Rarely they may present with haematuria and perineal pain [2]
- There may be a history of previous radiotherapy to a prostatic carcinoma or hormonal therapy for prostatic carcinoma. [3]

- Clinical examination findings including digital rectal examination which may show an enlarged prostate which could feel benign, irregular, nodular, hard or feel like a mass protruding into the rectum.

### 3.5 Laboratory Tests

Full blood count, serum urea and electrolytes, liver function tests, coagulation screen, urinalysis and urine culture and sensitivity are some of the routine tests that are done as part of the screening assessment of patients with carcinoma of prostate. Serum prostate-specific antigen (PSA) tests are routinely carried out in the initial investigation and follow-up of patients following treatment for adenocarcinoma of prostate. With regard to serum PSA and sarcomatoid carcinoma of prostate is that a number of cases of sarcomatoid carcinomas of prostate are associated with low-levels of serum PSA therefore serum PSA would not be that useful in the follow-up assessment of the sarcomatous component of sarcomatoid carcinoma of the prostate gland even though it may be useful in assessing the progress of the adenocarcinoma component of the tumour. The clinical progress of the patient and thorough clinical assessment of the patient as well as various radiological investigations are on the other hand useful in the follow-up assessment of the patients.

## 4. RADIOLOGICAL INVESTIGATIONS

### 4.1 Ultra-sound Scan of Renal Tract and Pelvis

Ultra-sound scan of the renal tract, abdomen and pelvis are useful in the general initial assessment of the patient for the characteristics of the tumour and the relationship of the tumour to near-by organs and the size of the prostate gland. The ultra-sound scan is also useful for the detection and exclusion of hydronephrosis as well as metastatic lesions in the lymph nodes and other organs in the abdomen and pelvis. Ultra-sound guided insertion of nephrostomy plus or minus insertion of ante-grade ureteric stent can also be performed in cases of ureteric obstruction.

### 4.2 Computed Tomography (CT) Scan

CT scan of abdomen, pelvis, and thorax is useful for the assessment of the prostate and

assessing whether or not there are any metastatic lesions in the pelvis, abdomen and thorax and bone lesions can also be picked up. CT scan is useful for the TNM staging of the tumour.

### 4.3 Magnetic Resonance Imaging (MRI) Scan

MRI scan is very useful in assessing the characteristics of the prostate as well as the prostatic lesion and its relationship with nearby organs. MRI scan is also useful in detecting or excluding metastatic lesions in the abdomen, pelvis and thorax. MRI scan is also useful for the TNM staging of the tumour.

### 4.4 Positron Emission Tomography (PET) Scan

PET scan is useful in assessing for metastatic lesion anywhere in the body.

### 4.5 Isotope Bone Scan

Isotope bone scan is useful in assessing whether or not a patient has or does not have bone metastasis.

Trans-rectal ultra-sound scan guided prostate biopsies / TUR /prostatectomy specimens.

Specimens of the prostate gland by means of trans-rectal ultra-sound guided biopsy, trans-urethral resection of prostate or prostatectomy are used for the histopathological examination which is used for the diagnosis of the tumor and for assessing the degree of differentiation and grading of the tumours.

### 4.6 Macroscopic Features

- There is nothing specific in the appearance of the gross appearance of a biopsy specimen of the prostate gland or prostatectomy specimen that is distinctive or diagnostic of sarcomatoid carcinoma of the prostate. Histological examination is required to establish the diagnosis.
- However, the prostatectomy specimens may consist of firm, greyish white nodular masses with variegated haemorrhagic surfaces [4].

### 4.7 Microscopic Features

- Sarcomatoid carcinoma of prostate gland (carcinosarcoma of the prostate gland) is a

biphasic tumour which has an adenocarcinoma component as well as a second component which is a clearly recognizable type of sarcoma component which could be angiosarcoma, chondrosarcoma, leiomyosarcoma, osteosarcoma or rhabdomyosarcoma [1].

- A carcinoma of the prostate gland therefore is called sarcomatoid carcinoma of prostate (carcinosarcoma of prostate) if microscopic examination of a prostate biopsy specimen or prostatectomy specimen shows (a) features of adenocarcinoma of the prostate and any of the type of the aforementioned sarcomas.

#### 4.8 Immunohistochemistry Features

The epithelial component of sarcomatoid carcinoma of prostate stains.

- Positively for cytokeratin and PAP [5]
- Negatively for PSA [5]

The sarcoma component of sarcomatoid carcinoma of prostate (carcinosarcoma) stains:

- Negatively for PSA, EMA and keratin [5]

#### 4.9 Differential Diagnosis

Some of the differential diagnoses of sarcomatoid carcinoma of the prostate include:

- Primary sarcoma of the prostate gland [1]
- Benign spindle cell proliferations of the prostate gland for example inflammatory myofibroblastic tumour (pseudosarcomatous fibromyxoid tumour) [1]
- Post-operative spindle cell nodule

It has been stated that the aforementioned conditions could be confused with the mesenchymal component of sarcomatoid carcinoma and that with regard to recurrent tumours, the mesenchymal component often overgrows the epithelial component and hence a pure sarcomatous pattern within the setting of pretreated adenocarcinoma of prostate should be diagnosed as sarcomatoid carcinoma [1].

#### 4.10 Treatment

- In view of the rarity of PSCP, there is no consensus on treatment. A number of patients would under prostatectomy by means of the open method of by trans-

urethral resection and histological examination of the specimen would confirm PSCP. In such situations adjuvant treatment with radiotherapy and or chemotherapy could be given. Nevertheless, it is worth noting that some cases of sarcomatoid carcinoma transformation develop after the patients had previously undergone radiotherapy for adenocarcinoma of prostate in view of this it is unlikely that radiotherapy would be effective. About 55.5% of cases of PSCP do not respond effectively to systemic chemotherapy.

- Aggressive surgical operation in the form of radical prostatectomy or anterior exenteration or total pelvic exenteration would appear to be the best approach with curative intent and this could be combined with adjuvant therapy.
- In cases of advanced disease supportive therapy / palliative therapy would be required. Patients with bilateral or unilateral obstruction of the ureter would require nephrostomy plus or minus insertion of ureteric stent(s); Some patients may require catheterization of the urinary bladder by means of urethral catheterization or insertion of urethral catheter; pain control and other supportive and support of the patient and his family through a multi-disciplinary team approach (Palliative care team, urologists, urology nurse specialist, oncologist, General Practitioner, the district nurse and the social care team) may be required to provide good delivery of care.
- Hormonal therapy would only be able to control the adenocarcinoma component of the prostatic tumour but would be ineffective in treating the sarcomatoid component of the tumour. Furthermore, considering the fact that a number of cases of sarcomatoid carcinoma develop following hormonal treatment for adenocarcinoma of the prostate, hormonal treatment would not be expected to be effective treatment for PSCP.

#### 4.11 Outcome

- Hansel and Epstein [3] had stated that sarcomatoid carcinoma (carcino-sarcoma) of the prostate gland is associated with an aggressive clinical course and that the prognosis of which dismal irrespective of other histological or clinical findings.

## 5. DISCUSSION AND MISCELLANEOUS NARRATIONS FROM SOME REPORTED CASES

Hansel and Epstein [3] stated that sarcomatoid carcinoma of the prostate gland is a rare variant of carcinoma of the prostate gland and apart from 1 previous study the morphological features of sarcomatoid carcinoma of the prostate gland and outcome of the patients had only been reported only in individual case reports and relatively small case series. Hansel and Epstein [3] examined specimens of the prostate gland which were obtained by means of trans-urethral resection, needle biopsy of prostate and radical prostatectomy from 42 patients who had been diagnosed as having sarcomatoid carcinoma of the prostate gland. Hansel and Epstein [3] stated that they were able to obtain clinical information on 32 patients. With regard to the results, Epstein and Hansel [3] reported the following:

- History of prior adenocarcinoma of prostate: Twenty one patients (66%) who constituted the majority of patients had a prior history of acinar adenocarcinoma of the prostate gland. The reported Gleason scores of the adenocarcinomas of the prostate of 14 patients whose clinical data were available to them were Gleason 6, 7 patients; Gleason 8, 4 patients; and Gleason 10, 3 patients. With regard to the remaining patients whose data were known, 11 of the patients had presented with de novo sarcomatoid carcinoma. The mean interval of time between the original diagnosis of acinar adenocarcinoma of prostate and the subsequent diagnosis of sarcomatoid carcinoma of prostate was 6.8 years and the ages had ranged between 6 months and 16 years.
- Concurrent adenocarcinoma of prostate: Most of the patients had a concurrent high-grade acinar carcinoma of prostate. Three patients had Gleason score 7; nine patients had Gleason score 8; ten patients had Gleason score 9; and ten patients had Gleason score 10. A sub-set of the patients had other types of concurrent tumours. Four patients had ductal adenocarcinoma of prostate, three patients had small cell carcinoma of prostate, three patients had squamous cell carcinoma of prostate, and three patients had other unusual pattern of carcinoma of the prostate gland. With regard to one of the patients, the diagnosis was made based upon the immunohistochemistry evidence of epithelial differentiation together with the history of prior adenocarcinoma of the prostate gland.
- Morphology of the sarcomatoid component of the tumour: The mean percentage of sarcomatoid-growth in the tumour was 65% and the percentage sarcomatoid-growth in the tumour had ranged between 5% and 99%. Fifty five percent of the tumours had bizarre atypia with giant cells. Ten of the cases (29%) had admixed heterologous elements which included 7 cases with osteosarcomatous elements, 5 cases with chondrosarcomatous elements, and two patients with rhabdomyosarcomatous elements.
- Immunohistochemistry: Out of the 12 cases in which immunohistochemistry was performed, 5 out of 7 cases exhibited focal positivity for cytokeratin, 1 case out of 1 was focally positive for Cam5.2, and 3 cases out of 6 cases were focally positive for prostatic acid phosphatase. The sarcomatoid component did not show any immunoreactivity for prostate-specific antigen in 8 cases.
- Prognosis: About half of all the patients had developed metastatic disease either at the time of presentation or later on. With regard to patients who had meaningful follow-up, six out of seven had died within one year of the diagnosis of sarcomatoid carcinoma of prostate; twenty of the patients at the time of publication of the paper were alive with very short follow-up with a median follow-up of one year and a mean follow up of 2.3 years. Kaplan-Meier analysis of the above results had shown that the actuarial risk of death at 1 year after the diagnosis of sarcomatoid carcinoma of prostate was 20%. There was no correlation found between the survival of patients and morphological characteristics, before radiotherapy or hormonal therapy, or evidence of concurrent high-grade carcinoma of prostate.
- Sarcomatoid carcinoma of prostate does demonstrate diverse spindle and epithelial cell morphologies. The sarcomatoid component of the prostatic carcinoma quite often exhibits heterologous elements, and in one case, there was no evidence of epithelial component on examination of haematoxylin and eosin-

stained sections of the tumour. The epithelial component of sarcomatoid carcinoma of prostate characteristically high-grade acinar adenocarcinoma, but other aggressive sub-types of tumour inclusive of ductal adenocarcinoma and small cell carcinoma may also be observed. Sarcomatoid carcinoma of the prostate is an aggressive form of carcinoma of the prostate gland, the prognosis of which is dismal irrespective of other histological or clinical findings.

AçJkgöz et al. [2] reported a 54-year-old man who had been on alpha-blocker therapy for the preceding year who presented with a 6-months history of lower urinary tract symptoms which included nocturia (3-4 times per night), pollakiuria, and poor urinary flow with a decrease in the stream of his urine. He had a digital rectal examination which revealed a grade 1 mildly enlarged benign feeling prostate gland. He had trans-rectal ultra-sound scan of prostate revealed a prostate volume of 40 cc and normal ultra-sound scan appearance. His serum PSA was 20.5 ng/ml but the rests of his laboratory tests including serum urea and electrolytes, ALP and urinalysis were normal. He then had trans-rectal ultra-sound guided biopsy of prostate and its histology was found to show benign prostatic biopsy. He then underwent trans-urethral resection of prostate (TURP) and histological examination of the specimen revealed Gleason 5 + 3 = 8 adenocarcinoma of prostate (see Fig. 1a). He then had CT scan of abdomen, pelvis, and thorax as well as isotope bone scan which were normal. He was scheduled to undergo radical prostatectomy but during the procedure sampling of his obturator lymph nodes was undertaken and frozen section histological examination had revealed adenocarcinoma in the right obturator lymph node therefore the procedure of radical prostatectomy was abandoned and he was put on total androgen blockade. His serum PSA was noted to have come down to 0.6 ng/ml at his 1 month follow-up and his total androgen blockade was continued. At 3 months following his abandoned operation he was readmitted with acute lower urinary tract symptoms and he had ultra-sound scan of renal tract and pelvis which showed left sided hydronephrosis and a 2 cm mass in the prostate. He therefore underwent cystoscopy and what was considered to have been complete resection of the prostatic lesion that had projected into the urinary bladder and histological examination of the specimen had shown poorly differentiated

tumour cells and the tumour was therefore classified as an undifferentiated tumour and detection of adenocarcinoma in <1% focus (see Fig. 1b). Immunohistochemistry did show to be negative for pancytokeratin. He was continued on his total androgen blockade. Four months pursuant to his latest operation he was admitted because of inability to void. His serum PSA then was 1.77 ng/ml and his serum urea and electrolytes were normal. He underwent cystoscopy which had revealed regrowth of prostatic tissue projecting into and almost completely filling his urinary bladder for which incomplete trans-urethral resection of the prostatic lesion was carried out. Histological examination of the specimen showed "sarcomatoid malignant tumour" (see Figs 1c and 1d). Light microscopic examination of the specimen revealed high cellularity, spindle and pleomorphic cells with bizarre appearance, and atypical mitotic Figs. as well as necrosis. The tumour on immunohistochemical analysis revealed the following staining characteristics:

- Negatively stained with Cytokeratin (AE1/AE3)
- Positively stained for Vimentin (V9)
- Positively stained for SMA
- Negatively stained for Factor VIII
- Negatively stained for C-kit (CD117) but there was rare, weak, granular positive staining in the Golgi area.
- Negatively stained for CD34

He had PET CT scan which had shown that he had multiple metastases in the liver, lung and thoraco-lumbar vertebrae. He was referred to the oncology department for radiotherapy and chemotherapy. He was alive at his 9 months follow-up. AçJkgöz et al. [2] stated that:

- Their patient was followed-up under maximum androgen blockade treatment to keep his serum PSA less than 0.2 ng/ml during the disease period. Nevertheless, the efficacy of hormonal therapy observed in adenocarcinoma of prostate could not be experienced on sarcomatoid variant, thus causing the presence of sarcomatoid component to be missed out in patients who are followed-up by successive serum PSA measurements under hormonal therapy.
- Sarcomatoid carcinoma of the prostate gland is one of the rarest malignant types of neoplasms and it has been well known for its aggressive clinical course.

- At the time of publication of their paper in 2013 around 100 cases of sarcomatoid carcinoma of the prostate had been reported in the literature according to [6].
- The most recent World Health Organization (WHO) classification did not distinguish clinically between carcinosarcoma and sarcomatoid carcinoma as two distinct lesions, even though there appears to be cases that are characterized, with regard to pathological diagnoses, with differentiation of adenocarcinoma of the prostate gland into sarcomatoid carcinoma and some others that are characterized with primary carcinosarcoma containing both epithelial and mesenchymal cells. The terminology "sarcomatoid carcinoma" is used for both of these lesions [7].
- Sarcomatoid carcinoma of the prostate gland pursues an insidious course and generally manifests with symptoms related to filling of the urinary bladder (nocturia, urinary urgency and so on) and/or symptoms related to voiding (dysuria, slow urinary stream, hesitancy, terminal dribbling, feeling of incomplete emptying of the urinary bladder in adult and elderly populations. Patients afflicted by sarcomatoid carcinoma of the prostate gland are rarely admitted with haematuria, perineal / rectal pain, or painful ejaculation [8].

AçJkgöz et al. [2] concluded that:

- Sarcomatoid carcinoma is a malignant variant which is associated with diagnostic and treatment difficulties.
- Lack of experience in the subject of sarcomatoid carcinoma of the prostate is a hindrance to the standardization of modalities.
- It had been suggested by Hansel and Epstein [3] that surgical resection of the curative tumours, adjuvant chemotherapy, and / or radiotherapy, together with palliative attempts in patients with advanced staged disease, would constitute the general approach to the management of sarcomatoid carcinoma of the prostate gland.

In 1993, Lauwers et al. [9] stated that carcinosarcoma of the prostate gland is a biphasic which contain adenocarcinoma (ACA) and recognizable sarcomatous components.

They also stated that carcinosarcoma of the prostate is a rare tumour and at the time of the report of their cases in 1993 only 12 cases of carcinosarcoma of the prostate gland had previously been reported. Lauwers et al. [9] reported 3 additional cases which had arisen between 4 and 6 years following the initial diagnosis of adenocarcinoma of prostate. Two of the patients had previously undergone prostatectomy, external beam radiotherapy to the pelvis, and hormonal manipulation. The third patient had previously undergone pelvic lymphadenectomy and 125I implants. Lauwers et al. [9] further stated that following the development of the sarcomatous component of the tumour, the first two patients were still alive with distant metastases and residual pelvic disease at 9 months and 17 months. The third patient died 7 months after the diagnosis of the sarcomatous component of the carcinoma. Lauwers et al. [9] additionally stated that histological examination had shown that adenocarcinoma of prostate was in all of the three cases, as well as neoplastic mesenchymal component of the tumours which appeared later. Foci of osteosarcomatous, chondrosarcomatous, and myosarcomatous differentiation were identified in two of the three cases. Lauwers et al. [9] stated the following:

- Based upon the chronological and histological evolution of the neoplasm, they were in favour of sarcomatoid transformation of the adenocarcinoma of prostate as the most likely histogenesis of carcinosarcoma of prostate gland.
- It would appear that radiotherapy and hormonal treatment may be important in the development of at least some of these tumours.

Adekoyejo Abiodun et al. [4] in Nigeria reported a 60-year-old man who presented with symptoms of bladder outlet obstruction and whose serum PSA at presentation was 0.94 ng/L. Upon clinical assessment a diagnosis of benign prostatic hypertrophy was made. He underwent prostatectomy. The prostatectomy specimen consisted of two firm, greyish white nodular masses with variegated haemorrhagic surfaces. Histological examination of the specimen revealed a biphasic tumour with a predominantly spindle cell component which had comprised 80% of the tumour, as well as clusters and nests of small undifferentiated cells. Nests of a well differentiated keratinizing squamous cell carcinoma were also identified in

the tumour which was EMA positive on immunohistochemical examination. A few of the small undifferentiated cells and stromal cells on immunohistochemistry studies found to be positive for EMA, but they were negative for desmin. Approximately, 40% of cells in stained sections were found to be positive for Ki-67. A diagnosis of sarcomatoid carcinoma of prostate gland with a Gleason score of 10 was made. The case was reported at a time when there was no long-term follow-up. Abiodun et al. [4] stated that to their knowledge even though a few cases of sarcomatoid carcinoma of the prostate have been reported in the literature, there had not been any previously reported case of sarcomatoid carcinoma of the prostate from Nigeria hence their case was the first to be reported from Nigeria. In view of the fact that there was no history of previous radiotherapy or hormonal treatment for prostate cancer in this reported case, it would be argued that the histogenesis of this carcinoma would be de novo carcinoma.

Zizi-Sempetzoglou et al. [6] reported a 76-year-old Caucasian man who had undergone trans-urethral resection of prostate as treatment for bladder outlet obstruction. Histological examination of the specimen showed a tumour which had malignant epithelial and sarcomatoid elements. The malignant epithelial component of the tumour comprised of poorly differentiated adenocarcinoma Gleason 5 + 4 = 9/10 and the sarcomatous component comprised mainly of undifferentiated spindle cells. Immunohistochemistry studies on the sarcomatous component of the tumour revealed positive immunohistological expression for vimentin. Many cells were positively stained for cytokeratin AE3 and myoD1 but all of the cells were negative for actin, desmin, and myogenin. A final diagnosis of sarcomatoid carcinoma of prostate was made. Zizi-Sempetzoglou et al. [6] stated that:

- The sarcomatoid component in sarcomatoid carcinoma of the prostate gland can vary between 5% and 99%.
- Even though sarcomatoid carcinoma of the prostate gland is a very aggressive tumour, and the patients to have poor prognosis, their patient was still alive one year after the diagnosis.

Diao et al. [10] reported a 62-year-old man with adenocarcinoma of the prostate (Gleason 5 + 4 = 9) who was treated by means of androgen blockade and radiotherapy in 2010. His serum

PSA was noted to have risen 13 months after his treatment. He underwent trans-urethral resection of prostate and histological examination of the resected prostate revealed concomitance of squamous cell carcinoma, sarcomatoid carcinoma and adenocarcinoma of prostate Gleason 5 + 5 = 10. With regard to immunohistochemistry studies of the tumour, Diao et al. [10] stated that the expression of epithelial markers E-cadherin and  $\beta$ -catenin were significantly down-regulated, on the other hand mesenchymal marker vimentin was up-regulated in both squamous cell carcinoma and sarcomatoid carcinoma components of the tumour. The expression of androgen receptor (AR) was down-regulated in the squamous cell carcinoma component of the tumour but it was up-regulated in the sarcomatoid carcinoma component of the tumour. From the 13<sup>th</sup> month to the time of death of the patient his serum PSA level increased rapidly to 400 ng/ml. Diao et al. [10] stated the following:

- The altered epithelial and mesenchymal markers and the heterogeneous androgen receptor expression in the relapsed tumour would indicate that the concurrence of unusual sub-types of tumour may emanate from the epithelial – to – mesenchymal transition and / or the differential function of the androgen receptor on the epithelial and stromal cells of the prostate gland.
- Their reported case would indicate concerns regarding anti-androgen regimen for carcinoma of the prostate gland.

Nazim et al. [11] reported a 64-year-old man who had presented with voiding problems and retention of urine. His initial serum PSA level was 9 ng / ml. He had had trans-urethral resection of prostate (TURP) elsewhere. Histological examination of the resected prostate had revealed adenocarcinoma of prostate (Gleason 4 + 5 = 9). He was adjudged to have had locally advanced carcinoma of prostate on clinical staging work-up. He was commenced on luteinizing hormone releasing hormone (LHRH) analogue. Two months pursuant to his initial TURP he failed to void again and urethral catheterization failed. He underwent another TURP and histopathological examination of the specimen had shown adenocarcinoma of the prostate with sarcomatoid variant. Within the subsequent six weeks his voiding symptoms had worsen and he also developed visible haematuria which resulted in retention of urine



and obstructive uropathy. He had insertion of supra-pubic catheter and bilateral percutaneous nephrostomy for bilateral hydronephrosis. At that stage his serum PSA was 0.5 ng/ml. He also developed severe constipation and deep seated pain in the pelvis and perineum. On clinical examination at that stage, a stony hard mass was palpated in his supra-pubic region through which his supra-pubic catheter was coming out. Another hard mass was palpable in his perineum which had involved the bulb of his penis. He had a digital rectal examination which revealed a stony, hard, irregular mass which had totally occluded the lumen of the rectum. He had magnetic resonance imaging (MRI) scan which showed an abnormal heterogeneous signal intensity mass lesion in the pelvis which had shown peripheral post-contrast enhancement with central necrotic component which measured 13 cm x 11 cm x 14 cm in the antero-posterior (AP), transverse and cranio-caudal dimensions and it had extended down into the perineum where it measured 8.9 cm x 3.8 cm x 5.2 cm and was noted in this area to have involved the root of the penis. The mass had infiltrated superiorly into the urinary bladder and had completely filled the lumen of the urinary bladder. The mass had abutted the symphysis pubis anteriorly. The mass on the posterior aspect had involved the rectum with loss of fat planes and on the lateral aspect had extended to the lateral pelvic wall. He also had computed tomography (CT) scan of thorax and isotope bone scan which did not reveal any metastasis. He underwent total pelvic exenteration with pelvic lymphadenectomy along with urinary and faecal diversion with ileal conduit and an end colostomy. The pelvic tumour was said to have been completely resected in two pieces in view of difficult dissection without any spillage and gross evidence at the end of the operation. The residual perineal aspect of the tumour was removed via an elliptical incision with a wide margin of normal tissue together with total penectomy. A margin of tissue was also excised from the anterior abdominal wall along with the cystotomy tract. At the end of the procedure, complete gross clearance was achieved with no palpable or visible disease. Histological examination of the surgical specimens revealed a mixture of carcinomatous and sarcomatous components which had comprised diffuse sheets and aggregate of oval and spindle shaped cells which were arranged in short interlacing fascicles with areas of chondroid, osteogenic, squamous differentiation. With regard to the immunohistochemistry profile of the tumour,

cytokeratin AE1/AE3 and cytokeratin cam5.2 immunohistological studies were undertaken which revealed focal positivity and PSA staining was negative. Histological examination also showed that two recovered pelvic lymph nodes were involved by the tumour. The patient was alive and well without any evidence of recurrence at his 4 months follow-up based upon CT scan of abdomen, pelvis and thorax which he had. Nazim et al. [11] stated the following:

- Many postulates have been promulgated regarding the histogenesis of sarcomatoid carcinoma of prostate which include (1) simultaneous development of both sarcoma and carcinoma from different regions of the same prostate. (2) Dual differentiation of malignant precursor (totipotential as promulgated by Kubusawa et al. [12], (3) transformation of adenocarcinoma into sarcoma and vice versa as iterated by Quay et al. [13] and Lauwers et al [9], (4) de-differentiation of tumour as a result of the effect of hormonal or radiotherapy treatment as suggested by some authors [9,14,15] Nevertheless, loss-of-heterozygosity (LOH) analysis studies which had been undertaken on tissue samples had shown that both the malignant epithelial and mesenchymal components of sarcomatoid carcinoma were clonally related which would be in support of the hypothesis of a single malignant transformation process [16,17].
- In their case, there was only adenocarcinoma in the original trans-urethral resected specimen of the prostate but the subsequent pelvic exenteration specimen contained adenocarcinomatous component mixed with sarcomatous component. Their patient did not receive hormonal therapy or radiotherapy. They would therefore postulate the histogenesis of the tumour to have emanated from transformation of adenocarcinoma of the prostate to the sarcomatous component.
- In most of the previously reported cases of sarcomatoid carcinoma of prostate, there was a history of prior adenocarcinoma of the prostate gland and the reported interval between the diagnosis of the original adenocarcinoma of prostate and the sarcomatoid carcinoma was between 6 months and 16 years [18]. Nevertheless, in their case the interval was only 3 months which would indicate which would

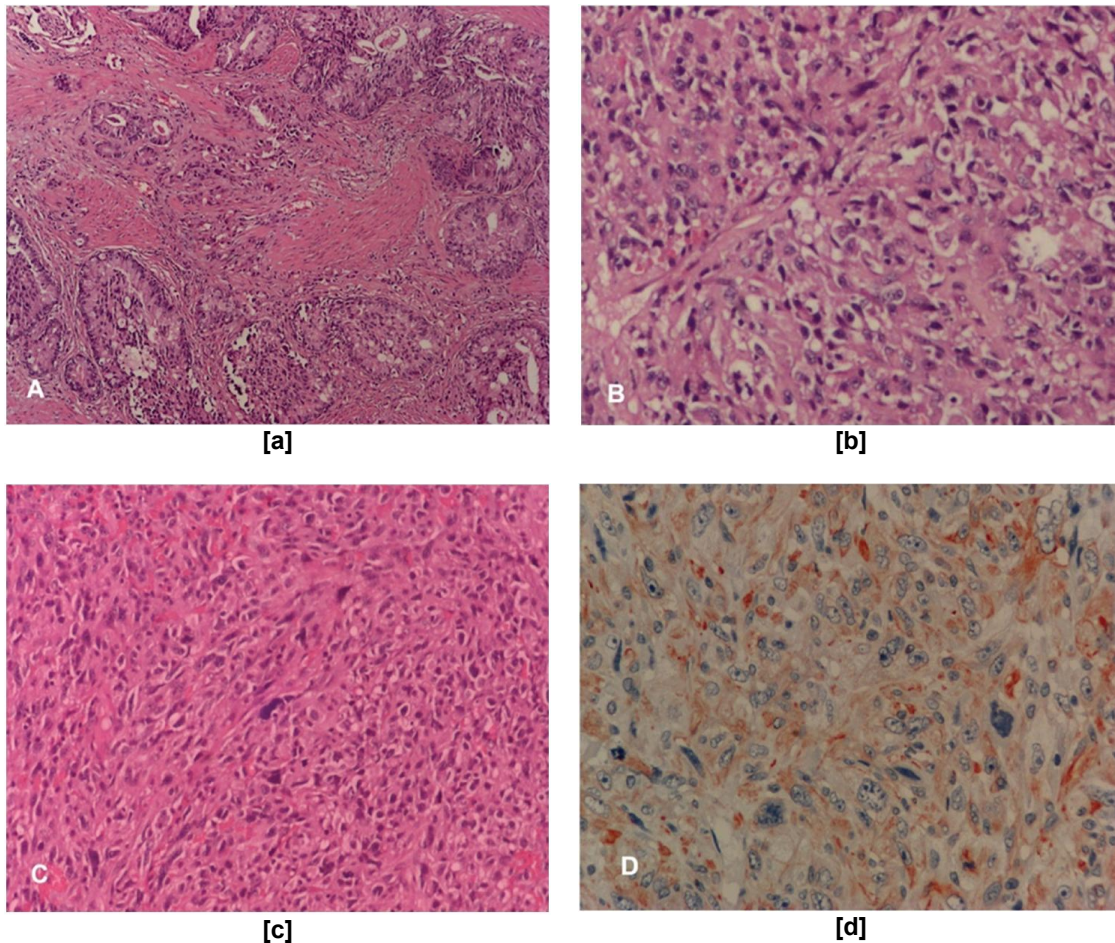
- explain the very aggressive disease process.
- Previously reported cases of sarcomatoid carcinoma of prostate had shown the epithelial component of the tumour to be high-grade adenocarcinoma. It had been stated that [18] morphologically, the sarcomatoid component of carcinosarcoma had varied from 5% to 99% of the total tumour and the sarcomatoid components tend to be composed of undifferentiated spindle and pleomorphic cells which are arranged in fascicles and sheets. A variety of subtypes of sarcoma can also be found and these include osteosarcoma in 50% of cases, chondrosarcoma in 33% of cases, and leiomyosarcoma in 17% of cases, and rarely rhabdomyosarcoma, malignant fibrous histiocytoma and fibrosarcoma. [19] Their patient had mostly undifferentiated sheets of large spindle cells with few areas of osteogenic, chondrogenic, and squamous differentiation.
  - Most patients with carcinomatoid carcinoma of the prostate manifest with obstructive voiding symptoms. Dundore et al. [20] in a series of 21 patients reported that carcinosarcoma was subsequently diagnosed in 18 patients who had previously undergone TURP secondary to obstructive symptoms [20] An equal number of patients who are afflicted by sarcomatoid carcinoma of the prostate gland have normal and higher PSA levels.
  - Fukawa et al. [21] had stated that sarcomatoid carcinoma of the prostate is associated with an aggressive course with local and systemic spread. As a result of extensive rapid growth, and about half of the patients subsequently develop urinary and faecal obstruction and severe pelvic or perineal pain as a sequel of involvement/compression of pelvic nerves.
  - A number of treatment options including radiotherapy, hormonal treatment, chemotherapy and surgery been used in cases of sarcomatoid carcinoma of prostate with disappointing outcomes. Some authors [21,22] of the opinion that surgical removal should be the first line therapy for sarcomatoid carcinoma of the prostate with potential cure. The aforementioned approaches depend upon the extent of the tumour and include radical surgery, (radical retro-pubic

prostatectomy, cystoprostatectomy or pelvic exenteration).

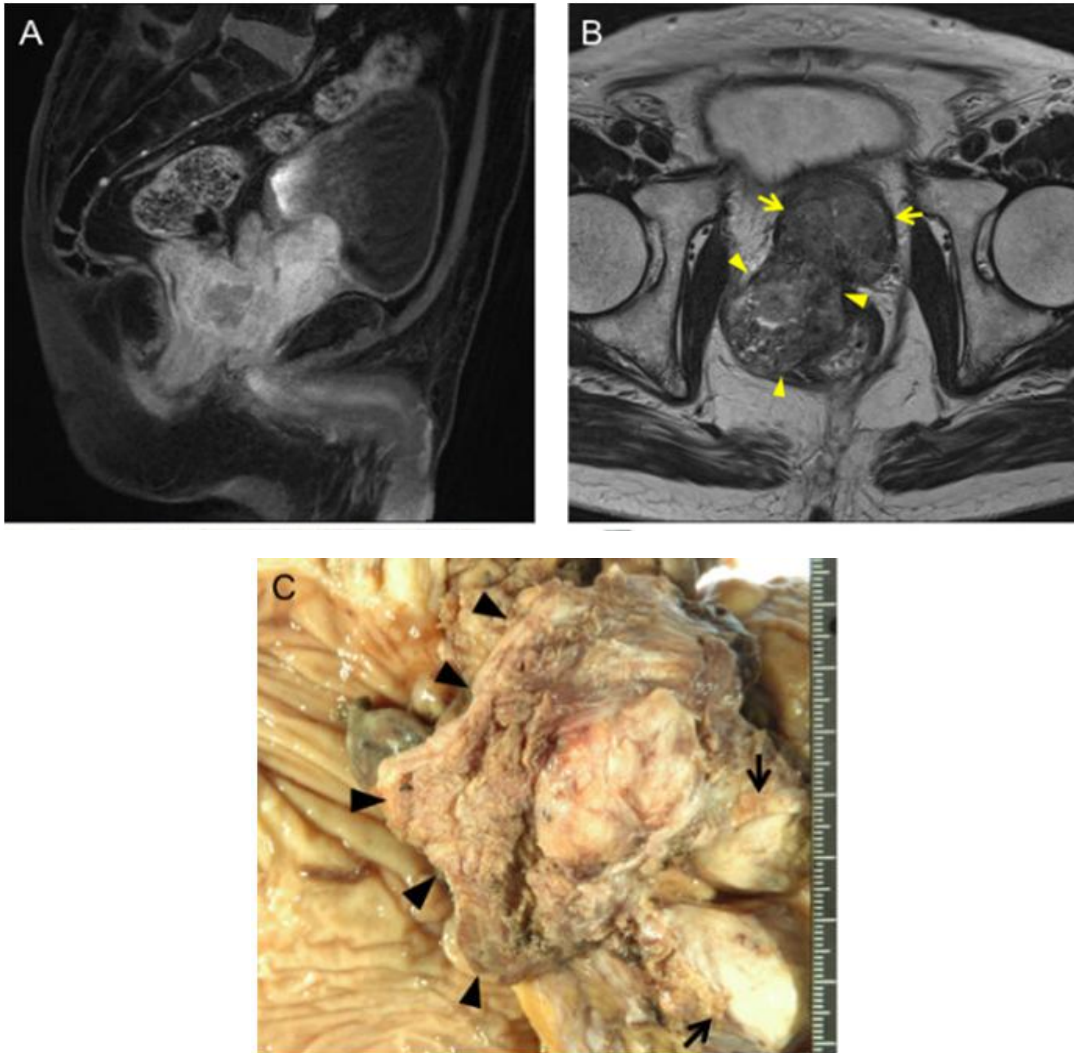
Goto et al. [23] in 2010 reported a 75-year-old man who presented in 2008 with nocturia. His serum PSA level was 14.37 ng/ml (normal range 0.0 to 4.0 ng/ml). He had computed tomography (CT) scan of abdomen and pelvis which showed a large prostate which had invaded the rectum and urinary bladder. He had trans-rectal ultrasound guided biopsy of prostate and histological examination of the specimen revealed a poorly differentiated adenocarcinoma of prostate. He was commenced on maximum androgen blockade and after one month his serum PSA level had remained within normal range. He then had magnetic resonance imaging (MRI) scan of pelvis which had shown that the prostate gland had decreased in size; however, the mass invading the urinary bladder and the rectum had got larger [see Fig. 2a, b]. Six months after his initial presentation, he underwent pelvic evisceration for the carcinoma of prostate [see Fig. 2c]. Histological examination of the specimen revealed a poorly differentiated adenocarcinoma Gleason 4/5 in the prostate gland as well as an undifferentiated sarcomatoid carcinoma which had consisted of spindle cells arranged in fascicles in the area of the posterior invasion of the tumour [see Figs. 3a-c]. The undifferentiated carcinoma component was found to contain numerous multi-nucleated giant cells. On immunological staining, the undifferentiated was positively stained for cytokeratin AE1/3, but negatively stained for cytokeratin 7, cytokeratin 20, vimentin and PSA (see Fig. 3d). His follow-up serum PSA level had remained normal. Three months after the pelvic exenteration procedure the patient had a CT scan of thorax which had shown a small nodular shadow in his right lung [see Fig. 4a]. The authors stated that at the mediastinal window setting, the tumour in the right lung, showed a density similar to that of large vessels [see Fig. 4b]. The patient was continued on total androgen blockade but despite this the tumour in the right lung got bigger. He had Positron emission tomography (PET) scan which apart from showing abnormal fluorodeoxy glucose uptake in the small nodular shadow in the right lung it did not show any abnormality anywhere else. Eleven months after his initial presentation, he underwent bronchoscopy and thoracoscopic wedge resection nodular mass in the lung [see Fig. 5a]. The lung tumour was noted to have a surface that was covered with pleura, protruded into the pleural cavity in a polypoidal fashion

[see Fig. 5a and 5b]. Histological examination of the specimen showed similar characteristics to the original sarcomatoid carcinoma of the prostate gland therefore a diagnosis of metastatic pulmonary sarcomatoid carcinoma ensuing primary sarcomatoid carcinoma of the prostate was made [see Fig. 5c and 5d]. Numerous multi-nucleated giant cells were also seen and there evidence of good microvasculature in the tumour on microscopic examination. Immunohistological staining of the

tumour showed positive staining cytokeratin AE1/AE3 and negative staining for cytokeratin 7, cytokeratin 20, vimentin, and PSA (see Fig. 5e). The patient next received combination systemic chemotherapy with cisplatin, ifosfamide, and Adriamycin. He was alive and free from tumour recurrence 10 months following his lung surgery. The authors stated that their case was the first case of solitary pulmonary metastasis from sarcomatoid carcinoma of the prostate to be reported in the literature.



**Fig. 1. (a) Gleason 5 + 3 = 8 prostate adenocarcinoma in the pathological examination of the first TUR-P material (an area which has more glands). (b) Undifferentiated tumour cells in pathological examination of the second TUR-P material. (c) Sarcomatous areas in the last TUR-P material (spindle and rare bizarre cells). (d) Sarcomatoid cells in immunohistochemical examination (Vimentin positive / AEC chromagen). Reproduced from: [2] AçJkgöz O, Gazel E, Zengin E Z, Kasap Y, Çamtosun A, Yazicioglu A H. Sarcomatoid Carcinoma of the Prostate. Case Reports in Urology.2013; Article ID 631809, 3 pages <http://dx.doi.org/10.1155/2013/631809> Copy Right © 2013 Onur AçJkgöz This is an open access article distributed under the Creative Commons Attribution License which permits unrestricted use, distribution, and reproduction in any medium, provided the original work is properly cited**



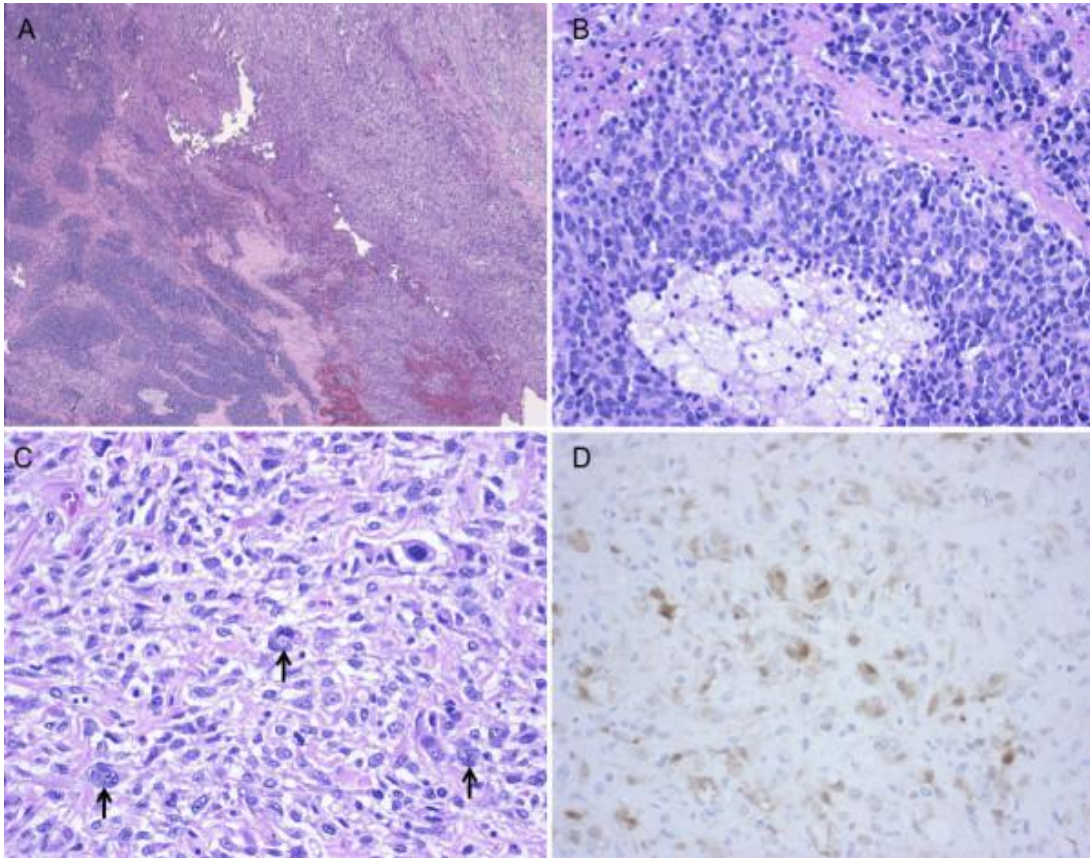
**Fig. 2. Radiological and microscopic findings of prostate cancer: A-B, Pelvic MRI showed an enlarged prostate invading the bladder (arrow) and a polypoid mass invading the rectum (arrowhead) (A, T1-weighted sagittal view; B, T2- weighted axial view). C, Gross examination of the resected specimen revealed an enlarged prostate invading the bladder (arrow) and polypoid mass invading the rectum (arrowhead) Reproduced from: Goto et al. World Journal of Surgical Oncology 2010; 8: 101 doi: 10.1186/1477-7819-8-101 © Goto et al; licensee Bio Med Central Ltd. This is an Open Access article distributed under the Creative Commons Attribution License (<http://creativecommons.org/licenses/by/2.0>), which permits unrestricted use, distribution and reproduction in any medium provided the original work is properly cited. The copy Right is permanently retained by Bio Med Central Ltd on behalf of the journal and the authors**

Huan et al. [24] reported two patients who had conventional adenocarcinoma of the prostate gland who then subsequently developed sarcomatoid carcinoma of the prostate gland six and two and half years following radiotherapy treatment (seed implant and external beam) for

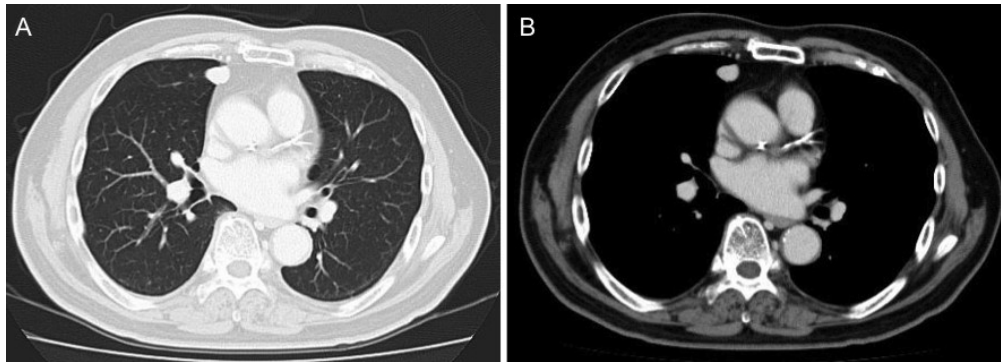
the original adenocarcinoma of prostate. They stated the following:

- Their cases had histological characteristics that were consistent with cases that were previously reported in the literature. The tumours were composed of

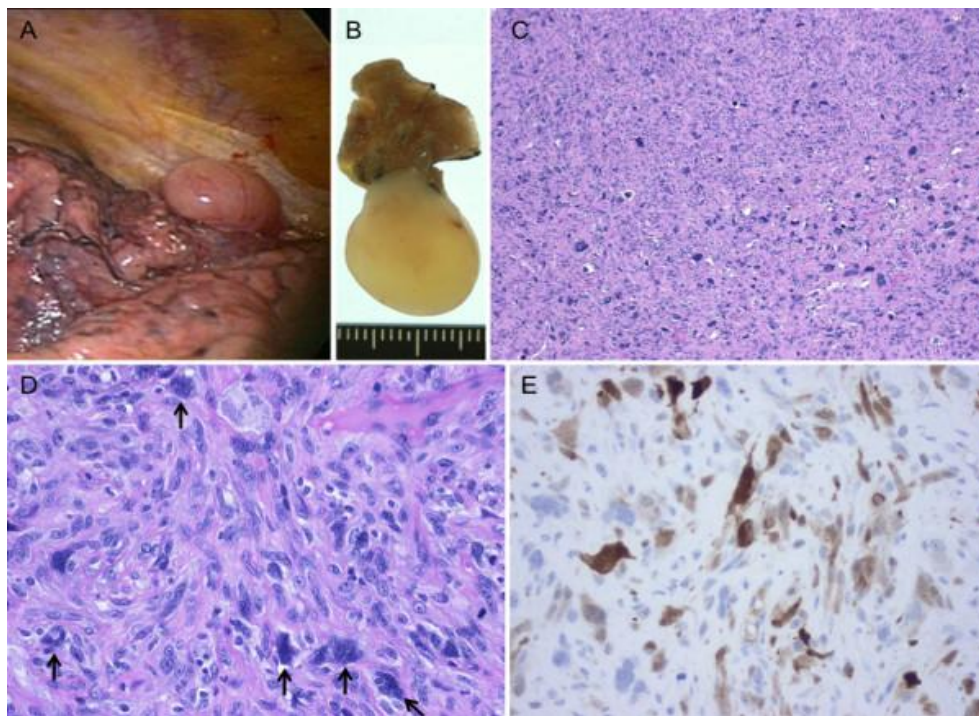
- spindle cells with large hyperchromatic nuclei and a pattern which resembled sarcoma.
- Immunohistochemical staining of the tumours had shown that the tumours were weakly positive for EMA, CK7, and vimentin. Ki67 staining had shown positive staining in more than 50% of the tumour cells. The tumours also did stain diffusely positive for p53 and p63. PSA and PAP were negative.
- Clinically, in their opinion, the sarcomatoid carcinomas had appeared to have originated from the prostate gland.
- The pathogenesis of the tumours was still uncertain; nevertheless, they most likely represented a radiotherapy-induced dedifferentiation of adenocarcinoma of the prostate gland.



**Fig. 3. Histological findings of prostate cancer: A, The tumor was composed of a poorly differentiated Gleason 4/5 adenocarcinoma (lower left of photograph) and an undifferentiated sarcomatoid carcinoma (upper right of photograph). B, The intraprostatic tumor showing a mixture of cribriform structures and necrosis C, The tumor in the area of posterior invasion Arrows indicate multinucleated giant cells. D, Cytokeratin AE1/3 immunostaining of the sarcomatoid carcinoma component** Reproduced from: Goto et al. *World Journal of Surgical Oncology* 2010; 8: 101 doi: 10.1186/1477-7819-8-101 © Goto et al.; licensee Bio Med Central Ltd. This is an Open Access article distributed under the Creative Commons Attribution License (<http://creativecommons.org/licenses/by/2.0>), which permits unrestricted use, distribution and reproduction in any medium provided the original work is properly cited. The copy Right is permanently retained by Bio Med Central Ltd on behalf of the journal and the authors



**Fig. 4.** CT findings of solitary pulmonary metastasis: A-B, after pelvic evisceration, Chest CT revealed a small nodular shadow (A, lung window image; B, mediastinal window image).  
Reproduced from: Goto et al. World Journal of Surgical Oncology 2010; 8: 101 doi: 10.1186/1477-7819-8-101 © Goto et al.; licensee Bio Med Central Ltd. This is an Open Access article distributed under the Creative Commons Attribution License (<http://creativecommons.org/licenses/by/2.0>), which permits unrestricted use, distribution and reproduction in any medium provided the original work is properly cited. The copy Right is permanently retained by Bio Med Central Ltd on behalf of the journal and the authors



**Fig. 5** Pulmonary metastasis of prostate cancer. A, Gross appearance during thoracoscopic surgery; B, Gross appearance of the resected specimen; C-D, Histology of the lung tumor Arrows indicate multinucleated giant cells; E, Cytokeratin AE1/3 immunostaining of the lung tumor. Reproduced from: Goto et al. World Journal of Surgical Oncology 2010; 8: 101 doi: 10.1186/1477-7819-8-101 © Goto et al; licensee Bio Med Central Ltd. This is an Open Access article distributed under the Creative Commons Attribution License (<http://creativecommons.org/licenses/by/2.0>), which permits unrestricted use, distribution and reproduction in any medium provided the original work is properly cited. The copy Right is permanently retained by Bio Med Central Ltd on behalf of the journal and the authors

There is no consensus opinion regarding the best treatment option; nevertheless, it would appear that early diagnosis and early aggressive surgical treatment in the form of radical prostatectomy or anterior pelvic exenteration and an adjunctive therapy using systemic chemotherapy might help improve prognosis. There are perhaps a large number of SCPs which are not detected because clinicians do not look for them considering the fact that a large number of patients who have been treated for adenocarcinoma of prostate by means of hormonal treatment or radiotherapy subsequent progression of disease and castrate resistant carcinoma of prostate following initial response to hormonal therapy. There is evidence to suggest that PSCP may develop following hormonal treatment as well as following radiotherapy for adenocarcinoma of prostate. It would be argued that a large number of patients who have developed castrate resistant prostate cancer following hormonal therapy and those who have developed progressive prostate cancer may have developed dedifferentiation into sarcomatoid carcinoma, angiosarcoma, small cell carcinoma admixed with adenocarcinoma but cannot be ascertained unless further biopsies are taken when a diagnosis of castrate resistant cancer is made or a diagnosis of progress of the carcinoma is made after radiotherapy. It would further be argued that if biopsies of prostate are undertaken for most patients who have developed castrate resistant carcinomas of prostate as well as those whose tumours have progressed after radiotherapy perhaps a large number of new carcinomas which had emanated from dedifferentiation would be diagnosed including sarcomatoid carcinoma of the prostate. In that case it would be argued that patients who are found to have developed PSCP following radiotherapy should be considered for chemotherapy plus or minus radical surgery if the patients are fit to undergo surgery. In order to confirm or negate these arguments a large scale multi-centre trial would be recommended to help decide on the best treatment options for PSCP and another trial to determine the proportion of patients who develop progressive disease or castrate resistant prostate carcinoma who have developed dedifferentiation into PSCP or any other variant of carcinoma of prostate.

## 6. CONCLUSIONS

PSCP is rare and may present with lower urinary tract symptoms and occasionally with perineal

pain and/or haematuria. PSCP may develop de novo or pursuant to previous radiotherapy to hormonal treatment or radiotherapy for adenocarcinoma of prostate. PSCP is an aggressive disease with the whole poor eventual outcome in majority of cases. Perhaps early diagnosis and early aggressive surgical treatment in the form of radical prostatectomy or anterior pelvic exenteration and an adjunctive therapy using systemic chemotherapy might help improve prognosis. Early re-biopsies of prostate in cases of progressed carcinomas of prostate following radiotherapy and of castrate resistant carcinomas may perhaps help diagnose many carcinomas that have dedifferentiated into other variants of prostate cancer which may also in deciding of the best options of further management. Clinicians should enter all cases of PSCP they encounter into a global large-scale multi-centre trial in order to determine the best treatment options for PSCP and to further study the biological behaviour of PSCP.

## CONSENT

Consent is not applicable. Copy Right permission was granted under the Creative Commons Attribution License by Case Reports in Urology, Bio Med Central LTD and World Journal of Surgical Oncology.

## ETHICAL APPROVAL

Ethical approval is not applicable in the situation of review of the literature. No experiment was undertaken.

## COMPETING INTERESTS

Author has declared that no competing interests exist.

## REFERENCES

1. Arora K. Prostate other carcinomas Carcinosarcoma. Pathology Outlines.com; 2012.
2. Açıköz O, Gazel E, Zengin E Z, Kasap Y, Çamtosun A, Yazıcıoğlu AH. Sarcomatoid carcinoma of the prostate. Case reports in Urology; 2013. Article ID 631809, 3 pages Available:<http://dx.doi.org/10.1155/2013/631809>
3. Hansel DE, Epstein JI. Sarcomatoid carcinoma of the prostate: A study of 42 cases. Am. J Surg Pathol. 2006;30(10): 1316–1321.

4. Adekoyejo Abiodun P, Adetola D, Charles A, Kehinde Habbeeb T, Martins M. Sarcomatoid carcinoma of prostate: A rare entity. *Journal of Case Reports*. 2014;4: 33–37. Available:<http://dx.doi.org/10.17659/01.2014.0009>
5. Wick MR, Young RH, Maivesta R, Beebe DS, Hansen JJ, Denner LP. Prostatic carcinosarcomas. Clinical, histologic, and immunohistochemical data on two cases, with a review of the literature. *Am J Clin Pathol*. 1989;92(2):131-139.
6. Zizi-Sermpetzoglou A, Savvaidou V, Tepelenis N, Galariotis N, Olympitis M, Stamatiou K. Sarcomatoid carcinoma of the prostate: A case report. *International Journal of Clinical and Experimental Pathology*. 2010;3(3):319–322.
7. Eble JN, Sauter G, Epstein JI, Sesterhenn IA. *Pathology and genetics of tumors of the urinary system and male genital organs*. IARC Press; 2004.
8. Grignon DJ. Unusual subtypes of prostate cancer. *Modern Pathology*. 2004;17(3): 316–327.
9. Lauwers GY, Schevchuk M, Armenakas N, Reuter VF. Carcinosarcoma of the prostate. *Am. J Surg Pathol*. 1993;17(4):342–349.
10. Diao R, Fok KL, Zhang Z, Zhao L, Mou L, Sun S, Zhou L, Cai Z. Concurrence of squamous cell carcinoma, sarcomatoid carcinoma and adenocarcinoma in relapsed prostate cancer originated from adenocarcinoma. *B. J. U. I*; 2013. Available:[www.bjui.org/ContentFullItem.aspx?](http://www.bjui.org/ContentFullItem.aspx?)
11. Nazim SM, Jalbani IK, Abbas F, Minhas K. Sarcomatoid carcinoma of prostate involving the whole lower urinary tract and rectum. *CASE Report*. 2013;5(4):283–286.
12. Kubosawa H, Matsuzaki O, Kondo Takao Sato N. Carcinosarcoma of the prostate. *Acta Patho Jpn*. 1993;43:209-214.
13. Quay SC, Proppe KH. Carcinosarcoma of the prostate: Case report and review of the literature. *J Urol*. 1981;125:436-438.
14. Mostofi FK, Price EB J. *Atlas of tumor pathology. Series 2, Fascicle 8* Washington DC. Armed Forces Institute of Pathology; Tumors of the male genital system. 1973;177–258.
15. Sak SD, Orhan D, Yaman O, Tulunay O, Ozdiler E. Carcinosarcoma of the prostate: A case report and a possible evidence on the role of hormonal therapy. *Urol. Int*. 1997;59:50–52.
16. Ray ME, Wojno KJ, Goldstein NS, Olson K NB, Shah RB, Cooney KA. Clonality of sarcomatous and carcinomatous elements in sarcomatoid carcinoma of the prostate. *Urology*. 2006;67:423 e8
17. Eble JN, Sauter Epstein JI. Sesterhenn IA, editors. Lyon, France. IARC Press. *The World Health Organization Classification of Tumors of the Urinary System and Male Genital Organs*. 2004;160:209–211.
18. Hansel DE, Herawi M, Montgomery E, Epstein JI. Spindle cell lesions of the adult prostate. *Mod Pathol*. 2007;20:148–158.
19. Subramanian VS, Coburn M, Miles EJ. Carcinosarcomas of the prostate with multiple metastases: Case report and review of the literature. *Urol. Oncol*. 2005; 23:181–183.
20. Dundore PA, Cheville JC, Nascimento AG, Farrow GM, Bostwick DG. Carcinosarcoma of the prostate: Report of 21 cases. *Cancer*. 1995;76:1035-1042.
21. Fukawa T, Numata K, Yamanaka M, Miyamoto T, Kurokawa Y, Kanayama H O, Kagawa S, Utsunomiya M, Hirokawa M. Prostatic carcinosarcoma: A case report and review of literature. *Int. J Urol*. 2003; 10(2):108–113.
22. Mazzucchelli R, Lopez-Beltran A, Cheng L, Scarpelli M, Kirkali Z, Montironi R. Rare and unusual histological variants of prostatic carcinoma: Clinical significance. *B. J. U. Int*. 2008;102:1369–1374.
23. Goto T, Maeshima A, Oyamada Y, Kato R. Solitary pulmonary metastasis from prostate sarcomatoid cancer. *World Journal of Surgical Oncology*. 2010;8:101 DOI: 10.1186/1477-7819-8-101
24. Huan Y, Idrees M, Gribetz MF, Unger RD. Sarcomatoid carcinoma after radiation treatment of prostatic adenocarcinoma. *Annals of Diagnostic Pathology*. 2008; 12(2):142–145.

© 2015 Venyo; This is an Open Access article distributed under the terms of the Creative Commons Attribution License (<http://creativecommons.org/licenses/by/4.0>), which permits unrestricted use, distribution, and reproduction in any medium, provided the original work is properly cited.

*Peer-review history:*  
The peer review history for this paper can be accessed here:  
<http://sciedomain.org/review-history/10682>