



Tooth Bleaching and Its Adverse Effects: A Review

Gauri Patil ^{a++*}, Amit Reche ^{a#} and Priyanka Paul ^{a†}

^a Sharad Pawar Dental College and Hospital, DMIHER (Deemed to Be), Sawangi (Meghe), Wardha-442001, Maharashtra, India.

Authors' contributions

This work was carried out in collaboration among all authors. All authors read and approved the final manuscript.

Article Information

DOI: 10.9734/JPRI/2022/v34i577257

Open Peer Review History:

This journal follows the Advanced Open Peer Review policy. Identity of the Reviewers, Editor(s) and additional Reviewers, peer review comments, different versions of the manuscript, comments of the editors, etc are available here: <https://www.sdiarticle5.com/review-history/94794>

Review Article

Received: 10/10/2022

Accepted: 16/12/2022

Published: 20/12/2022

ABSTRACT

The technique of lightening the shade of a person's teeth is known as tooth whitening or tooth bleaching. For a variety of reasons, teeth can become discoloured, and whitening is frequently the preferred solution. Nowadays aesthetics play a major role in today's lifestyle. One of the common procedures in cosmetic dentistry is bleaching of the tooth. There are many causes of tooth discolouration. According to the aetiology and localization it is divided into intrinsic and extrinsic causes. This review article tells us briefly about various aspects of tooth bleaching like causes of tooth discolouration, bleaching material and its mechanism, bleaching techniques and the adverse effect of bleaching. The walking bleach technique and in-office thermocatalytic bleach technique is non vital tooth bleaching techniques. Walking bleach method uses sodium perborate with distilled water while thermocatalytic bleaching uses hydrogen peroxide with heat. Extracoronary tooth bleaching techniques are in-office vital bleach technique and at-home vital bleach technique. There are number of adverse effects of tooth bleaching. Gingival irritation and tooth sensitivity are common side effects in vital tooth bleaching while root resorption, chemical burns is seen in non

⁺⁺ BDS Intern;

[#] Head of Department;

[†] Assistant Professor;

*Corresponding author: E-mail: patilgauri893@gmail.com;

vital bleach technique. Chemical burn can be avoided by application of petroleum jelly or Vaseline to gingiva and oral mucosa during bleaching. Gingival irritation is mainly seen in in-home vital bleach technique where the customized tray irritates the gingiva. This can be prevented by trimming the customized tray. Tooth sensitivity is also a common side effect of vital tooth bleaching.

Keywords: Tooth bleaching; bleaching techniques; adverse effects.

1. INTRODUCTION

Tooth discolouration is a common problem in various parts of the world [1-4]. The patients nowadays desire smiles that seem to be whiter and more beautiful. The media's description of people with flawless white teeth has influenced the general population. Anterior teeth play important role in aesthetics of an individual mainly the colour of teeth and smile. Tooth discolouration gives an unaesthetic appearance to an individual especially on anterior teeth. Bleaching of tooth improves aesthetics by reducing tooth discolouration.

There are various studies which state that tooth discolouration is a common problem in various individuals of world and there is increase demand for tooth whitening treatment [1-4].

A study was conducted in United Kingdom on 3215 subjects [1]. About 50 percentage of population considered themselves to have tooth discoloration. He also concluded that there is rise in demand for tooth whitening treatment and cosmetic dentistry. A study on the female population of Saudi Arabia, result stated that about 43.7percentage females had undergone tooth bleaching procedure and about 8.7 percent of females undergo bleaching procedure per year [2]. A study was conducted in city of Turkey at a dental school about 1014 individuals participated [3]. There were basic questions on demographic details along with questions regarding appearance of their tooth, dental treatment done on anterior, orthodontic treatment done on anterior teeth. The result stated that about 55.1% of the patients were not happy with the shade of their teeth, 29.9% had misaligned anterior teeth. The study also discovered that the most preferred dental treatment was bleaching of teeth in about 49 percent of cases. A study concluded that tooth discolouration is common in Chinese population and the people were not satisfied with colour of their tooth. This study used a colorimeter to measure the colour to upper

central incisors in 405 adults and teenagers of Chengdu, China [4].

The earliest report of whitening for discoloured and non-vital teeth dates back to the 19th century [5]. In the ninth annual meeting of American Society of Dental Surgeons the first bleaching agent approved and recommended was chlorinated lime [6]. Other chemicals used were oxalic acid, chlorine solution, sodium hypochlorite, sodium peroxide [7-12]. 25% hydrogen peroxide in 75% ether can be used as a mixture for whitening of the teeth [13,14]. Harlan first reported the use of hydrogen peroxide for bleaching of teeth in research article named "The Removal of Stains From the Teeth Caused by the Administration of Medicinal Agents and the Bleaching of Pulpless Teeth" in 1884 [15]. In 1981 Abbot suggested to use 30 percentage of hydrogen peroxide i.e. superoxol for whitening of the teeth [16]. To accelerate the bleaching process many authors suggested to used heat along with bleaching agents [17]. Heated solution of sodium perborate and superoxol was recommended for whitening of teeth by Prinz in 1924 [18].

Mainly the intrinsic colour and extrinsic stains influence the colour of the teeth [19,20]. Scattering and absorption properties of enamel and dentin play important role in intrinsic colour of the tooth [21,22]. Extrinsic stains are seen on tooth where there is less access to tooth brushing and abrasive action of toothpaste. These extrinsic stains are increased by habit like smoking, tannin rich food like red wine [23]. Extrinsic stains can be caused by occupational exposure to metallic salts or due to medicines containing metal salts [23]. There are various treatment modalities to treat tooth discolouration we can use whitening tooth pastes, stains can be removed by scaling and polishing, bleaching of teeth [24]. Various bleaching include agent are hydrogen peroxide, carbamide peroxide, sodium perborate, oxalic acid and chlorine solution [7-12]. There are organic and inorganic peroxides. Peroxides are powerful oxidizers and effective bleaching agent [25].

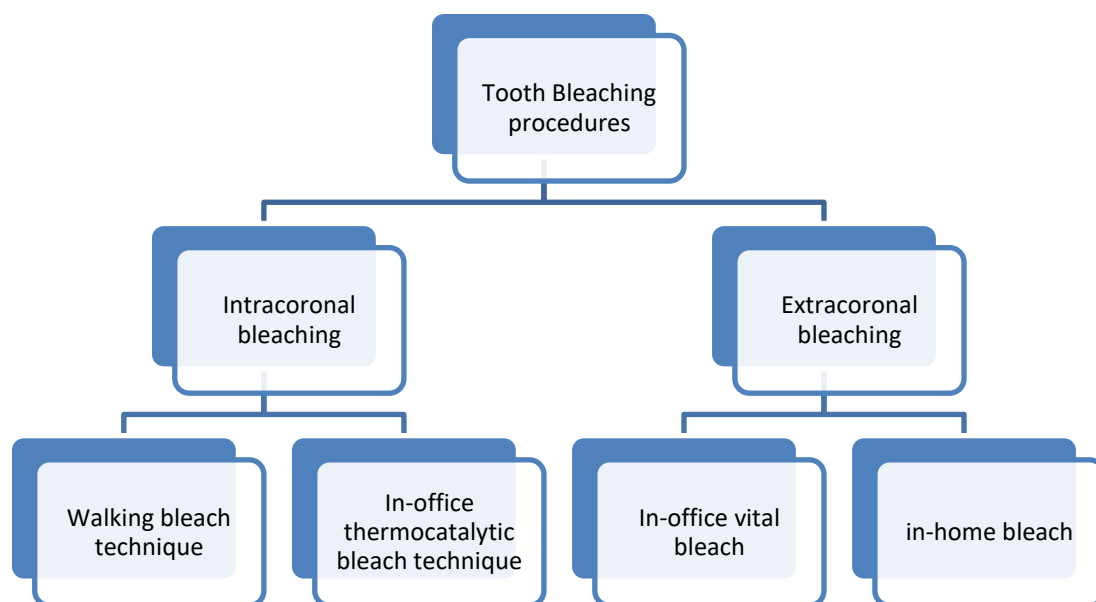


Fig. 1. Classification of bleaching techniques

Bleaching is divided into intracoronaral and extracoronaral bleaching. Intracoronaral bleaching is done on non vital teeth while extracoronaral bleaching is done on vital teeth. Thermocatalytic bleaching is a best intracoronaral bleaching technique which uses hydrogen peroxide and heat [26,27]. Extracoronaral bleaching uses a chemical on outer surface of tooth to remove discolouration from vital tooth. Fig. 1 tells us about the classification of various bleaching techniques.

There are certain disadvantages of using the bleaching agent in oral cavity. The main disadvantage of bleaching of vital tooth is sensitivity, gingival irritation. A study was conducted to assess the risk of using bleaching agents [28]. The result stated that 50.3 percentage of individuals experienced sensitivity after at-home bleaching and 39.3 percent after in office bleaching. While gingival irritation is seen in 14 percent of cases after in home bleaching and in office bleaching about 35.7 percentage individual suffered from gingival irritation. This review article gives a brief overview of bleaching of teeth which includes causes of tooth discolouration, various bleaching agent, and their mechanism of action, bleaching procedures and its adverse effects.

2. CAUSES OF TOOTH DISCOLOURATION

It is very important is to diagnose the causes of tooth discolouration as it will affect the treatment

modality. Therefore it's important for dentist to know about the aetiology of tooth discolouration for diagnosis and arriving at proper treatment plan [19]. The causes of tooth discolouration are divided into intrinsic, extrinsic or combination of the both causes [29].

2.1 Extrinsic Causes

The cause for intrinsic staining is the deposition of chromatogenic substance on the surface of external tooth surface. These chromatogenic substances are seen in tea, coffee, tobacco, oranges, carrots, licorice, chocolate [19,23,29]. It is also seen in tannin rich products like red wine. Metal salts in mouthwashes cause extrinsic discolouration of teeth. Dental plaque can also cause extrinsic staining. Nathoo et al in 1997 gave the classification for extrinsic tooth discolouration [23]. He has classified extrinsic tooth discolouration under three categories. These categories are N1 type, N2 type and N3 type. In N1 type the chromogens or the colour substance stick to tooth surface and causes discolouration but the stain is of the same colour as the chromogen. In N2 type, here there is change in chromogen colour after sticking to the tooth surface. The colourless prechromogens bind to external surface of tooth and a chemical reaction occur between tooth and prechromogens to form a stain. Extrinsic stains can be removed easily as they are found on tooth surface. Stronger the bonding of chromogens to tooth surface stronger is the extrinsic stain. Attractive forces include van der

waals force, electrostatic force, hydration forces, hydrophobic interactions, dipole-dipole forces and hydrogen forces [30]. These attractive forces strongly bind the chromogens to tooth. In a study it showed that with ageing the stains of tea and coffee are difficult to remove. The first classification of extrinsic stains was based on metallic and non-metallic stains [31]. This classification could not explain the mechanism of staining and tooth are not stained by all metals. Therefore there was a need for a newer classification which was given by Nathoo which was based on chemistry of staining.

2.2 Intrinsic Causes

2.2.1 Pulp necrosis

Irritation to dental pulp by microbial, chemical or mechanical stimulus which may leads to tooth necrosis. This releases toxic substances which penetrate dentinal tubules and causes discolouration of surface dentin leading to intrinsic staining of tooth. Discolouration is directly proportional to the time the discolouring agent stays on the tooth surface. Longer the discolouring agent stays in contact with tooth surface stronger is the discolouration [25,32].

2.2.2 Intrapulpal hemorrhage

Intrapulpal bleeding occurs due to severe and sudden trauma to tooth. This bleeding is caused by rupture of blood vessels. The blood component flows in the dentinal tubules which leads to discolouration [33]. First the tooth colour changes to pink then there is breakdown of red blood cells into heme and globulin. Then heme reacts with the putrefying pulpal tissue to form iron [19]. Then the iron converts hydrogen sulphate into iron sulphate. Iron sulphate stain the tooth in grey colour and get deposited deep in the dentinal tubules causing discolouration of teeth.

2.2.3 Coronal filling materials

Old composite restoration can cause discolouration of tooth due to microleakage. Amalgam restoration can lead to greyish discolouration of dentinal surface. When amalgam restoration are used in lingual access opening preparation in premolar or developmental grooves in anterior teeth in this amalgam can cause discolouration. This discolouration is difficult to manage as there is recurrence of discolouration in this. Sometimes amalgam restoration, the metal post gives darker

appearance to tooth due to transparency of enamel enamel. This can be also caused by release of metallic ions from restoration [25].

2.2.4 Root resorption

Root resorption is clinically has no symptoms but pinkish spot can be seen at cemento-enamel junction. This should be known to distinguish between discolouration and root resorption [19].

2.2.5 Dystrophic calcification

At the time of ageing there is deposition of secondary dentin which results in darkening of tooth surface. This is mainly due to the light transmitting properties of tooth [19].

3. BLEACHING AGENTS

Bleaching agents are used for whitening of the discoloured tooth. The first used bleaching agent is chlorinated lime [6]. Commonly use bleaching agents are hydrogen peroxide, carbamide peroxide and sodium perborate [7-12].

3.1 Hydrogen Peroxide

Hydrogen peroxide is an active substance in the bleaching agents. It is a colourless solution which is highly dissolving in water to give acid solution. It is used as a bleaching or whitening agent for tooth, balancing agent in wine preparation, disinfection of seeds and in treatment of water [34]. There are organic and inorganic peroxides. Peroxides are strong and powerful oxidizing agents and are considered as the by product of hydrogen peroxide. When hydrogen is replaced with metal it forms inorganic peroxide, when replaced with organic radical it forms organic peroxide [25]. At low concentration it is used as a bleaching agent. At higher concentration it is highly unstable and can explode if not kept at cooler temperature.

3.1.1 Mechanism of action

Hydrogen peroxide can penetrate the dentinal tubules as it has less molecular weight. Then it releases oxygen molecules that break the double bond of inorganic and organic substance present in dentinal tubules [35]. If along with hydrogen peroxide heat is used it will fasten the process [36].

3.2 Sodium Perborate

Sodium perborate is an effective whitening agent which is sold in powder form. It is highly stable in

powder. It is safe and easy to control bleaching agent [37].

3.2.1 Mechanism of action

Sodium perborate in powder form when react with water or acid it breaks into sodium perborate, hydrogen peroxide and nasant oxygen molecule. The nasant oxygen molecule breaks the double bond present in dentinal tubules and treats discolouration of tooth [37].

3.3 Carbamide Peroxide

Carbamide peroxide is a compound formed by urea and hydrogen peroxide. It is pure white in colour and is organic substance.it is called as urea hydrogen peroxide. In water it breaks into 3% hydrogen peroxide and 7% urea. It is used along with glycerine to make the substance more stable. The most common concentration of carbamide peroxide is 10 percentage. This 10 percent of carbamide peroxide is more effective than 0.2 percent chlorohexidine [38].

3.3.1 Mechanism of action

Carbamide peroxide is highly soluble in water. When reacts with water gives urea, ammonia, carbon dioxide and hydrogen peroxide. Hydrogen peroxide releases nasant oxygen and breaks the double bond in dentinal tubules [38].

4. BLEACHING PROCEDURES

Tooth bleaching procedures are divided into intracoronal and extracoronal bleaching.the intracoronal bleaching is also known as bleaching of endodontically treated tooth or non vital blwaching. The intracoronal bleaching is futher divided into walking blech technique and in office thermocatalytic blech technique. The extracoronal bleaching is the vital tooth bleaching. The extracoronal bleaching is divided into in-office vital bleach technique and in-home bleach technique [39]. Fig. 1 gives the classification of bleaching technique.

4.1 Intracoronal Bleaching Technique

4.1.1 Walking blech technique

Article regarding walking bleach technique was first given by Salvas et and al the technique uses sodium perborate along with distilled water [40]. Further nutting and poe used hydrogen peroxide instead of water to accelerate and increase the

effect of bleaching agent [41]. The combination of sodium perborate and distilled water is used even nowadays and is one of the most effective and successful procedure for intracoronal bleaching [37]. In a studies done by E A Aldecoa et al, he treated 534 discoloured teeth by tetracycline over a span of years and intracoronal bleaching was proved effective and successful 68.

4.1.1.1 Procedure [39]

Tooth is prepared for whitening procedures by cleaning it with prophylactic pastes to remove debris. Petroleum jelly is applied to gingival tissue and oral mucosa near the tooth to be bleached.To avoid direct contact to oral mucosa due to chemicals in bleaching agent. Apply rubber dam. Access opening is re-established. Root canal filling material is removed with plunger or gates glidden drill upto a level of alveolar bone. Rest of filling material is compressed at level 1 mm apical to cementoenamel junction which is confirmed by periodontal probe. Now seal the opening of root canal with 1 mm intracoronal barrier to avoid perforation of bleaching agent. Glass ionomer cement, resin modified glass ionomer cement and mineral triaggregate can be used as a barrier. It is important to seal the bleaching agent to crown itself and prevent its entry to area apical to level of bone as it causes cervical root resorption. Cover the patient's eyes and face with protective equipments and the operator should wear gloves. Sodium perborate and distilled water is mixed in thick paste. The thick mixture of sodium perborate and distilled water is carried to pulp chamber with a plastic instrument. The facial surface should be in contact with the thick paste for bleaching to be effective. A small cotton pellet containing hydrogen peroxide is placed over the mixture. Now seal the access opening with thick adhesive or temporary restoration about 3 mm in thickness. This will create a seal and prevent leakage of bleaching agent. The bleaching effect is seen in 24 hours after the procedure. Patient should return to dentist after a week for evaluation of the result.

4.1.2 In-office thermocatalytic bleach technique

In thermocatalytic bleaching heat is used along with the chemicals. This is the best technique to bleach non vital tooth due to strong interaction between hydrogen peroxide and heat [26]. Electric heating devices are used for heat

application. The additional heat application increases the whitening properties of hydrogen peroxide. Heat can also be applied by heated metallic instrument. The reaction releases more nasant oxygen when heat is applied [39].

4.1.2.1 Procedure

As discussed in the procedure of walking bleaching technique the same technique will be used that involves cleaning tooth with prophylactic procedure, applying Petroleum jelly, use of rubber dam, access opening is re-established and root canal filling material is compressed till the the level of cemento enamel junction. But in this technique it involves the use of 30-35 percent of hydrogen peroxide in pulp chamber which is followed by heat application. There is usually 5-6 minutes of exposure to tooth and solution is replenished frequently. Pellet of cotton containing hydrogen peroxide is placed in the pulp chamber and sealed with temporary restoration till next appointment.

In-office themocatylic bleaching method is very good when the walking bleach technique fails or when walking bleach technique doesn't give effective results even after 3-4 times application [42].

4.2 Extracoronral Bleaching Technique

4.2.1 In-office vital bleach technique

In this technique high concentration of hydrogen peroxide is used. The concentration of hydrogen peroxide is about 30-35%. In this procedure the dentist has full control over the procedure and can stop when the desired shade is achieved. Before the use of chemicals the surrounding gingiva and oral cavity should be covered by rubber dam. This can also be activated by heat for an hour in dental clinic [43].

4.2.1.1 Procedure [39]

Radiograph is taken to see the presence of decay, faulty restoration and the location of pulp horn.

The tooth shade is evaluated by shade guide and photos before and along the procedure. Vaseline is applied to gingival tissues surrounding to tooth to be bleached. Protective equipments are worn by patient and dentist, and rubber dam is applied. With the help of cotton hydrogen peroxide is applied to the labial surface of tooth.

Heat is applied by electric heating device. The temperature should be maintained at 52-60 degree Celsius. The time of treatment should not exceed more than half an hour even if treatment is not effective. The heating source is removed and teeth are allowed to cool down for 5 minutes. Then the teeth are cleaned thoroughly to remove the bleaching agent then the teeth are dried. Neutral sodium fluoride gel is used for 2-5 minutes. Patient is told used to fluoride rinse foe about 14 days.

4.2.2 In-home vital bleach technique

It uses less concentration of bleaching agent i.e. 10-20 percentage carbamide peroxides¹⁰. The concentration of 10 percent of carbamide peroxide is used for 8 hours per day while concentration of 15-20 percent is used for about 3-4 hours. The procedure is carried out by the patients but is done in supervision of dentist at the time of recall. A custom made mouth guard is fabricated by dentist and the bleaching solution is applied on it and is worn by patient at night for about 14 days [43].

4.2.2.1 Procedure [39]

At the first appointment maxillary and mandibular impression are taken by alginate. The base of caste should be trimmed for better adaptation.

Reservoirs can be placed on the labial surface of tooth for bleaching agent to be applied properly to the tooth surface. The reservoirs are made by wax and it should be 1 mm short of free gingival margin. Material used to fabricate the tray is thick semi rigid plastic material. The adaptation of the tray should be checked properly in the second appointment and should be trimmed if any problem. The patient is instructed to brush the teeth prior to use tray and patient is instructed to use sufficient amount bleaching agent to cover the labial surface of tooth. For every session the tray should be worn for about 4 hours. The patient should maintain proper and regular follow up with the dentist for evaluation of bleaching procedure.

5. ADVERSE EFFECTS OF BLEACHING

5.1 Adverse Effect of Intracoronral Bleaching

5.1.1 External root resorption

External root resorption is one of the disadvantage of intracoronral bleaching. Four

cases of root resorption were reported after intracoronal bleaching procedure with heat by Harrington and Natkin where the pulp was devital [44]. More such cases are reported by Lado et al which also developed cervical root resorption followed after intracoronal bleaching procedure [45].

5.1.2 Chemical bur

Chemicals used in the bleaching procedures are caustic in nature and can cause chemical burn. The chemical burn is caused when there is interaction of chemicals with gingiva or oral mucosa surrounding tooth to be bleached. To prevent this petroleum jelly is used [39].

5.1.3 Inhibition of resin polymerization

The nasant oxygen liberated after the bleaching procedure affects the bonding and polymerisation of composite resin [39].

5.2 Adverse Effect of Extracoronal Bleaching

5.2.1 Tooth sensitivity

Tooth sensitivity is the most common side effect of extracoronal bleaching. The tooth sensitivity after vital tooth bleaching is seen in about 50 percent of cases [46]. The tooth sensitivity occurs after the procedure and is persistent for about 2-3 days. Mainly the sensitivity is maximum on the third day as the pulp has maximum saturation of oxygen [47]. Tooth sensitivity does not depend on the patients age, sex, faulty restoration while it depends on patient who change the bleaching agent more than once a day.

5.2.2 Enamel damage

Extracoronal bleaching can cause damage to enamel. Damage is caused by erosive action of bleaching agent. The enamel is made weak by extracoronal bleaching technique mainly due to three reasons. The first reason include mineral loss as the ratio of organic and inorganic changes. The second reason includes change in enamel surface morphology and the third reason is alteration of enamel micro hardness, many in vitro studies are done on enamel [48,49].

5.2.3 Gingival irritation

Gingival irritation is the most common side effect of extracoronal bleaching procedure. Gingival

irritation can occur with or without tooth sensitivity often patient has difficulty in distinguishing both. In in-home vital bleaching technique, gingival irritation can take place due poorly fitting or ill fitting trays but this can be corrected by trimming the tray [50]. In in-office bleaching technique, gingival irritation takes due to faulty gingival barrier protection [43,51].

5.2.4 Effect on restoration

In the teeth with amalgam restoration extracoronal bleaching is difficult to perform as there is release of mercury from the amalgam restoration [52,53]. Mercury with many disadvantage on health so it is advised to avoid bleaching on amalgam restoration. Studies state that bleaching affects the chemical and physical properties of restorative material like its strength the bound to tooth structures, marginal leakage, and release of ions.

6. CONCLUSION

Tooth Bleaching is a procedure to lighten the shade of the tooth. Nowadays people of world are focusing more on aesthetics and there is growing demand for tooth bleaching procedures. There are number of aetiology's for tooth discolouration which are divided into intrinsic and extrinsic causes. Intrinsic causes are mainly microbial cause, trauma to tooth, non vital tooth. Extrinsic causes are due to tea, coffee, wine, tobacco. Bleaching agents are hydrogen peroxide, carbamide peroxide and sodium perbarate. The bleaching procedures are vital tooth bleaching procedure and non vital bleaching procedures. There are various adverse effects of tooth bleaching like gingival irritation, tooth sensitivity, cervical root resorption, damage to enamel, damage to restorative materials, chemical burns.

CONSENT

It is not applicable.

ETHICAL APPROVAL

It is not applicable.

COMPETING INTERESTS

Authors have declared that no competing interests exist.

REFERENCES

1. Alkhatib MN, Holt R, Bedi R. Prevalence of self-assessed tooth discolouration in the United Kingdom. *J Dent [Internet]*. 2004; 32(7):561–6.
DOI:10.1016/j.jdent.2004.06.002
2. Jaha HS, Alhejoury HA, Fayad AA, Alnafisah AM, Bahshan IA, Assiri SI, et al. Knowledge, practices, and perceptions about tooth whitening among female population in Saudi Arabia - A cross-sectional study. *J Pharm Bioallied Sci [Internet]*. 2021;13(Suppl 1):S817–20.
DOI: 10.4103/jpbs.JPBS_769_20
3. Akarslan ZZ, Sadik B, Erten H, Karabulut E. Dental esthetic satisfaction, received and desired dental treatments for improvement of esthetics. *Indian J Dent Res [Internet]*. 2009;20(2):195–200.
DOI: 10.4103/0970-9290.52902
4. Xiao J, Zhou XD, Zhu WC, Zhang B, Li JY, Xu X. The prevalence of tooth discolouration and the self-satisfaction with tooth colour in a Chinese urban population. *J Oral Rehabil [Internet]*. 2007;34(5): 351–60.
DOI: 10.1111/j.1365-2842.2007.01729.x
5. Truman J. Bleaching of non-vital discoloured anterior teeth. *Dent Times*. 1864;1:69-72.
6. Dwinelle WW. Ninth annual meeting of American Society of Dental Surgeons: Article X. *Am J Dent Sc*. 1850;1:57–61.
Available:https://www.ncbi.nlm.nih.gov/pmc/articles/PMC6059622/
7. Atkinson CB. Bleaching teeth, when discolored from loss of vitality: Means for preventing their discoloration and ulceration. *Dental Cosmos*. 1862;3: 74–7.
8. Bogue EA. Bleaching teeth. *Dental Cosmos*. 1872;141-3.
9. Taft J. Bleaching teeth. *Am J Dent Sci*. 1878/1879;12:364.
10. Atkinson CB. Hints and queries. *Dental Cosmos* 1879;21:471.
11. Messing JJ. Bleaching. *J Br Endod Soc*. 1971;5:84–5.
Available:https://doi.org/10.1111/j.1365-2591.1971.tb00057.x
12. Kirk EC. Hints, queries, and comments: sodium peroxide. *Dental Cosmos*. 1893;35:1265-7.
13. Dietz VH. The bleaching of discolored teeth. *Dent Clin North Am*. 1957;1: 897–902.
14. Atkinson CB. Fancies and some facts. *Dental Cosmos* 1892;34:968–72.
Available:https://quod.lib.umich.edu/d/dencos/ACF8385.0034.001/980:348?rgn=main;view=image
15. Harlan AW. The removal of stains from teeth caused by administration of medical agents and the bleaching of pulpless tooth. *Am J Dent Sci*. 1884/1885;18:521.
Available:https://www.ncbi.nlm.nih.gov/pmc/articles/PMC6904009/pdf/dentreg130092-0037.pdf
16. Abbot CH. Bleaching discoloured teeth by means of 30 per cent perhydrol and the electric light rays. *J Allied Dent Society*. 1918;13:259.
17. Andreasen FM. Transient apical breakdown and its relation to color and sensibility changes after luxation injuries to teeth. *Dental Traumatology*. 1986;2(1): 9-19.
DOI: 10.1111/j.1600-9657.1986.tb00118.x
18. Prinz H. Recent improvements in tooth bleaching. *Dent Cosmos*. 1924;66(5): 558-60.
19. Watts AM, Addy M. Tooth discolouration and staining: A review of the literature. *British dental journal*. 2001;190(6).
DOI: 10.1038/sj.bdj.4800959
20. Joiner A. Tooth colour: a review of the literature. *Journal of dentistry*. 2004;32:3-12.
DOI: 10.1016/j.jdent.2003.10.013
21. Ten Bosch JJ, Coops JC. Tooth color and reflectance as related to light scattering and enamel hardness. *Journal of dental research*. 1995;74(1):374-80.
DOI: 10.1177/00220345950740011401
22. Muia PJ. The four dimensional tooth color system. Quintessence Publishing (IL); 1982.
Available:https://pubmed.ncbi.nlm.nih.gov/6337388/
23. Nathoo SA. The chemistry and mechanisms of extrinsic and intrinsic discoloration. *The Journal of the American Dental Association*. 1997;128:6S-10S.
DOI: 10.14219/jada.archive.1997.0428
24. Joiner A, Pickles MJ, Matheson JR, Weader E, Noblet L, Huntington E. Whitening toothpastes: effects on tooth stain and enamel. *International dental journal*. 2002;52:424-30.
Available:https://doi.org/10.1111/j.1875-595X.2002.tb00732.x
25. Rotstein I, Li YI. Tooth discoloration and bleaching. *Endodontics*. 5th ed. Hamilton,

- Ontario, Canada: BC Decker Inc. 2002; 845-60.
26. Grossman L. Root canal therapy. Philadelphia: Lea and Febiger; 1943. DOI: 10.4236/ojst.2013.35048
 27. Marin PD, Bartold PM, Heithersay GS. Tooth discoloration by blood: an in vitro histochemical study. *Dental Traumatology*. 1997;13(3):132-8. DOI: 10.1111/j.1600-9657.1997.tb00026.x
 28. Bruzell EM, Pallesen U, Thoresen NR, Wallman C, Dahl JE. Side effects of external tooth bleaching: A multi-centre practice-based prospective study. *British Dental Journal*. 2013;215(9):E17. DOI: 10.1038/sj.bdj.2013.1047
 29. Hattab FN, Qudeimat MA, AL-RIMAWI HS. Dental discoloration: An overview. *Journal of Esthetic and Restorative Dentistry*. 1999;11(6):291-310. DOI: 10.1111/j.1708-8240.1999.tb00413.x
 30. Scannapieco FA, Levine MJ. Saliva and dental pellicles. *Contemporary periodontics*. 1990;1:117-25.
 31. Gorlin RJ, Goldman HM. Environmental pathology of the teeth. In: Thoma's oral pathology. 6th ed. St Louis: Mosby; 1970.
 32. Attin T, Paque F, Ajam F, Lennon AM. Review of the current status of tooth whitening with the walking bleach technique. *International Endodontic Journal*. 2003;36(5):313-29. DOI: 10.1046/j.1365-2591.2003.00667.x
 33. Arens D. The role of bleaching in esthetics. *Dental Clinics of North America*. 1989;33(2):319-36. Available: <https://pubmed.ncbi.nlm.nih.gov/2721797/>
 34. Hydrogen peroxide. IARC Monogr Eval Carcinog Risks Hum. 1999;71:671-689. Available: https://publications.iarc.fr/_publications/media/download/2309/9f15d671c4186d7755411e49c5ed690efb249129.pdf
 35. Seghi RR, Denry I. Effects of external bleaching on indentation and abrasion characteristics of human enamel in vitro. *Journal of Dental Research*. 1992; 71(6):1340-4. DOI: 10.1177/00220345920710061201
 36. Hardman PK, Moore DL, Petteway GH. Stability of hydrogen peroxide as a bleaching agent. *General Dentistry*. 1985;33(2):121-2. Available: <https://pubmed.ncbi.nlm.nih.gov/3858201/>
 37. Rotstein I, Mor C, Friedman S. Prognosis of intracoronal bleaching with sodium perborate preparations in vitro: 1-year study. *Journal of Endodontics*. 1993; 19(1):10-2. DOI: 10.1016/s0099-2399(06)81033-2
 38. Gurgan SE, Bolay S, Alacam R. Antibacterial activity of 10% carbamide peroxide bleaching agents. *Journal of endodontics*. 1996;22(7):356-7. DOI: 10.1016/S0099-2399(96)80217-2
 39. Gutmann J. Grossman's endodontic practice - 13th edition. *J Conserv Dent [Internet]*. 2016;19(5):494. Available: <https://www.jcd.org.in/text.asp?2016/19/5/494/190011>
 40. Salvias JC. Perborate as a bleaching agent. *JADA*. 1938;25:324-6.
 41. Nutting EB. A new combination for bleaching teeth. *J South Calif Dent Assoc*. 1963;31:289-91.
 42. Baratieri LN, Ritter AV, Monteiro Jr S, Caldeira de Andrada MA, Cardoso Vieira LC. Nonvital tooth bleaching: guidelines for the clinician. *Quintessence International*. 1995;26(9). Available: <https://pubmed.ncbi.nlm.nih.gov/8602439/>
 43. Sulieman M, Addy M, Macdonald E, Rees JS. The bleaching depth of a 35% hydrogen peroxide based in-office product: a study in vitro. *Journal of Dentistry*. 2005;33(1):33-40. DOI: 10.1016/j.jdent.2004.07.008
 44. Harrington GW, Natkin E. External resorption associated with bleaching of pulpless teeth. *Journal of Endodontics*. 1979;5(11):344-8. DOI: 10.1016/S0099-2399(79)80091-6
 45. Lado EA, Stanley HR, Weisman MI. Cervical resorption in bleached teeth. *Oral Surg*. 1983;55:78-80. DOI: 10.1016/0030-4220(83)90310-9
 46. Leonard Jr RH, Haywood VB, Phillips C. Risk factors for developing tooth sensitivity and gingival irritation associated with nightguard vital bleaching. *Quintessence International*. 1997;28(8). Available: <https://pubmed.ncbi.nlm.nih.gov/9477880/>
 47. Matis BA, Mousa HN, Cochran MA, Eckert GJ. Clinical evaluation of bleaching agents of different concentrations. *Quintessence international*. 2000;31(5). Available: <https://pubmed.ncbi.nlm.nih.gov/11203940/>
 48. Haywood VB, Leonard RH, Dickinson GL. Efficacy of six months of nightguard vital bleaching of tetracycline-stained teeth.

- Journal of Esthetic and Restorative Dentistry. 1997;9(1):13-9.
DOI: 10.1111/j.1708-8240.1997.tb00910.x
49. Bitter NC. A scanning electron microscope study of the long-term effect of bleaching agents on the enamel surface *In vivo*. General Dentistry. 1998;46(1): 84-8.
Available: <https://pubmed.ncbi.nlm.nih.gov/9667168/>
50. Kugel G, Aboushala A, Zhou X, Gerlach RW. Daily use of whitening strips on tetracycline-stained teeth: comparative results after 2 months. COMPENDIUM-NEWTOWN-. 2002;23(1A):29-34.
Available: <https://pubmed.ncbi.nlm.nih.gov/11913291/>
51. Sulieman M. An overview of bleaching techniques: 3. In-surgery or power bleaching. Dental update. 2005 Mar 2;32(2):101-8.
DOI: 10.12968/denu.2005.32.2.101
52. Attin T, Hannig C, Wiegand A, Attin R. Effect of bleaching on restorative materials and restorations—a systematic review. Dental Materials. 2004 ;20(9):852-61.
DOI: 10.1016/j.dental.2004.04.002
53. Swift Jr EJ, Perdigao J. Effects of bleaching on teeth and restorations. Compendium of continuing education in dentistry (Jamesburg, NJ: 1995). 1998;19(8):815-20.
Available: <https://pubmed.ncbi.nlm.nih.gov/9918105/>

© 2022 Patil et al.; This is an Open Access article distributed under the terms of the Creative Commons Attribution License (<http://creativecommons.org/licenses/by/4.0>), which permits unrestricted use, distribution, and reproduction in any medium, provided the original work is properly cited.

Peer-review history:

The peer review history for this paper can be accessed here:

<https://www.sdiarticle5.com/review-history/94794>