

Granulomatous Mastitis Masquerading as Breast Neoplasms- An Enigmatic Series of 14 Cases

MEGHADIPA MANDAL¹, ANADI ROY CHOWDHURY²

ABSTRACT

Granulomatous Mastitis (GM) is a rare entity encountered in day-to-day practice. Aetiologies range from infections like tuberculosis, lactation, certain medications to being idiopathic. Clinical and radiological pictures in these cases often mimic breast carcinoma that poses diagnostic dilemmas to the treating physician. However, sometimes they may be asymptomatic. Definitive diagnosis is made using cytology followed by histomorphology by demonstration of granulomas, which are collections of histiocytes along with giant cells and inflammatory cells. Ancillary studies like Ziehl-neelsen (ZN) stain, Periodic Acid Schiff (PAS) stain, Cartridge Based Nucleic Acid Amplification Test (CBNAAT) are used to detect or rule out certain aetiologies of granulomatous inflammation. Idiopathic Granulomatous Mastitis (IGM) is mainly a diagnosis of exclusion, where all the possible aetiologies have been ruled out by detailed history and investigations. Treatment approaches are mainly conservative, depending on the cause or may be anti-inflammatory and steroids in case of IGM. Appropriate and timed diagnosis of such cases is essential to prevent over diagnosis of carcinoma and unnecessary mastectomies. This is a series of 14 such cases which were diagnosed using cytology or histology and ancillary tools. They belonged to four categories (namely-Tuberculous mastitis, IGM, Post-chemotherapy GM and sarcoid granuloma of breast). Tuberculous cases shared majority of the series, whereas, sarcoid granuloma was a single isolated entity. All these cases presented with lump in breast with other associated presentations. Immediate tissue diagnosis helped in ruling out malignancy and adopting a conservative approach for management.

Keywords: Adjuvant chemotherapy, Idiopathic granulomatous mastitis, Sarcoidosis, Tuberculosis

INTRODUCTION

The granulomatous mastitis is an uncommon group of chronic inflammatory breast disorders [1] that can mimic breast neoplasms or infectious mastitis, both clinically and radiologically [2]. The aetiopathogenesis is vastly idiopathic with possible roles of trauma, hormonal effect, metabolic process, previous therapy-related changes or even infections [3], tuberculosis being an important aetiology behind this entity in Indian subcontinent. There additionally seems to be geographic and ethnic variance in the prevalence, where Caucasian and African American population appear to be less affected. Some unidentified infectious trigger or genetic predisposition may be the reason behind this diversity [4]. Local autoimmune disease, involving humoral and cell-mediated immunity appears to be another interesting proposed pathogenic mechanism behind this entity [5]. There is lack of any consensus on management in the literature due to rarity of this condition [6].

The symptoms of GM tend to overlap with more malicious entities, particularly breast carcinoma. However, it may also be asymptomatic [7]. GM cases usually presents with lump with or without the features of inflammation. Associated axillary lymphadenopathy may further increase the clinical suspicion of a neoplastic process, especially in the setting of older age group. Discharging sinuses or abscess formation may be occasionally seen in tubercular cases [8]. IGM cases also typically presents with unilateral or bilateral tender firm breast masses along with erythema, pain, and drainage, despite not being associated with any infective or neoplastic process [9]. All the GM cases were studied for total duration of six months with respect to their clinical presentation, demographic characteristics and ancillary investigations in support of their diagnosis. The findings are demonstrated in this paper.

CASE SERIES

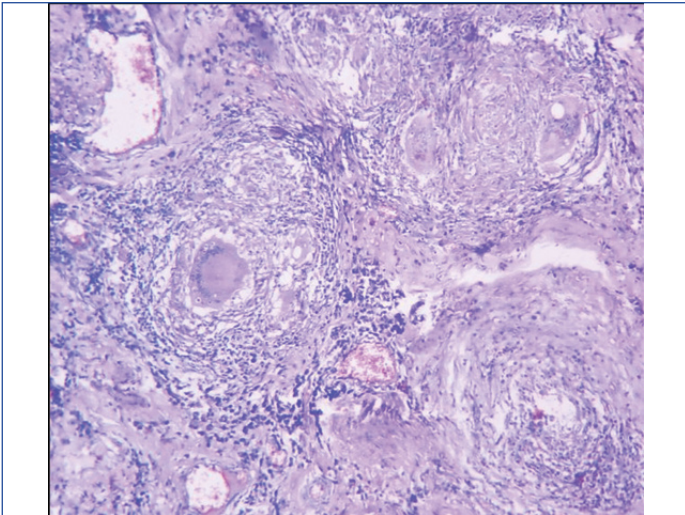
All the histomorphologically and cytologically proven cases of GM cases during the period of 6 months (March, 2022-August, 2022)

were included in this series. Total number of such cases was 14. They were analysed based on their age of presentation, presenting complaints, clinical findings and significant past history (with respect to any Anti-tubercular Therapy, adjuvant chemo/radiotherapy, etc.). Ancillary studies like Ziehl-neelsen stain, CBNAAT, etc., were carried out to confirm certain aetiologies.

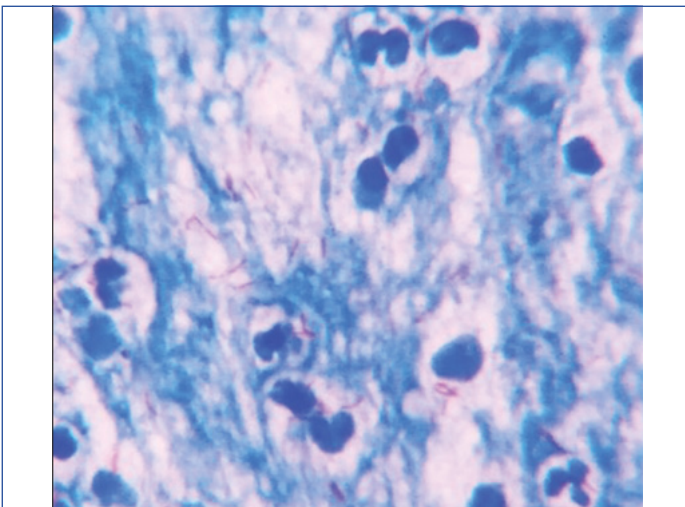
Tuberculous mastitis: This accounted for a total number of 8 cases. These included women of child-bearing age to post-menopausal age group. They had varied clinical presentation, lump being the most common one, present in all eight cases. Systemic symptoms like fever, weight loss were present in 6 cases. Two cases had nipple discharge as well. Clinically, peau d' orange change over the skin was seen in 2 cases of elderly population, giving a false impression of malignancy. Four cases had a past history of Anti-tubercular Drug (ATD) intake for pulmonary tuberculosis, more than five years back. Ultrasound examination of the breast masses were scored as Breast Imaging Reporting and Data System (BI-RADS) 2 & 3 in 6 cases, whereas BI-RADS 4 in 2 cases.

All these cases showed well-defined epithelioid granulomas along with Langhans giant cells either in histology sections [Table/Fig-1] or cytology smears. Definite caseation necrosis was also present in few cases. Three cases showed Acid Fast Bacilli (AFB) in ZN stain [Table/Fig-2] whereas, 5 cases showed positive CBNAAT results. All these cases on follow-up for six months showed signs of remission after starting ATDs.

Idiopathic Granulomatous Mastitis (IGM): This was diagnosed in three cases of the series. Their ages were 26 years, 38 years and 41 years, respectively. All of them presented with painless lump in breast. On palpation, the lump was firm, immobile with no axillary lymphadenopathy. There was history of lactation in one case and Oral Contraceptive Pill (OCP) intake in two cases. Ultrasonography (USG) examination showed Breast Imaging Reporting and Database System 3 (BI-RADS) in two cases and BI-RADS 4 in one case.

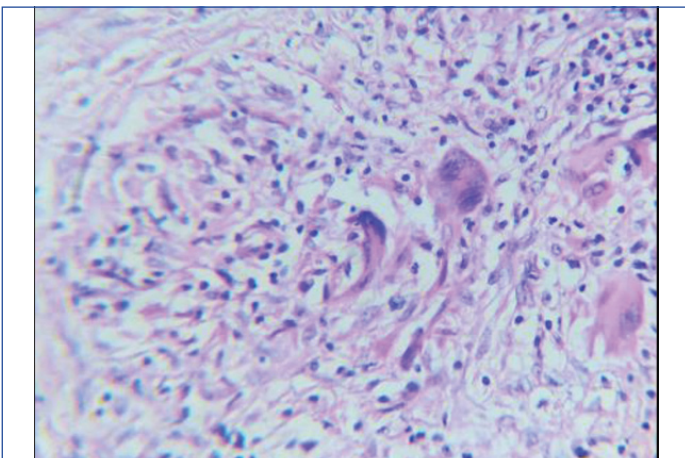


[Table/Fig-1]: Epithelioid granuloma with classical Langhans giant cell in tuberculous mastitis (H&E, 100x magnification).



[Table/Fig-2]: Acid Fast Bacilli (AFB) in ZN stained smear in Tuberculous mastitis (1000x magnification).

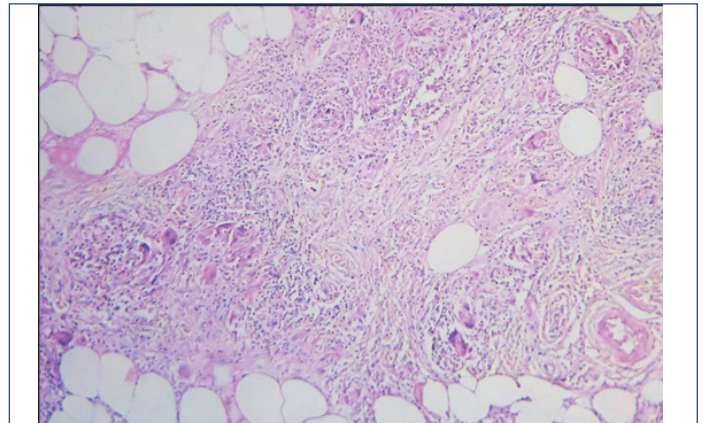
Cytology smears showed non caseating granulomas with foreign body giant cells in two cases, whereas, there were few atypical epithelial cells in the elderly patient. The latter was followed by tru-cut biopsy that showed granulomatous inflammation with foreign body giant cell reaction [Table/Fig-3]. No necrosis or malignancy was visualised in the sections. Ancillary investigations like ZN stain, CBNAAT turned out negative. PAS stain was also done, but failed to demonstrate any fungal bodies. No definite aetiology was identified in these cases. All these cases were treated with anti-inflammatory drugs and corticosteroids and on follow-up for six months, showed partial remission of symptoms.



[Table/Fig-3]: Foreign body granuloma in Idiopathic Granulomatous Mastitis (IGM) (H&E, 400x magnification).

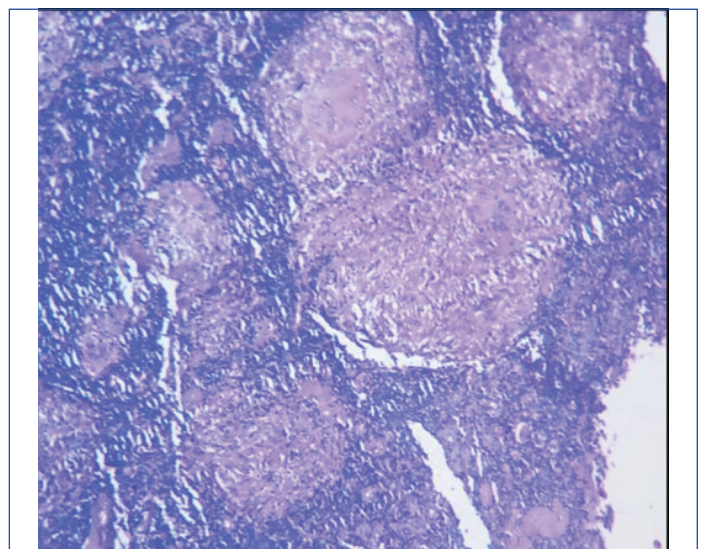
Post-chemotherapy Granulomatous Mastitis (GM): This was seen in two cases aged 48 years and 56 years, respectively. Both had breast conservation surgeries followed by chemotherapy and presently complained with lump in the breast. There was clinical suspicion of recurrence of malignancy and hence, tru-cut biopsy was performed. Breast imaging studies were not available for these cases.

One case revealed suture granuloma. Another case showed post-chemotherapy changes like fibrosis, histiocytes, inflammatory cells and ill-defined granulomas [Table/Fig-4]. There was no atypical/malignant cells visualised in both the cases. Both the cases on six months follow-up were doing well with no evidence of recurrence.



[Table/Fig-4]: Ill-defined granuloma, giant cells along with post-chemotherapy changes like fibrosis and inflammation (H&E, 100x magnification).

Sarcoid granuloma: There was a single case of sarcoidosis of breast in a 35-year-old female patient. She presented with firm lump in breast along with unilateral axillary lymphadenopathy. USG showed a BI-RADS score of 3. Cytology as well as histopathology from the breast lump showed classical non caseating granulomas. Similar picture was also seen in enlarged axillary nodes [Table/Fig-5]. Ancillary investigations like ZN stain, CBNAAT, PAS stain turned out negative. With the suspicion of sarcoidosis in mind, detailed history revealed long standing cough with fatigue and weight loss for last 8-9 months. Plain chest X-ray turned out normal, whereas focal reticulo-nodular opacities were seen in CT scan. In the two months follow-up, the patient was currently being treated with corticosteroids, showing signs of response. The following table summarises the above findings [Table/Fig-6].



[Table/Fig-5]: Classical non caseating granuloma in axillary lymph node in Sarcoidosis (H&E, 100x magnification).

DISCUSSION

The granulomatous mastitis is a rare non neoplastic entity of uncertain incidence [10]. It has been estimated that between 0.44 and 1.6% of all breast biopsy specimens are reported as GM

Diagnosis	Number of cases with frequency (%)	Age range of patients (yrs.)	Presenting complaints with frequency of occurrence (%)	Significant past history	BI-RADS scoring in USG	Cyto/histological findings	Ancillary investigations	Follow-up
Tuberculous mastitis	8 (57.2%)	20-62	Lump-100% (8 cases) Fever, weight loss-75% (6 cases) Nipple discharge-25% (2 cases) Skin changes (peau d' orange)-25% (2 cases)	History of ATD intake-50% cases	BI=RADS 2,3 (6 cases) BI-RADS 4 (2 cases)	Well-defined epithelioid granulomas, langhans giant cells, caseation necrosis	AFB found-37.5% (3 cases) CBNAAT detection-62.5% (5 cases)	Remission after ATD intake
Idiopathic Granulomatous Mastitis (IGM)	3 (21.4%)	26-41	Firm painless immobile lump, no axillary lymphadenopathy	Lactation history-33.3% OCP intake-66.7%	BI-RADS 3 (2 cases) BI-RADS 4 (1 case)	Granuloma with foreign body giant cell reaction Degenerative atypia in cytology smear in 1 case	CBNAAT & ZN stain- negative	On anti-inflammatory drugs and steroids
Post-chemotherapy granulomatous mastitis	2 (14.3%)	48-56	Lump in breast	Breast conservation surgery followed by chemotherapy for breast carcinoma	N/A	Suture granuloma Ill-defined granuloma with post-chemotherapy changes (fibrosis, histiocytes, inflammation)	Not required	Doing well for 6 months of follow-up
Sarcoidosis of breast	1 (7.1%)	35	Firm breast lump with axillary lymphadenopathy	Dry cough, fatigue, weight loss for 8-9 months	BI-RADS 3	Non caseating granulomas in breast and axillary lymph node	CBNAAT & ZN stain- negative	Response with corticosteroids

[Table/Fig-6]: Distribution of cases with respect to age, presenting complaints, past history, cytological and histological findings, imaging findings, ancillary investigations and follow-up (n=14).

[11]. The aetiopathogenesis of GM may remain unknown with no identifiable causative factor or may have an autoimmune reaction to mammary duct protein secretions secondary to trauma, infection or chemical irritation [12]. Tuberculous mastitis, although rare, may contribute to a significant proportion of cases in endemic areas [13], as was seen in this series. Breastfeeding, smoking, and use of the OCP have also been reported to be correlated with GM [14,15]. These associations, i.e., lactation and OCP intake were also seen in this study population.

Although, rare, the reporting pathologist and treating physician must be well versed with this entity as they mimic neoplasm as was seen in all the patients in this case series, that presented with breast lump. Skin changes like peau d' orange appearance or axillary lymphadenopathy are less common presentations [16] seen in some tuberculous or sarcoid aetiologies in this series. Systemic symptoms such as fever, chills, and fatigue are unusual [17], as was limited to tuberculous mastitis amongst this study population. In a relatively large series of 25 patients, the mean age at presentation was found to be 36.5 years, mainly pertaining to child-bearing age group [18]. However, in this series, the age ranges varied depending on the cause of granulomatous reaction in breast. The mean age of this series was 44 years (range: 20-62 years).

Imaging in the form of USG study was available in 6 out of 8 cases and BI-RADS scoring were given. Three cases (50%) were suspicious of malignancy with a BI-RADS 4, whereas 3 (50%) were BI-RADS 2 & 3 (Benign and possibly benign respectively). Such radiologic overlap with breast carcinoma has also been demonstrated in other study populations [19]. The diagnosis was based on cytology and/or histology with formation of granulomas with associated features depending on cause of the inflammatory process. Biopsy is the gold standard in making a diagnosis in these cases. Ancillary tests like ZN stain, CBNAAT, PAS stains were performed to confirm tuberculous or fungal aetiologies, as well as, to exclude these causative factors to make a diagnosis of IGM. It is mainly a diagnosis of exclusion as was followed in other case series as well [20]. Granulomatous reaction following breast conserving surgeries and adjuvant therapy in cancer survivors is rare with few case series depicting the same [21]. This was seen in two cases of this study population that initially raised concern amongst the clinician with suspicion of recurrence/relapse of malignancy.

Tuberculosis is a chronic granulomatous inflammation, with *Mycobacterium tuberculosis* as its main causative agent. It is one of the most widespread human infections in the world with re-emergence in developed countries due to increase in Human Immunodeficiency Virus (HIV) infections and increasing immigrations [13]. Breast tissue has natural resistance to multiplication of tubercle bacilli, thereby making breast involvement a rare entity even in endemic countries [22]. The clinical and imaging characteristics are vastly non specific, combined with lack of familiarity of the clinicians that have increased rates of misdiagnosis of these cases as breast cancers or pyogenic breast abscess [23]. The pauci-bacillary nature of these cases further complicates the diagnosis [24]. Tuberculous mastitis can be secondary to primary infection elsewhere or direct inoculation of bacilli via lactiferous ducts or even through direct extension from chest wall. The clinical presentation of tuberculous mastitis spans around a wide spectrum of solitary or multiple breast masses, abscesses, sinus tracts, skin ulcers, or skin thickening some of which are seen in this series like breast mass, peau d' orange-like skin changes, as has already been discussed before. Timely and accurate diagnosis of tuberculous mastitis cases require physician's knowledge about these varied presentations and hence, raise a clinical suspicion [13]. Core biopsy followed by histopathology is the gold standard for confirming or ruling out the diagnosis, especially in endemic zones [25]. IGM is yet another mysterious illness with its first report in 1972 by Kessler E and Wolloch Y [26]. With a reported incidence of 2.4 cases per 100,000 women aged 20-40 years in the US [27], it is predominantly seen to affect women of childbearing age, with rare instances in men and elderly women [28]. There are multi-factorial propositions behind its pathogenesis, as has already been discussed, none of which has been conclusively proven. Like Tuberculous mastitis, similarity to the clinical presentation of breast cancer, along with inconclusive imaging modalities often lead to misdiagnosis as cancer, delayed diagnosis and misguided therapies [29]. Adequate knowledge and awareness amongst the physician will be helpful as these are diagnosed only based on high degrees of suspicion and after exclusion of all possible causes of granulomatous inflammation in breast.

Post-chemotherapy GM is a very rare entity with only few supporting case series and reports available in literature as already discussed previously. This is extremely important from treatment point of view, as recurrence of breast cancer is the first most important differential that needs to be ruled out [21], that will lead to paradigm

shift in therapeutic management of these cases. However, post-treatment malignancy rate is low, recorded to be as low as 6.1% in follow-up in a study by Laws A et al., [30]. Thus, histopathological confirmation of such cases may prevent unnecessary surgeries in many cases.

Sarcoidosis is originally described as idiopathic systemic inflammatory granulomatous disorder comprising epithelioid and multinucleated giant cells with little or no necrosis. It is multisystemic with common involvement of lungs with fibrosis, along with lymph nodes, skin, liver, spleen, eyes, phalangeal bones, parotid glands and very rarely breast [31]. When such breast lumps are found, they are clinically suspected as breast malignancy due to associated axillary lymphadenopathy, in a set up of sarcoidosis. This case of the series was unique as breast lump was the initial presenting complaint with subsequent investigations, further detailed history

and ancillary studies helped in making a diagnosis of Sarcoidosis. Although rare, but sarcoidosis should also be considered as one differential in granulomatous inflammation of breast, where it can either be primarily or secondarily involved [32].

All these cases were treated depending on their diagnosis. There is no definite treatment protocol for IGM, the therapeutic arsenal varying from broad spectrum antibiotics usually associated with corticosteroid therapy to shrink the mass before a lumpectomy to a radical mastectomy is planned depending on the severity and extension of the lesions and the efficiency of medical treatment [33]. Corticosteroids were sufficient in this study population with patients showing signs of remission and recovery in follow-up period. A more comprehensive literature review in the last five years was made and the findings have been tabulated [Table/Fig-7] [5,9,13,21,34-39].

S. No.	Authors	Year of Publication	Total no. of cases	Age of patients	Presenting features	Aetiology	Histopathology	Treatment	Follow-up
1.	Nguyen MH et al., [34]	2021	1	Young, parous, lactating women	tender, erythematous breast lesions	immune-mediated, lipophilic Corynebacterium species	non caseating granulomata and an inflammatory cell infiltrate	multidisciplinary approach	-
2.	Ringsted S et al., [9]	2021	28	young-middle aged, with recent pregnancy or breastfeeding	Painful, erythematous lump, with discharge in few cases, inflammatory arthritis and erythema nodosum in few	Corynebacterium and tubercle bacilli positive in few cases	biopsy showing non caseating granulomas	Treatment for active tuberculosis, steroids, methotrexate	Few cases showed relapse
3.	Mathew Thomas V et al., [35]	2020	2	young-middle aged	Painful breast lump, erythema with axillary lymphadenopathy	Corynebacterium kroppenstedtii growth in one case	lymphocytic infiltration and non caseating granulomas in cytology smears	Steroids in one case, doxycycline in another	Recurrence seen
4.	Deng JQ et al., [5]	2017	65	Average age 31.2 years (19-48)	Inflammatory mass, firm-to hard lump in few cases	local autoimmune disease, involving humoral and cell-mediated immunity, hyperprolactinaemia	non caseating granulomas in biopsy, IHC-CD3, CD4, CD8, CD79a lymphocytes diffusely distributed in the lesion. Stains for IgG, IgM-negative.	Corticosteroids with/without surgical removal of breast lesion	Recurrences in few cases
5.	Wang J et al., [36]	2021	200	20-50 years	Breast lump with skin rupture	Auto-immune	non caseating granuloma, inflammatory cell infiltrate	Corticosteroids with/ without surgical therapy	Recurrence, post-surgical wound complications
6.	Farrokh D et al., [13]	2019	32	Young-middle aged, with recent history of pregnancy or lactation	Solitary/multiple breast mass, skin ulcer, sinus tracts, and nipple discharge	Tuberculous (positive smears, tuberculosis culture, TB PCR)	Granulomas with caseation necrosis	Anti-tubercular therapy	-
7.	Ichinose Y et al., [21]	2021	3	Older women	Lump at the site of previous surgical scar, often with erythema	Previous surgical incision	Xanthogranulomatous lesion with cystic changes and dense sclerosis, calcification, necrosis	Follow-up, tumorectomy	Resolution
8.	Li J [37]	2019	75	Young to middle-aged parous women	Breast lump (with/without pain), nipple retraction, sinus formation, axillary lymphadenopathy	Idiopathic	Non caseating granulomas	lumpectomy, abscess drainage or mastectomy. Follow-up with post-operative antibiotics.	Resolution
9.	Shin YD et al., [38]	2017	34	Reproductive age, with history of lactation, OCP, smoking, etc.	Painful mass, erythema, fistula formation, discharge	AFB, TB-PCR-negative. Methicillin-resistant Staphylococcus aureus-cultured in one case	Noncaseating scattered granulomas composed of epithelioid histiocytes, giant cell, lymphocytes, neutrophils, plasma cells, eosinophils.	antibiotic therapy incision and drainage Steroids wide excision	Partial to complete response
10.	Alrayes A et al., [39]	2019	29	Young to middle aged	Inflamed breast mass	Unknown	Demonstration of granulomas	surgical excision with debridement and removal of retroareolar ductal system	No recurrence in follow-up period

[Table/Fig-7]: Table showing summary of the findings of studies in the last 5 years [5,9,13,21,34-39].

CONCLUSION(S)

The GM is a rare but benign and non neoplastic entity among all cases of breast biopsy specimens with lack of awareness and paucity of literature in this field. However, it must be properly diagnosed to avoid unnecessary mastectomies, due to a greater clinical and radiologic overlap with malignant lesions of breast. Certain ancillary investigations are helpful to confirm/exclude certain causative factors for the same. Although definite and standardised therapeutic norms are not available, corticosteroids have shown promising results in a large number of cases.

Acknowledgement

I would sincerely like to thank all the co-authors for their intellectual contributions towards completion of this paper. They have not produced this work in any form on any other platform and have committed to the submission of this case series for publication in this journal.

REFERENCES

- [1] Afridi SP, Memon A, Shafiq-ur-Rahman, Memon A. Granulomatous mastitis: A case series. *J Coll Physicians Surg Pak*. 2010;20(10):706.
- [2] Ahmed R, Sultan F. Granulomatous mastitis: a review of 14 cases. *J Ayub Med Coll Abbottabad*. 2006;18(1):52-54.
- [3] Wolfrum A, Kummel S, Theuerkauf I, Pelz E, Reinisch M. Granulomatous mastitis: A therapeutic and diagnostic challenge. *Breast Care (Basel)*. 2018;13(6):413-18.
- [4] Davis J, Cocco D, Matz S, Hsu CH, Brown MJ, Lee J, et al. Re-evaluating if observation continues to be the best management of idiopathic granulomatous mastitis. *Surgery*. 2019;166(6):1176-80.
- [5] Deng JQ, Yu L, Yang Y. Steroids administered after vacuum-assisted biopsy in the management of idiopathic granulomatous mastitis. *J Clin Pathol*. 2017;70(10):827-31.
- [6] Freeman M, Lewis CD, Lower E. Refractory granulomas of breast: benign or malignant disease. *J Clin Oncol*. 2014;32(suppl):21.
- [7] Severs FJ, Guevara L, Sam KQ, Roark A, Benveniste AP, Ebuoma L. Granulomatous Mastitis of the Breast: A Malicious Mimic. *Journal of Diagnostic Medical Sonography*. 2018;34(3):223-28.
- [8] Jalali U, Rasul S, Khan A, Baig N, Khan A, Akhter R. Tuberculous mastitis. *J Coll Physicians Surg Pak*. 2005;15(4):234-37.
- [9] Ringsted S, Friedman M. A rheumatologic approach to granulomatous mastitis: A case series and review of the literature. *Int J Rheum Dis*. 2021;24(4):526-32.
- [10] Babahabib A, Arsalane A, Aitefaddi F, Chahdi H. Granulomatous mastitis-a case report. *Integr J Med Sci*. 2018;5(r):01-03.
- [11] Elsididg KE, Khalil EA, Elhag IA. Granulomatous mammary disease: ten years' experience with needle aspiration cytology. *Int. J. Tuberc. Lung Dis*. 2003;7(4):365-69.
- [12] Benson JR, Dumitru D. Idiopathic granulomatous mastitis: presentation, investigation and management. *Future Oncol*. 2016;12(11):1381-94.
- [13] Farrokh D, Alamdaran A, FeyziLaeen A, FallahRastegar Y, Abbasi B. Tuberculous mastitis: A review of 32 cases. *Int J Infect Dis*. 2019;87:135-42.
- [14] Barreto DS, Sedgwick EL, Nagi CS, Benveniste AP. Granulomatous mastitis: etiology, imaging, pathology, treatment, and clinical findings. *Breast Cancer Res Treat*. 2018;171(3):527-34.
- [15] Bani-Hani KE1, Yaghan RJ, Mataalka II, Shatnawi NJ. Idiopathic granulomatous mastitis: time to avoid unnecessary mastectomies. *Breast J*. 2004;10(4):318-22.
- [16] SamKQ, Severs FJ, EbuomaLO, Chandandeeep NS, SedgwickEL. Granulomatous mastitis in a transgender patient. *J Radiol Case Rep*. 2017;11(2):16-22.
- [17] Al-Khawari HA, Al-Manfouhi HA, Madda JP. Radiologic features of granulomatous mastitis. *Breast J*. 2011;17(6):645-50.
- [18] Azlina AF, Ariza Z, Arni T, Hisham AN. Chronic granulomatous mastitis: diagnostic and therapeutic considerations. *World J Surg*. 2003; 27:515-18.
- [19] Sripathi S, Ayachit A, Bala A, Kadavigere R, Kumar S. Idiopathic granulomatous mastitis: A diagnostic dilemma for the breast radiologist. *Insights Imaging*. 2016;7(4):523-29.
- [20] Varshochi M, Haghdooost M, Mashrabi O. Idiopathic granulomatous mastitis: a case report. *Am J Infect Dis*. 2010;6(3):61-65.
- [21] Ichinose Y, Kosaka Y, Saeki T. Granuloma after breast conserving surgery-a report of three cases. *J Surg Case Rep*. 2021;2021(6):01-04.
- [22] Gon S, Bhattacharyya A, Majumdar B, Kundu S. Tubercular mastitis-a great masquerader. *Turk Patoloji Derg*. 2013;29:61-63.
- [23] Madhusudhan KS, Gamanagatti S. Primary breast tuberculosis masquerading as carcinoma. *Singapore Med J*. 2008;49:e3-e5.
- [24] Domingo C, Ruiz J, Roig J, Texido A, Aguilar X, Morera J. Tuberculosis of the breast: a rare modern disease. *Tubercle*. 1990;71:221-23.
- [25] Banerjee SN, Ananthkrishnan N, Mehta RB, Parkash S. Tuberculous mastitis: a continuing problem. *World J Surg*. 1987;11:105-09.
- [26] Kessler E, Wolloch Y. Granulomatous mastitis: a lesion clinically simulating carcinoma. *Am J Clin Pathol*. 1972;58(6):642-46.
- [27] Centers for Disease Control and Prevention (CDC). Idiopathic granulomatous mastitis in Hispanic women-Indiana, 2006-2008. *MMWR Morb Mortal Wkly Rep*. 2009;58(47):1317-21.
- [28] Gautier N, Lalonde L, Tran-Thanh D, El Khoury M, David J, Labelle M, et al. Chronic granulomatous mastitis: Imaging, pathology and management. *Eur J Radiol*. 2013;82(4):e165-75.
- [29] Erhan Y, Veral A, Kara E, et al. A clinicopathologic study of a rare clinical entity mimicking breast carcinoma: idiopathic granulomatous mastitis. *Breast*. 2000;9(1):52-56.
- [30] Laws A, Xu Y, Kong S, Brisson AM, Bouchard-Fortier A, Quan ML. Breast biopsy during post-treatment surveillance of screen-detected breast cancer patients yields high rates of benign findings. *Ann Surg Oncol*. 2020;27:2689-97.
- [31] Fiorucci F, Conti V, Lucantoni G. Sarcoidosis of the breast: a rare case report and a review. *Eur Rev Med Pharmacol Sci*. 2006;10(2):47-50.
- [32] Panzacchi R, Gallo C, Fois F. Primary sarcoidosis of the breast: case description and review of the literature. *Pathologica*. 2010;102(3):104-07.
- [33] Imoto S, Kitaya T, Kodama T, Hasebe T, Mukai K. Idiopathic granulomatous mastitis: case report and review of the literature. *Jpn J Clin Oncol*. 1997;27:274-77.
- [34] NguyenMH, MollandJG, Kennedy S, Gray TJ, Limaye S. Idiopathic granulomatous mastitis: case series and clinical review. *Intern Med J*. 2021;51(11):1791-97.
- [35] Mathew Thomas V, Alexander S, Bindal P. Idiopathic granulomatous mastitis-a mystery yet to be unraveled: a case series and review of literature. *Cureus*. 2020;12(2):e6895.
- [36] Wang J, Zhang Y, Lu X. Idiopathic granulomatous mastitis with skin rupture: a retrospective cohort study of 200 patients who underwent surgical and nonsurgical treatment. *J Invest Surg*. 2021;34(7):810-15.
- [37] Li J. Diagnosis and treatment of 75 patients with idiopathic lobular granulomatous mastitis. *J Invest Surg*. 2019;32(5):414-20.
- [38] Shin YD, Park SS, Song YJ, Son SM, Choi YJ. Is surgical excision necessary for the treatment of Granulomatous lobular mastitis? *BMC Womens Health*. 2017;17(1):49.
- [39] Irayes A, Almarzooq R, Abdulla HA. Surgical treatment of granulomatous mastitis: Our experience in Bahrain. *Breast J*. 2019;25(5):958-62.

PARTICULARS OF CONTRIBUTORS:

1. Senior Resident, Department of Pathology, Jhargram Government Medical College and Hospital, Jhargram, West Bengal, India.
2. Professor and Head, Department of Pathology, Murshidabad Medical College and Hospital, Berhampore, West Bengal, India.

NAME, ADDRESS, E-MAIL ID OF THE CORRESPONDING AUTHOR:

Meghadipa Mandal,
AC1, AA1, Farsight Housing Coopsoclimited, New Town,
Rajarhat, North 24 Parganas, Kolkata-700156, West Bengal, India.
E-mail: meghadipa.mandal41@gmail.com

PLAGIARISM CHECKING METHODS: [Jain H et al.]

- Plagiarism X-checker: Nov 28, 2022
- Manual Googling: Dec 15, 2022
- iThenticate Software: Jan 21, 2023 (6%)

ETYMOLOGY: Author Origin

AUTHOR DECLARATION:

- Financial or Other Competing Interests: None
- Was informed consent obtained from the subjects involved in the study? Yes
- For any images presented appropriate consent has been obtained from the subjects. Yes

Date of Submission: **Nov 21, 2022**

Date of Peer Review: **Jan 06, 2023**

Date of Acceptance: **Jan 23, 2023**

Date of Publishing: **Apr 01, 2023**