



Injection Snoreplasty-a Simple Way to Treat Habitual Snoring

**Bakshi Jaimanti^{1*}, Gupta K. Ashok¹, Dash K. Anil¹
and Khandelwal Gaurav¹**

¹*Department of Otolaryngology and HNS PGIMER, Postgraduate Institute of Medical Education & Research, Chandigarh, India.*

Authors' contributions

This work was carried out in collaboration between all authors. Author BJ designed the study and did all the procedures herself on all patients. She collected the data for this study and followed up all patients after treatment. Author GKA helped in designing the study. Author KG, helped in writing the manuscript and in statistical analysis of the data. Author DKA, helped in data collection. All authors read and approved the final manuscript.

Original Research Article

Received 18th November 2013
Accepted 2nd June 2014
Published 3rd July 2014

ABSTRACT

Aims: Injection snoreplasty was recently introduced as a safe, effective, and minimally invasive treatment for primary snoring. We assess the effectiveness of the treatment in our patients.

Study Design: It was a prospective, non-randomised study on 54 patients with primary snoring.

Place and Duration of Study: Study was done in the department of otolaryngology & head neck surgery at PGIMER, Chandigarh, India over 7 years between January 2004 and December 2010.

Methodology: Patients were questioned about their symptoms; a detailed clinical and radiological examination was done in all patients. All the causes of snoring were ruled out. 1-3% sodium tetradecyl sulphate (STS) injection was administered in all patients in 1-3 sittings. Patients were assessed after 1, 3 and 6 months and their improvement was noted

Results: There were 47 males and 7 females enrolled in our study with mean age as 47.6 years. The mean duration of snoring was 76.1 months. The average BMI of patients was 28.11. All the patients except 4 were initially injected 1% STS injection;

*Corresponding author: Email: drjayabakshi@ymail.com;

the others were injected 3%. 11 patients were re-injected at 1 month and 4 had 2nd re-injection at 3 month follow up. The mean improvement in symptoms was 57.24%. The only side effect was pain which in majority of patients was mild. There was no correlation between BMI and percentage of improvement.

Conclusion: Injection snoreplasty is a safe and cost effective treatment for primary snoring.

Keywords: Injection snoreplasty; snoring; sodium tetradecyl sulphate.

1. INTRODUCTION

Snoring is a common problem, affecting 20% of the general population and 60% of men aged older than 40 years [1]. It generally results from the narrowing and partial obstruction of the upper airway during sleep due to unfavorable positioning of the uvula, soft palate, and tongue. Because snoring is so common, treatment modalities continue to evolve to meet this demand, with emphasis on developing simple, effective, and less invasive procedures that are well tolerated by the patient. Treatments include weight loss, exercise programs, smoking cessation, nasal and oral appliances, and dietary changes. All of these methods depend on patient compliance.

Surgical treatments for snoring are varied and controversial. Uvulopalatopharyngoplasty (UPPP), laser-assisted uvulopalatopharyngoplasty (LAUP), radiofrequency ablation (RFA), [2] cauterly-assisted palatal stiffening operation (CAPSO), [3] and injection snoreplasty (IS) are the most accepted techniques. LAUP [4] was introduced as an alternative to UPPP [5] since it can be performed with local anesthesia in an office setting. However it has lost popularity because it is more painful than other more recently developed procedures, usually needs multiple visits, and requires expensive equipment. In addition, long-term success rates are reported to be under 50% [6]. Thus it seems logical to perform minimally invasive procedures.

There are many causes for snoring. Simple snoring can occur due to deviated nasal septum, mass in nasopharynx or in the nasal cavities, excessive palatal flutter and bulky base of tongue. Among all these, palatal flutter is the most common cause for snoring in habitual snorers. It occurs due to large, floppy soft palate or bulky and elongated uvula. It is logical that patients with palatal flutter would benefit from palatal surgery, whereas those with tongue base or other types of snoring would not benefit.

Injection snoreplasty, first introduced by Brietzke et al. in 2001 [7], has been well received with increasing popularity as a primary treatment for palatal snoring because of its comparative advantages over other snoring procedures. Its primary objective is to stiffen the soft palate to reduce palatal flutter which causes snoring. STS is a sclerosing agent and causes fibrosis at the site of injection into soft palate. Fibrosis leads to stiffening and reduced vibration of the palate thus reducing the snoring. It is very simple to perform during a routine clinic visit, is minimally painful and inexpensive. The procedure was initially presented using the well-described sclerotherapy agent sodium tetradecyl sulfate (STS) as the palatal sclerosing agent [7]. This agent was selected because of its excellent safety record and established efficacy over several decades in the literature. We assess the efficacy of STS in our patients.

2. MATERIALS AND METHODS

This prospective, nonrandomized human use pilot study was first approved by our local institutional review board before any patient enrollment.

Fifty four patients were enrolled in the study in the department of Otolaryngology & Head Neck surgery at PGIMER, Chandigarh, India between 2004 and 2010. A detailed informed consent was taken from all the patients. Patients as well as their spouses were questioned and a detailed history was obtained. Patients were specifically questioned about any symptoms suggestive of sleep apnea, morning headaches, irritability, decreased concentration span and day time somnolence. This is relevant because all these features are seen in patients with obstructive sleep apnea which may not improve after injection snoreplasty. Snoring was graded using the VAS scale from 1-3 as mild, moderate and severe snoring. Objective measurement of the snoring sound in decibels was not done as it was not feasible. A detailed clinical examination was done in all the patients. Flexible nasopharyngoscopy and laryngoscopy was done to visualize the nasopharynx, oropharynx and the larynx and the site of obstruction was inferred. Radiological examination included X-ray PNS water's view, X-ray skull lateral view, and X-ray soft tissue neck lateral view and X-ray chest PA view. All enrolled patients underwent an overnight sleep study confirming the diagnosis of primary snoring with a respiratory disturbance index (RDI) of less than 10. Exclusion criteria included tonsillar hypertrophy on physical examination (defined as greater than 1+), a known history of co-morbid disease that could alter routine healing patterns (eg, vascular disease, diabetes mellitus, significant periodontal disease, etc), or a history of prior surgical snoring treatments.

All the patients who were habitual snorers were included in the study. The patients had palatal flutter on nasopharyngoscopy during simulated snoring and had obstruction at palatal level. This was the inclusion criteria and was mandatory for case enrollment. Other exclusion criteria included patients having sleep apnea syndrome; diabetics; age above 70 years; multiple levels of obstruction; primary bulky tongue and allergy to STS.

One ml of 1-3% sodium tetradecyl sulphate (STS) injection was administered in all patients in 1-3 sittings after giving topical anesthesia using 10% xylocaine spray. 1% STS was used for primary injection and 3% STS was used for re-injections. 1% STS is recommended for primary injection and cures snoring in habitual snorers. 3% STS should be injected in failed cases as they require more stiffening of the soft palate to cure snoring. First injection is indicated when patient comes to us with diagnosis of habitual snoring. Patient is re-assessed at 4 weeks after first injection to see the response to STS. If there is significant reduction in snoring, no further injection is required. But if patient still complains of snoring as before the treatment, re-injection is indicated. The site of injection was at the root of uvula in midline as shown in (Fig. 1). Site for re-injection, which was done after 4 weeks of the first injection, was paramedian in the soft palate. Re-injection in soft palate should be done at paramedian site as the first injection would cause stiffening in the median part (Fig. 3.). 1ml insulin syringe was used to administer the sclerosant. Patients were only given pain killers for 1-3 days. Patients were assessed at 1, 3 and 6 months after treatment. All 54 patients were followed up at all time periods. Snoring improvement was noted subjectively using Visual Analogue scale (VAS) and objectively using Sleep study. It showed the improvement in apnea-hypopnea index and oxygen saturation after injection snoreplasty. Degree of pain was also graded as no pain, mild, moderate and severe on visual analogue scale (VAS). All procedures were done by the principal

investigator with total duration of 20 minutes. Mean and standard deviation method and Pearson's correlation co-efficient tests were used for statistical analysis.

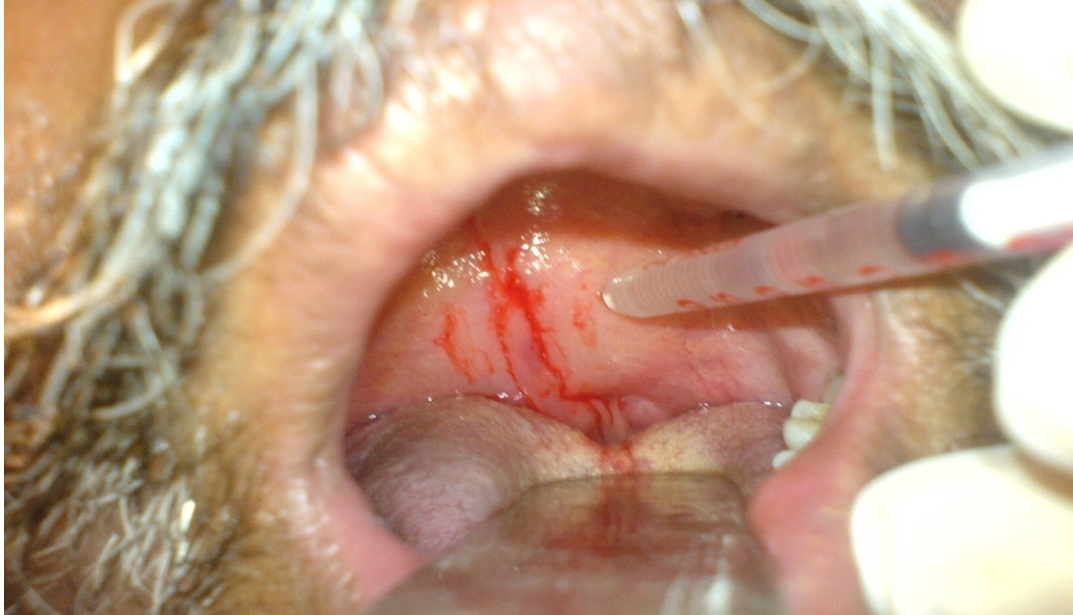

Fig. 1. Showing injection into soft palate with 1% sodium tetra decyl sulphate

3. RESULTS

There were 47 males and 7 females enrolled in our study with mean age of 47.6 years. The mean duration of snoring was 76.1 months. All had undergone a previous overnight sleep study confirming the diagnosis of primary snoring. (RDI<10 events/hour). The RDI ranged from 0 to 10 with a mean of 2.6 events per hour. The average BMI of patients was 28.11 kg/m². The additional symptomatology of snorers included morning headache in 27 cases, irritability in 3, decreased concentration span in 10 and day time somnolence in 14 cases.

Twenty one patients had moderate snoring while the rest had severe snoring. All the patients were initially injected with 1% STS injection; 21 patients were re-injected at 1 month and 4 had 2nd re-injection at 3 months follow up. The first few days after injection, patients developed mucosal necrosis followed by sloughing as shown in (Fig. 2). This was then followed by fibrosis which led to palatal stiffening. Fig. 3 shows the sites for primary injection and re-injection in the soft palate. The average follow up of patients was 12.2 months (ranged from 3 months to 3 years). The mean improvement in symptoms was 57.24% (ranged from 10% to 90%) with standard deviation of +/- 17.96% (Fig. 4).

The main side effect was pain (severity is given in Table 1). Some patients developed difficulty in swallowing which lasted few days, maximum of 7 days; 3 patients developed severe mucosal ulceration which did not require any intervention. No other side effect was observed during the study.

5 patients had mild dysphagia after treatment which improved over 3 days with analgesics. The maximum reported convalescence beyond the day of injection was 3 to 5 days (2 patients, both with mucosal breakdown), although the great majority of patients required no convalescence. Pain scores reported via the visual analog scale (0 to 10 scale) ranged from 0 to 6 and averaged 3.0 for post injection day 1, 2.4 for day 2, 2.2 for day 3, 1.4 for day 4, and less than 1 for day 5 (Fig. 5).

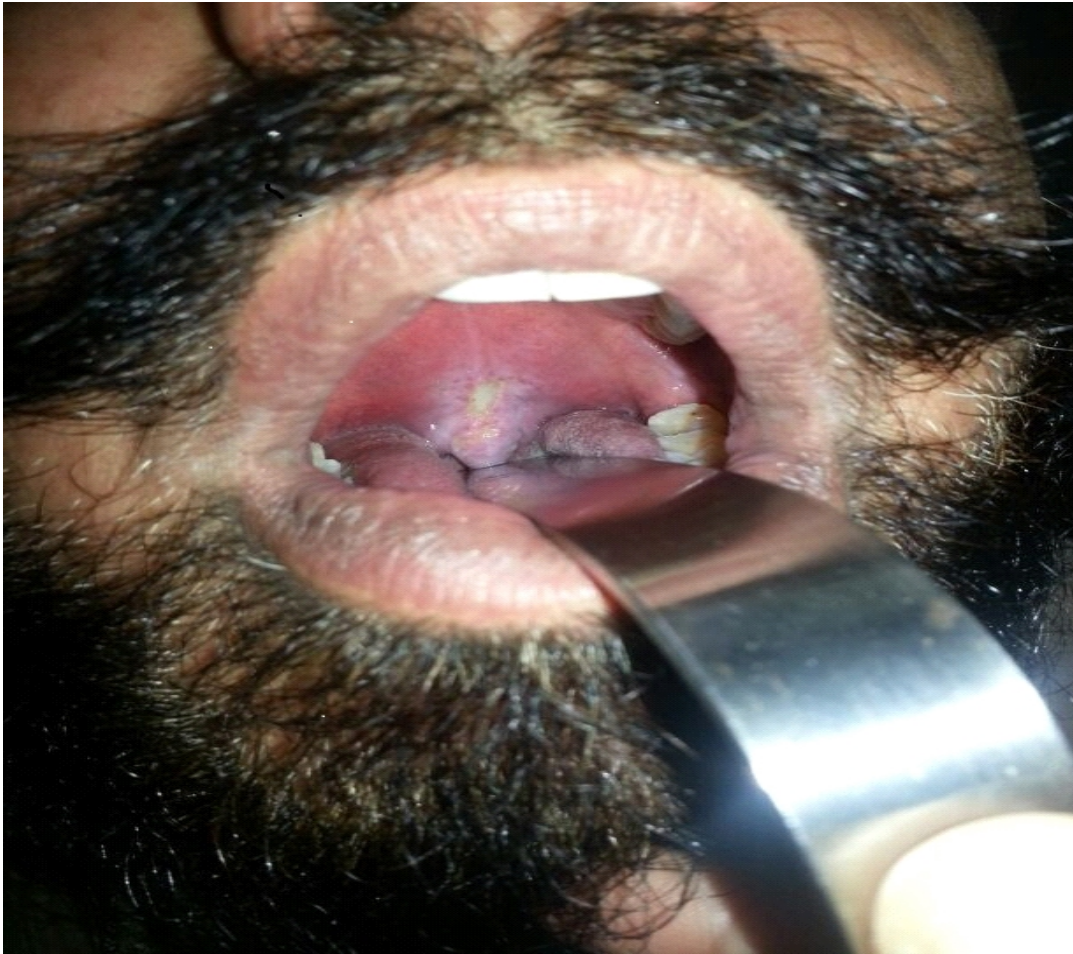

Fig. 2. Shows a healing ulcer in the soft palate at 2 weeks after injection snoreplasty

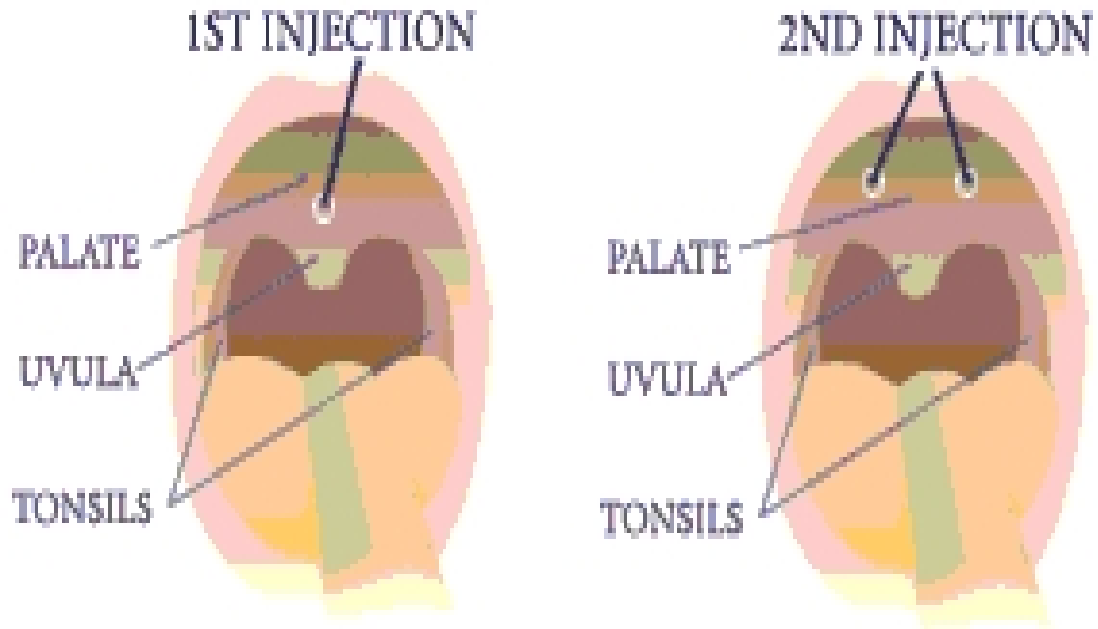


Fig. 3. Sites of injection in the soft palate

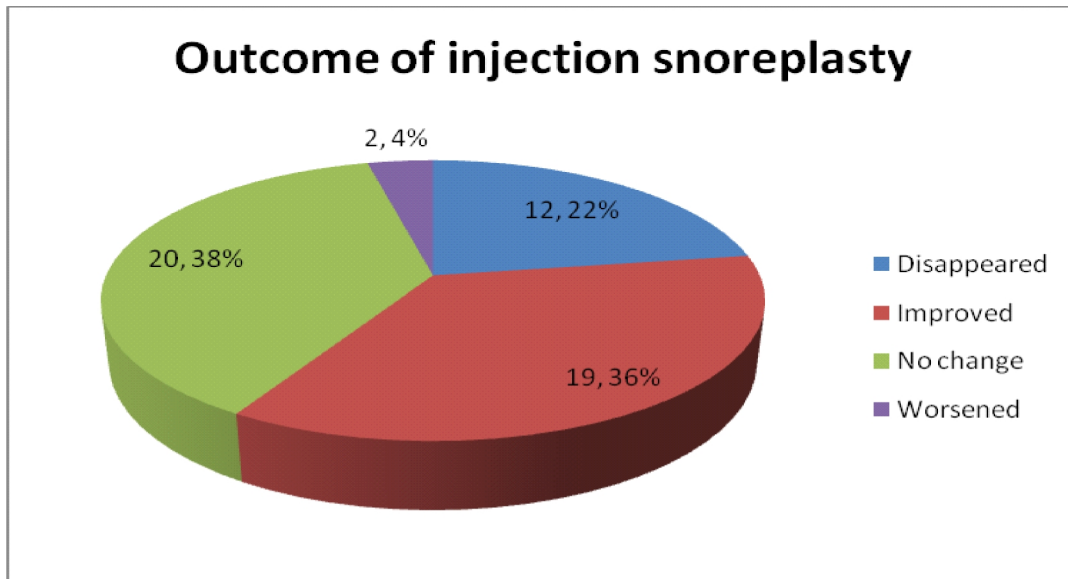


Fig. 4. Snoring improvement after injection snoreplasty

The correlation of percentage of improvement in snoring was calculated with BMI. This was our observation during the study although it was not the focus of our work. As many patients with snoring had high BMI, we planned to study the correlation of BMI with improvement in snoring. We found negative correlation between BMI and improvement in snoring with correlation coefficient value of -0.56 and p value of <0.05 using Pearson's correlation co-efficient method, there by implying that higher the BMI lesser would be the

improvement. Patients' BMIs had not changed over the one year of the study; although there had been temporary improvement, patients had returned to their original BMI eventually.

Sleep improved significantly in 48.14 % patients, remained unchanged in 37.03% and results were not known in 14.81 % patients as shown in (Table 1).

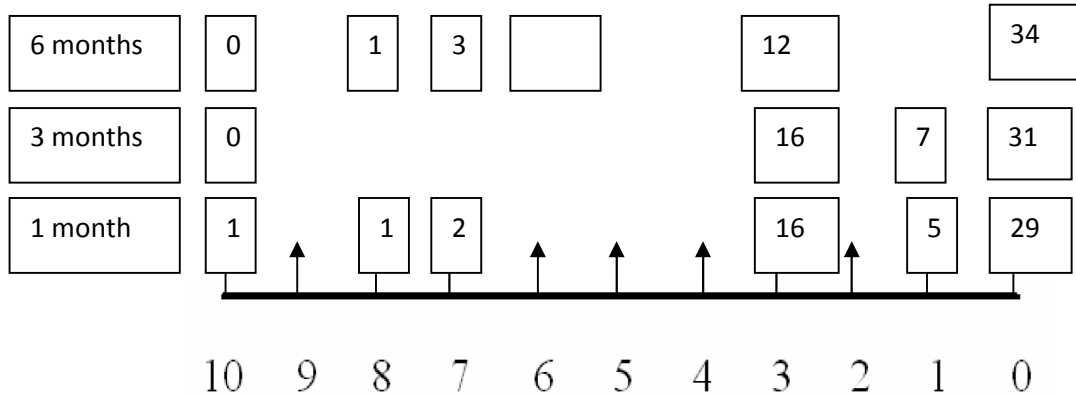


Fig. 5. Pain associated with snoreplasty

Table 1. Sleep improvement and injection snoreplasty

Sleep out come	Patients	
	N	%
Improved	26	48.14
Unchanged	20	37.03
Don't know	8	14.81

Snoring outcome was assessed clinically using VAS scale and by testing the simulated snoring during flexible nasopharyngoscopy and sleep improvement was tested subjectively as well as objectively using overnight sleep study.

3. DISCUSSION

UPPP was introduced as a first surgical treatment by Fujita [5] in 1981. The surgery gave good results initially, but with time they dropped significantly. Moreover, the drawback of UPPP included the requirement for general anesthesia and the association with significant postoperative pain and complications. To avoid the requirement for general anesthesia, LAUP was introduced by Kamami in 1990 [4]. However, it can be equally as painful as UPPP. In addition, it may require multiple procedures; thus, it is not a cost-effective procedure. Radiofrequency ablation for tissue volume reduction has been used for snoring treatment [2]. It provides a minimally invasive office-based therapy with decreased morbidity and less disruption of patients' normal activities in the peri-procedure period. However it requires a sophisticated equipment which is costly. Injection snoreplasty was introduced as a new treatment for primary snoring with advantages when compared to other snoring procedures [7]. It is very simple to perform, minimally painful and inexpensive. Brietzke et al. in their follow up of 22 patients over 19 months reported an improvement rate up to 75% [8].

We used sodium tetradecyl sulphate as a sclerosant agent, which showed to be safe and USFDA approved. Moreover, higher rates of palatal fistulas are noted with 50% ethanol, another agent commonly used [9].

The results of the different surgical procedures for snoring are variable. The success rate with UPPP for snoring is 40.7% as reported by Sher et al. [10]. We achieved 57.24% improvement rate in our patients which is quite good comparing with the morbidity of UPPP. The results of other modalities viz. radiofrequency ablation 46.7% [11], geniotubercle advancement 39-70% [12], hyoid advancement 53.3% [13], suture suspension of the tongue (repose procedure) 20-57% [12] and tongue base resection (midline glossectomy) 25-83% [12] are quite comparable our results. Moreover these surgical procedures demand expertise and have high morbidity. No such morbidity is seen with injection snoreplasty.

It is important to know how injection snoreplasty evolved. As the procedures described earlier for snoring treatment were too morbid requiring hospitalization, they went out of repute when injection snoreplasty was introduced in 2003 as a simple treatment for habitual snoring.

Recently Labra et al. [14] have done a pilot study using sodium tetra decyl sulphate as submucosal injection in the soft palate in patients with mild obstructive sleep apnea syndrome to treat snoring. They have found good results in OSAS patients as well thereby increasing the scope of this sclerotherapy in OSAS also.

Recently palatal implants have also been introduced [15]. They also stiffen the palate. They are painless and easy to implant. But reports of extrusion and high cost are disadvantages. The allergic reactions to these implants and long term results are yet to be known as these are in their initial phase. Injection snoreplasty on the other hand is quite safe and established method of palatal stiffening.

Patients with higher BMI tend to perform poorly with injection snoreplasty. This is quite understandable as obesity usually leads to multilevel obstruction in the airway. By injection snoreplasty we are only stiffening the palate. It was seen that if these patients reduce their weights then snoring improvement is more.

4. CONCLUSION

Injection Snoreplasty is introduced as a simple, safe, and effective office treatment for primary snoring. Advantages over current snoring procedures include simplicity, decreased expense, decreased post-treatment pain, and minimal/no convalescence. Given the numerous advantages, it has the potential to replace many current snoring treatments.

In summary, Injection Snoreplasty has been found to be the safe and effective sclerotherapy for treating habitual snoring with 58% cure rate in our study. No adverse effects were found in any of the subjects receiving this therapy.

CONSENT

Informed consent was taken in all patients before enrolling them in this study. It was recorded in the consent form.

ETHICAL APPROVAL

Ethical approval was sought for this study from the institute ethics committee before starting the study. It was approved by the committee.

ACKNOWLEDGEMENTS

I sincerely acknowledge the contributions of my co-author Prof. Ashok Gupta who guided me in designing this study. I acknowledge the contribution of Dr Gaurav Khandelwal for writing the manuscript and Dr Anil K Dash for data collection. Funding was provided by the institute research cell only for stationary and data collection. No funding was provided for manuscript preparation.

COMPETING INTERESTS

Authors declare that they have no competing interests.

REFERENCES

1. Hoffstein V, Madeira JH, Mateika S. Snoring and sleep architecture. *AM Rev Respir Dis.* 1991;143:92-96.
2. Powel NB, Riley RW, Troell RJ, et al. Radiofrequency volumetric tissue reduction of the palate in subjects with sleep-disordered breathing, *Chest.* 1998;113:1163-1174.
3. Mair EA, Day RH. Cautery-assisted palatal stiffening operation. *Otolaryngol Head Neck Surg.* 2000;122:547–555.
4. Kamami YV. Outpatient treatment of sleep apnea syndrome with CO2 laser laser-assisted UPPP. *J Otolaryngol.* 1994;23:395-398.
5. Fujita S, Conway W, Zorick F, et al. Surgical correction of anatomic abnormalities in obstructive sleep apnea syndrome uvulopalatopharyngoplasty. *Otolaryngol Head Neck Surg.* 1981;89:923–934.
6. Levin BC, Becker GD. Uvulopalatopharyngoplasty for snoring long term results. *Laryngoscope.* 1994;104:1150–1152.
7. Brietzke SE, Mair EA. Injection snoreplasty: How to treat snoring without all the pain and expense. *Otolaryngol Head Neck Surg.* 2001;124:503–510.
8. Brietzke SE, Mair EA. Injection snoreplasty: Extended follow-up and new objective data. *Otolaryngol Head Neck Surg.* 2003;128:605-15.
9. Brietzke SE, Mair EA. Injection snoreplasty: Investigation of alternative sclerotherapy agents. *Otolaryngol Head Neck Surg.* 2004;130:47–57.
10. Sher AE, Schechtman KB, Piccirillo JF. The efficacy of surgical modifications of the upper airway in adults with obstructive sleep apnea syndrome. *Sleep.* 1996;19:156-177.
11. Powell NB, Riley RW, Guilleminault C. Radiofrequency tongue base reduction in sleep-disordered breathing: a pilot study. *Otolaryngol Head Neck Surg.* 1999; 120:155-162.

12. Kezirian EJ, Goldberg AN. Hypopharyngeal surgery in obstructive sleep apnea. *Arch Otolaryngol*. 2006;132:206-213.
13. den Herder C, van Tinteren H, de Vries N. Hyoidthyroidpexia: A surgical treatment for sleep apnea. *Laryngoscope*. 2005;115:740-745.
14. Alberto Labra, Reyes Haro-Valencia, Angel-Daniel Huerta-Delgado, Ulises Jimenez-Correa, Francisco Sanchez-Narvaez. Efficacy of Submucosal Sodium Tetradecyl Sulfate in the Soft Palate as a Treatment of the Mild Obstructive Sleep Apnea Syndrome: A Pilot Study. *Sleep Disorders: Volume 2012 (2012)*, Article ID 597684, 4 pages. Available: <http://dx.doi.org/10.1155/2012/597684>.
15. Joachim TM, Hein G, Verse T, Hormann K, Stuck BA: Long-term results of palatal implants for primary snoring. *Otolaryngol Head Neck Surg*. 2005;133:573-78.

© 2014 Jaimanti et al.; This is an Open Access article distributed under the terms of the Creative Commons Attribution License (<http://creativecommons.org/licenses/by/3.0>), which permits unrestricted use, distribution, and reproduction in any medium, provided the original work is properly cited.

Peer-review history:

The peer review history for this paper can be accessed here:
<http://www.sciencedomain.org/review-history.php?iid=587&id=12&aid=5172>