



Acute B-Cell Lymphoblastic Leukemia/Acute B-Cell Lymphoblastic Lymphoma Presenting as Bilateral Breast Masses

Burak Ilhan¹, Fatma Sen², Rustu Turkey³ and Hasan Karanlik^{4*}

¹Department of General Surgery, Istanbul University, Istanbul Medical Faculty, Istanbul, Turkey.

²Department of Medical Oncology, Institute of Oncology, Istanbul University, Istanbul, Turkey.

³Department of Radiology, Istanbul Bakirkoy Dr. Sadi Konuk Training and Research Hospital, Istanbul, Turkey.

⁴Surgical Oncology Unit, Institute of Oncology, Istanbul University, Istanbul, Turkey.

Authors' contributions

This work was carried out in collaboration between all authors. Author BI designed the study, wrote the protocol and wrote the first draft of the manuscript. Authors FS, RT and BI managed the literature searches, analyses of the study and author HK managed the experimental process. All authors read and approved the final manuscript.

Article Information

DOI: 10.9734/BJMMR/2015/20637

Editor(s):

(1) Alex Xiucheng Fan, Department of Biochemistry and Molecular Biology, University of Florida, USA.

Reviewers:

(1) Arda Isik, Erzincan University, Turkey.

(2) Ketan Vagholkar, D. Y. Patil University, India.

Complete Peer review History: <http://sciencedomain.org/review-history/11331>

Case Report

Received 1st August 2015

Accepted 18th August 2015

Published 9th September 2015

ABSTRACT

Aims: Metastases of leukemia and lymphoma to both breasts were very rare. We have aimed to report a rare and interesting case that presented with metastases of leukemia and lymphoma to both breasts.

Case Report: A thirty-year-old woman has applied to our department with a four month story of painless masses in both of breasts. We have performed tru-cut biopsies to both breasts after clinical examination. Histological and immuno-histochemical profile analysis have revealed bilateral acute B - cell lymphoblastic lymphoma and acute B - cell lymphoblastic leukemia metastases. A positive response was observed after treating the patient with adjuvant systemic chemotherapy and consolidated radiation therapy. On the sixth month follow-up, no evidence of disease recurrence was identified.

*Corresponding author: Email: hasankaranlik@yahoo.com;

Discussion: In patients presenting with bilateral breast masses, considering that other tumors may metastasize to the breast, the details of this rare case may aid clinicians treating similar patients, and highlight the importance of this situation.

Conclusion: This finding emphasizes the need to accurately identify these tumors as metastases in order to avoid unnecessary procedures and treatments in these patients.

Keywords: Leukemia; lymphoma; breast involvement; metastasis.

1. INTRODUCTION

Metastases to the breast and axilla are rare and account for approximately 2% of all mammary malignancies [1,2]. The most common metastatic lesion to involve the breast is a metastasis from a contralateral mammary cancer [1,2]. If hematologic malignancies are also excluded, the number of non-mammary metastases drops to well below 1% [1-3]. Although most common extra mammary metastases of breast is from hematopoietic system and melanomas, presenting of the patient with both breast involvement is very rare [4]. The present study reports the rare case of thirty-year-old female breast metastases with extra mammary leukemia and lymphoma. Due to the rarity of the disease, the relevant literature was also reviewed.

2. CASE REPORT

Thirty-year-old woman with four month story of painless bilateral breast masses was presented to the Breast Unit of Istanbul Medical Faculty. The masses had rapidly increased their size in diameter according to the patient's story. Multiple masses were found with the largest being 4 cm on the right and 3 cm on the left breast. We detected multiple enlarged axillary and cervical lymph nodes on physical examination bilaterally. Bicytopenia on hemogram has made us to suspect hematologic diseases.

Bilateral mammography and ultrasonography were performed. Mammography has revealed BIRADS V lesions on both breasts. On ultrasonography, an intramammary lymph node (IMLN) of 2,5x2 cm diameter located in the upper outer quadrant was detected. Fatty hilum of this node was undistinguishable with highly vascular appearance. Sonoelastographic value of IMNN was 129±26.2 kPa. Ultrasonography of the left breast was revealed several oval shaped and ill-defined hypoechoic solid lesions with maximum diameter of 8.6 mm. In shear wave elastography, masses in left breast categorized as hard lesions (136.7±33.4 kPa). Normal breast parenchymal elastography value was 13.8±2.9 kPa for the left

breast and 12.6±2.5 kPa for the right breast (Figs. 1-2). Shear wave sonoelastography provides quantitative elasticity measurements, thus adding complementary information that potentially could help in breast lesion characterization with B-mode US. With gray-scale findings, as in our case, sometimes it can be challenging to distinguish pathologic tissue from normal breast tissue. In our case, we have measured the elasticity in the lesions higher than the normal tissue and classified them as hard. These values give us the opportunity to perform tru-cut biopsies for suspected lesions.

We planned and performed a tru-cut biopsy. Histological findings revealed infiltration of the breast parenchyma by cells with blastic morphology. Immuno-histochemical evaluation has demonstrated the following; Tdt (+), CD34 focally (+), CD15 (+), CD20 focally (+), PAX5 (+), CD2 (-), CD3 (-), CD5(-), CD10 (+), p63 (-), bcl-1 (-), and CD56(-). Microscopically, the tumor cells were demonstrated invasive growth with a tendency to surround and invade the wall and lumina of the epithelial structures, resulting in a lympho-epithelial lesion. In addition, the mammary gland structure was destroyed (Figs. 3-4).

We additionally have performed a positron emission computed tomography to evaluate the patient and excluded further metastatic disease.

3. DISCUSSION

Intramammary metastases in women were %92.2 and were metachronous %84. In imaging commonly the presence of multiple, bilateral round tumors, superficial without the traditional signs of malignancy which one meets with the primitive tumors, such as irregular margins, speculations, microcalcifications, posterior cone of shadows were evocative diagnosis. The prevalence of primitive cancer were not alone responsible for intramammary metastases. The seed and soil theory could explain, that tumor cells could grow selected organs, such as melanoma. The vascularity was also very important.

Hematologic metastases to the breast and axilla were rare occurrences. They usually develop in the fifth or sixth decade and the patients most often had a prior history of a malignant tumor with documented metastatic spread. A wide variety of malignancies from many different sites have been reported with the most common sites of origin reported as the lung, skin, stomach, colon, and ovary [5-12].

Breast metastases of leukemia and lymphoma remain as rare diseases however the occurrence was more frequent due to improved diagnostic techniques and increased awareness about the disease. As diagnostic criteria; obtaining adequate specimen for pathological evaluation, confirming the lymphoid infiltration of breast tissue, and the presence of ipsilateral axillary lymph node involvement was crucial [13].

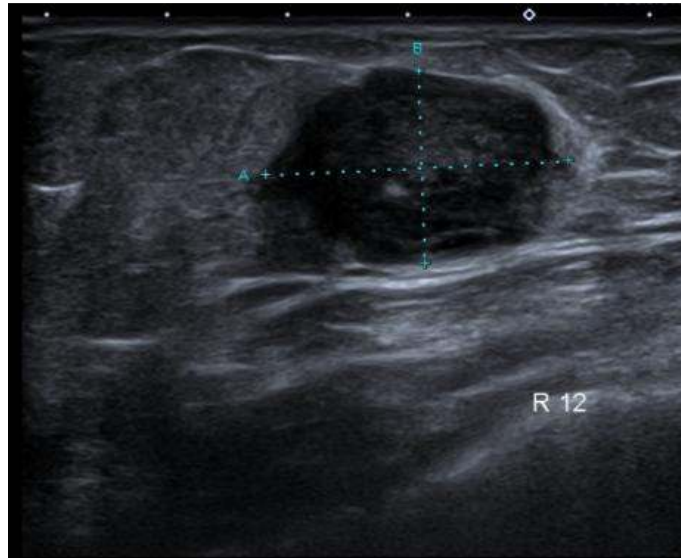


Fig. 1. Palpable right breast mass, ultrasonographic appearance of pathologic intramamarian lymph node

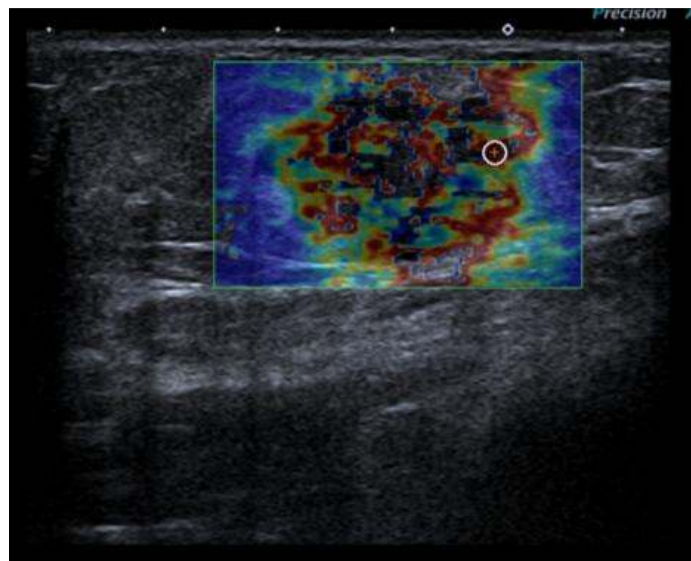


Fig. 2. Shear wave ultrasonographic findings of IMLN; mean elasticity value was 129.5 ± 26.2 kPa

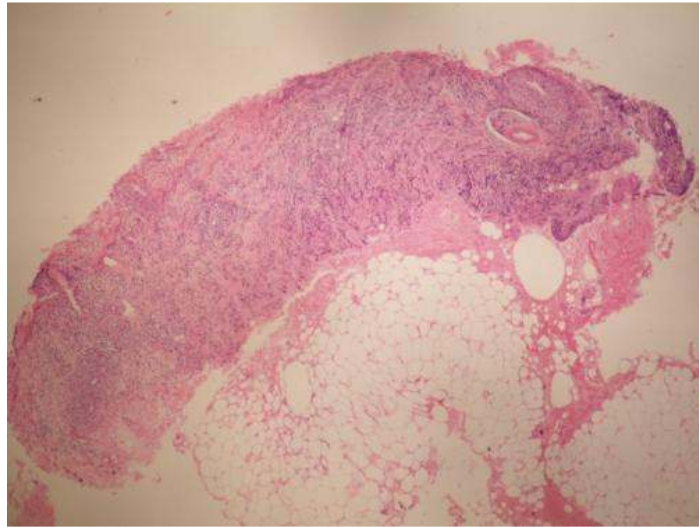


Fig. 3. Tru-cut biopsy material (HEx40)

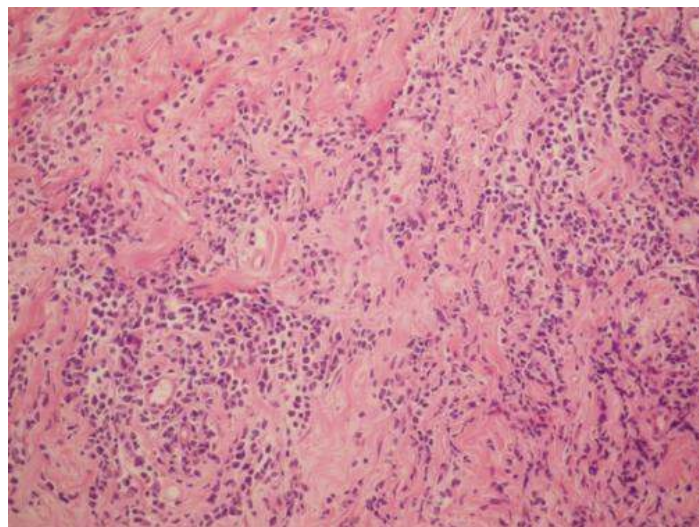


Fig. 4. Magnified image (HEx100)

Histopathological and immuno-histochemical evaluation is very important, because this tumor was also the type most often misdiagnosed initially with a primary breast cancer. The literature shows that the lack of the clinician to provide the absence of a prior cancer history is resulted with the failure of the pathologist to recognize the metastatic nature of the lesion at the time of initial interpretation. A correct diagnosis is crucial so as to avoid unnecessary procedures and treatments in these patients. Holland solution should be used for fixation of the biopsy specimen in suspicion of hematopoietic malignancy. Additionally, Tdt, CD34, CD15, CD20, PAX5, CD2, CD3, CD5, CD10, pcd-6,

bcl-1, and CD56 were useful for immuno-histochemical evaluation of leukemia and lymphoma.

4. CONCLUSION

To date, no standard treatment for breast metastasis of leukemia and lymphoma has been identified. Mastectomy is not indicated and wide local excision is not required as these tumors are highly sensitive to radiotherapy and systemic chemotherapy [10]. For small localized tumors, adequate surgical resection may be effective, followed by chemotherapy or radiotherapy.

CONSTENT

All authors declare that 'written informed consent was obtained from the patient for publication of this case report and accompanying images

ETHICAL APPROVAL

It is not applicable.

ACKNOWLEDGMENTS

The research was supported by Istanbul Medical Faculty general surgery and pathology section. The funding agency had no role in the study design, collection, analysis and interpretation of data or in the writing of the manuscript.

COMPETING INTERESTS

Authors have declared that no competing interests exist.

REFERENCES

1. Georgiannos SN, Chin J, Goode AW, Sheaff M. Secondary neoplasms of the breast: A survey of the 20th Century. *Cancer*. 2001;92:2259–2266.
2. Mason C, Yokubaitis K, Hamilton R, Oza U, Shah Z, Spigel J. Unusual presentation of metastatic ovarian carcinoma as an enlarged intramammary lymph node. *Proc (Bayl Univ Med Cent)*. 2015;28(3):386-8.
3. Chaignaud B, Hall TJ, Powers C, Subramony C, Scott-Conner CE. Diagnosis and natural history of extramammary tumors. *J Am Coll Surg*. 1994;179(1):49-53.
4. Oksuzoglu B, Abali H, Güler N, Baltali E, Ozişik Y. Metastasis to the breast from nonmammary solid neoplasms: A report of five cases. *Med Oncol*. 2003;20:295–300.
5. Georgiannos SN, Chin J, Goode AW, Sheaff M. Secondary neoplasms of the breast: A survey of the 20th Century. *Cancer*. 2001;92:2259-2266.
6. Serraille A, Barazzutti H, Greillier L, Barlesi F. Atypical metastatic breast localization in lung cancer. *Rev Mal Respir*. 2015;S0761-8425
7. Lee SK, Kim WW, Kim SH, Hur SM, Kim S, Choi JH, et al. Characteristics of metastasis in the breast from extramammary malignancies. *J Surg Oncol*. 2010;101:137–140.
8. DeLair DF, Corben AD, Catalano JP, Vallejo CE, Brogi E, Tan LK. Non-mammary metastases to the breast and axilla: A study of 85 cases. *Mod Pathol*. 2013;26(3):343-9.
9. Williams SA, Ehlers RA 2nd, Hunt KK, Kuerer HM, Singletary SE, Ross MI, et al. Metastases to the breast from nonbreast solid neoplasms: Presentation and determinants of survival. *Cancer* 2007;110:731–737.
10. Brogi E, Harris NL. Lymphomas of the breast: Pathology and clinical behavior. *Semin Oncol*. 1999;26:357-364.
11. Koch A, Richter-Marot A, Wissler MP, Baratte A, Mathelin C. Mammary metastases of extramammary cancers. *Gynecol Obstet Fertile*. 2013;41(11):653-659
12. Magri K, Damaoulin G, Milion G, Duvert B. Metastases to the breast from non-mammary metastases. 2007;36(6):602-606.
13. Duman BB, Sahin B, Guvenc B, Ergin M. Lymphoma of the breast in a male patient. *Med Oncol*. 2011;28(Suppl 1):S490-S493.

© 2015 Ilhan et al.; This is an Open Access article distributed under the terms of the Creative Commons Attribution License (<http://creativecommons.org/licenses/by/4.0>), which permits unrestricted use, distribution, and reproduction in any medium, provided the original work is properly cited.

Peer-review history:
The peer review history for this paper can be accessed here:
<http://sciedomain.org/review-history/11331>