



Endoscopic Ultrasound-Guided Liver Lesions Biopsy with Atypical Malignancies- An Alternative to Radiological Biopsy

**Zain Majid^{a*}, Adeel Urrehman^a, Shoaib Ahmed Khan^a,
Muhammad Mazoor ul Haq^a, Rani Tulsi^a, Asha Devi^a, Nasir Mehmood^a,
Nishat Akbar^a, Nasir Hassan Luck^a and Mohammad Mubarak^b**

^a *Department of Gastroenterology and Hepatology, Sindh Institute of Urology and Transplantation, SIUT, Karachi, Pakistan.*

^b *Department of Histopathology, Sindh Institute of Urology and Transplantation, Karachi, Pakistan.*

Authors' contributions

This work was carried out in collaboration among all authors. All authors read and approved the final manuscript.

Article Information

DOI: 10.9734/JPRI/2022/v34i44B36346

Open Peer Review History:

This journal follows the Advanced Open Peer Review policy. Identity of the Reviewers, Editor(s) and additional Reviewers, peer review comments, different versions of the manuscript, comments of the editors, etc are available here: <https://www.sdiarticle5.com/review-history/89432>

Original Research Article

Received 25 April 2022

Accepted 11 July 2022

Published 16 July 2022

ABSTRACT

Background: Endoscopic ultrasound (EUS) is gaining attraction as an alternative method of obtaining biopsies. It offers a more targeted approach for focal lesions in liver especially for those areas which are accessible via EUS-guided method.

Materials and Methods: A total of 8 patients underwent EUS-guided liver lesions biopsies (LLB). EUS Guided LLB was performed using the 22G FNA needle, 2 passes were done with slow pull technique over one minute with 10–15 strokes done in each pass to obtain core samples. The average duration of the procedures ranged from 15–30 minutes.

Results: Out of 8 patients, majority were males. Most of these patients had presented with nonspecific signs and symptoms including weight loss, abdominal pain, jaundice etc. All of the 8 patients had atypical liver lesions on initial radiological evaluation with inconclusive tumour markers and atypical CT radiological findings. Screening for Hepatitis B and C virus were negative in all of them. EUS guided biopsy performed in them revealed the following diagnosis: well differentiated adenocarcinoma, sarcomatoid carcinoma, neuroendocrine tumour, smooth muscle tumour, metastatic adenocarcinoma, lymphoproliferative disorder and malignant melanoma.

Conclusions: EUS-guided LLB is an alternative new technique for biopsy of liver lesions with suspected atypical malignancies.

Keywords: Endoscopic ultrasound; liver lesion; radiological biopsy; atypical malignancies.

1. INTRODUCTION

A Liver biopsy often plays a crucial role when making decisions for patients with liver disease [1]. A through history, physical examination along with the laboratory parameters are all critical when establishing a diagnosis, however the role of liver biopsy for diagnostic purposes is still there and can pick up significant fibrosis and cirrhosis even in those abnormal LFTs having normal serological results [2]. A percutaneous liver biopsy can have sampling variability and thus sampling errors may lead to misdiagnosis [1]. Hence image guided liver lesion biopsies via CT scan or MRI for these atypical malignancies are recommended [3,4].

Endoscopic ultrasound (EUS) is gaining attraction as an alternative method of biopsy [1,A]. It offers a more targeted approach for focal lesions in liver especially those areas which are accessible via EUS-guided method with its high diagnostic yield, better histological specimen and limited adverse event profile with results comparable to percutaneous and transjugular liver biopsy, making it a more promising modality [2,A].

2. MATERIAL AND METHODS

All the patients were inducted via the outpatients' department of the department of Hepatogastroenterology, Sindh Institute of Urology and Transplantation, SIUT, Pakistan and were discharged the same day. A total of 8 patients were included in this study for EUS guided liver lesion biopsy. The procedure was carried out under conscious sedation and informed written consent was obtained from the patients prior to the procedure. Standard base line laboratory investigations were performed prior to the procedure. EUS guided liver lesion biopsy was done by using a 22-gauge FNA needle. 2 passes were done using slow pull technique over 1 minute with 10-15 strokes in each pass to obtain core samples. The total duration of the procedures ranged from 15 minutes to 30 minutes.

3. RESULTS

Case 1, A 78-years-old male having a history of gastrectomy done 5 years ago for a biopsy

proven gastric cancer, presented to us having weight loss and vague epigastric pain since 3 months. His CT scan abdomen showed left lobe SOL (space occupying lesion), measuring 3.4cm x3.4cm in the segment IV of the liver without any lymph node involvement. EUS guided biopsy of the lesion was done which showed well differentiated adenocarcinoma from GI (gastrointestinal) Tract (as shown in Fig. 1).

Case 2, A 58-years-old male presented with weight loss of 10kgs in 2 months and on further workup was found to have a large liver lesion measuring 6.2cm x 4.5cm in segment VII, showing enhancement without any washout. Hepatitis B & C serology were negative with normal serum AFP levels of 10ng/ml (normal: less than 20ng/ml). EUS guided Biopsy of the liver lesion was done which revealed Sarcomatoid Carcinoma (as shown in Fig. 1).

Case 3, Another case showed a 53-Year-old male who was evaluated for weight loss and abdominal pain for 2 months. His CT Scan abdomen had revealed multiple lesions in the liver, which were isodense to the liver so an EUS guided biopsy of one of those lesions revealed a Neuroendocrine Tumor (as shown in Fig. 2).

Case 4, A 35-years-old male presented with abdominal pain on and off since 4 months. Laboratory tests showed anti-HCV reactive, HCV RNA detected with normal AFP levels. CT Scan had shown a liver lesion showing arterial enhancement without any washout on the portovenous phase, which were suggestive of atypical hepatoma. Biopsy revealed Smooth Muscle Tumor (as shown in Fig. 1). As part of workup he also had gastroscopy and Colonoscopy with no evidence of luminal malignancy.

Case 5, A 60-years-old female, recently diagnosed with diabetes, presented with weight loss, CT scan showed a mass in the head of the pancreas measuring 2x 2.4cm without any vascular involvement but with liver metastasis. EUS guided biopsy revealed metastatic Adenocarcinoma (as shown in Fig. 1) and the patient was referred to the medical oncologist for further management.

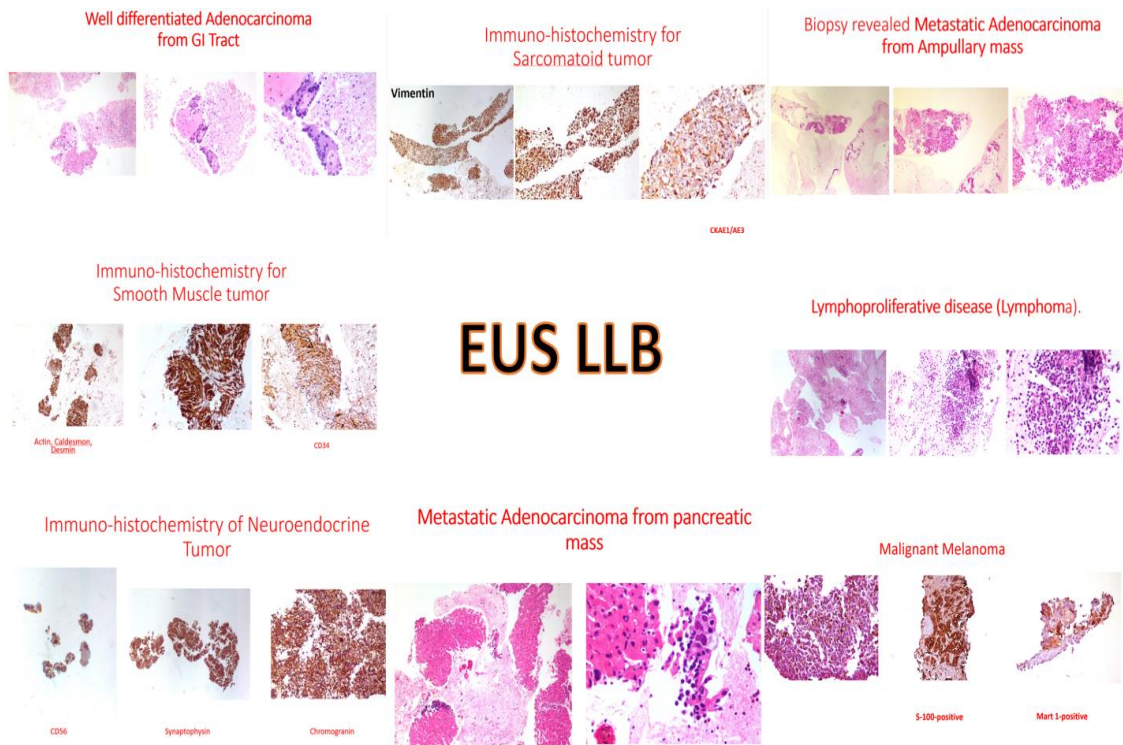


Fig. 1. A collage of the 8 EUS guided liver biopsies

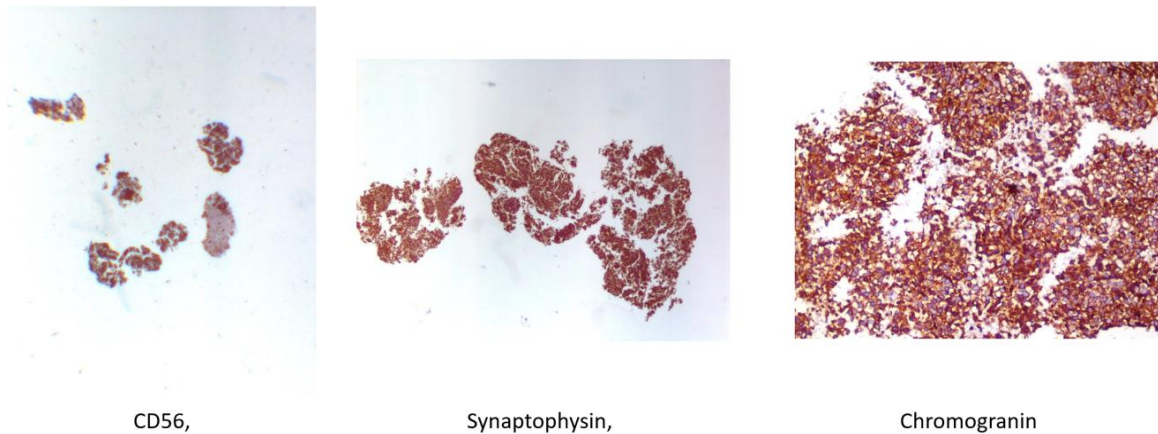


Fig. 2. Neuroendocrine tumor

Case 6, 42-years-old female presented with obstructive jaundice secondary to ampullary carcinoma with an SOL in the liver on CT scan findings. She underwent EUS staging and biopsy, the biopsy of left liver lobe lesion revealed Metastatic Adenocarcinoma (as shown in Fig. 1).

Case 7, A 32-year-old male being worked up for weight loss and obstructive jaundice for 3 months, CT scan showed left lobe malignancy consistent with Cholangiocarcinoma with normal

AFP and CA19-9 levels, his hepatitis B & C screen negative, biopsy revealed Lymphoproliferative disease (Lymphoma) (as shown in Fig. 3).

Case No 8, 48-years old male presented with weight loss and abdominal discomfort, Hepatitis B and C screen was negative with normal AFP levels. Ct scan showed multiple liver lesion, Biopsy was done which showed Malignant melanoma (as shown in Fig. 4).

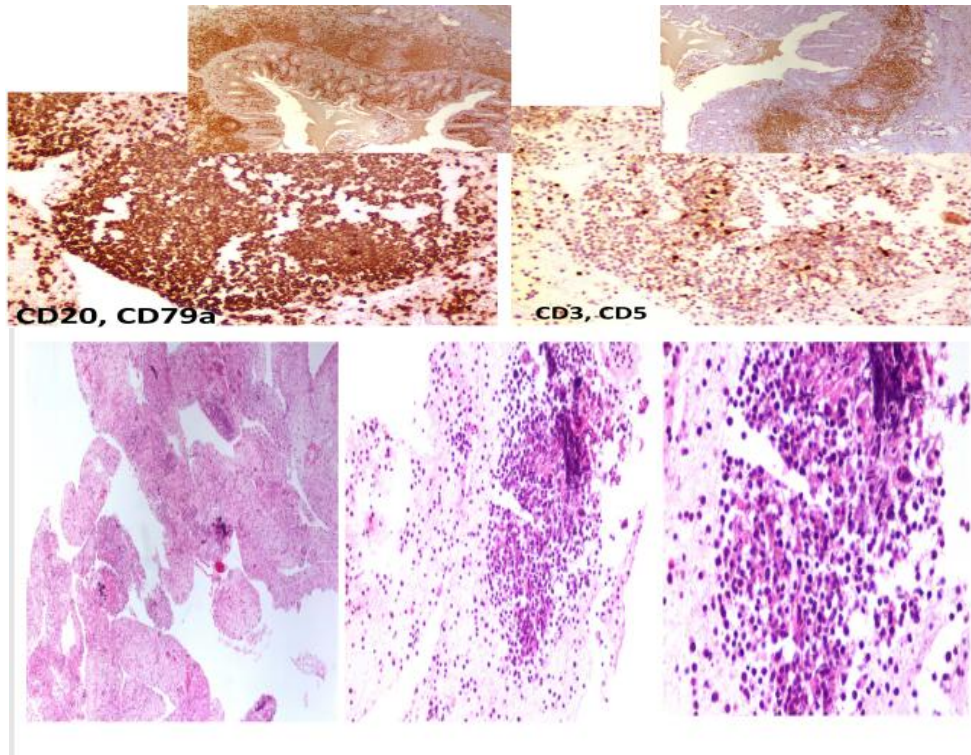


Fig. 3. Lymphoproliferative disease (Lymphoma)

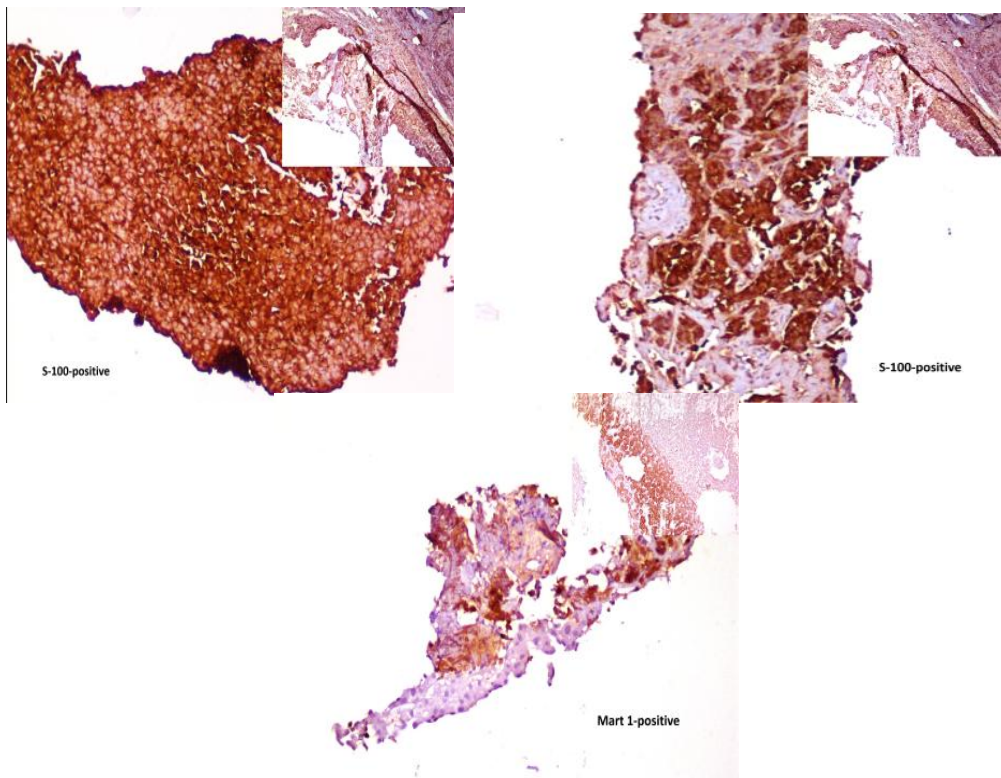


Fig. 4. Malignant melanoma

4. DISCUSSION

The percutaneous liver biopsy, first performed in the 1920s, has seen various phases of evolution and has gone from a blind approach to an ultrasound (U/S) or CT guided. The use of the image guided techniques has significantly reduced the complication rates [1]. The main complication of the image guided techniques include pain at the biopsy site or at the right shoulder [1]. The trans jugular approach for liver biopsy is employed when the percutaneous approach is contraindicated that is in the presences of ascites, coagulopathy, morbid obesity and a non-cooperative person [1]. The complications include hematoma, carotid puncture, risk of Horner's syndrome and supraventricular arrhythmias [1].

The EUS guided liver biopsy is a recently introduced technique having a low side effect profile. By providing high resolution images of the both the right and left lobes of the liver, the biopsy needle is used safely for sampling [5]. By using its Doppler, the intervening vessels and structures are avoided. Hence EUS allows safe sampling from either lobes of the liver [6]. The 19 gauge Tru cut needle or the FNA needle is used to obtain the sample [7,8]. A metaanalysis involving 23 studies, involving 1326 subjects revealed that EUS core biopsy needles had more chances of providing a complete core as compared to fine needle aspiration needles [9]. Another study showed how inadequate sample when using the 22 gauge franseen tip needle when compared to the 19 gauge needle [10].

Having the ability to pick up pancreatic lesions which are less than 5cm in size, EUS has the ability to target liver lesions which are less than 1cm in size [3]. The trans-gastric approach offers an easy access to these liver lesions even in the presence of ascites [3].

The main advantages for using EUS for liver biopsy is that it can be done in an outpatients' setting and hence reduces the patient's anxiety and stress. Secondly, sampling of both lobes of the liver are possible through it, more easily approachable by EUS then with conventional CT since a larger surface area is visible through the EUS. Thirdly nearby vasculature structures can be avoided [11]. Even though currently the standards for an EUS guided liver specimen have not been established, but these should be the same as those obtained via the percutaneous approach, with the length of the specimen,

number of complete portal tracts along with the needle type being important parameters [12]. Lastly biopsies obtained via EUS can help avoid major vessels and the biliary tree hence reduce chances of complications [3].

5. CONCLUSION

EUS guided liver lesion biopsy is an attractive options with a better safety profile, less side effects and better patient related outcome.

CONSENT

As per international standard or university standard, patients' written consent has been collected and preserved by the author(s).

ETHICAL APPROVAL

Ethical review was taken as per institutional protocol.

DISCLAIMER

Some part of this manuscript also an abstract was previously presented and published in the Joint Event on GLOBAL PHARMA SUMMIT & 2nd International Conference on GASTROENTEROLOGY AND HEPATOLOGY, November 23-24, 2018, Bangkok, Thailand , Web Link of the proceeding: <http://dx.doi.org/10.1136/gutjnl-2019-IDDFAbstracts.157>

WHAT IS KNOWN

Identification and characterization of malignant lesions requires image guided biopsies.

WHAT IS NEW

Image guided biopsy has now evolved and now endoscopic ultrasound guided biopsy has over taken it, being not only safe but also very effective.

Our study shows how EUS guided biopsies can be obtained for different liver lesions inorder to reach a diagnosis

COMPETING INTERESTS

Authors have declared that no competing interests exist.

REFERENCES

1. Parekh PJ, Majithia R, Diehl DL, Baron TH. Endoscopic ultrasound-guided liver biopsy. *Endosc Ultrasound*. 2015 Apr-Jun;4(2):85-91. DOI:10.4103/2303-9027.156711. Review. PubMed PMID: 26020041; PubMed Central PMCID:PMC4445181.
2. Skelly MM, James PD, Ryder SD. Findings on liver biopsy to investigate abnormal liver function tests in the absence of diagnostic serology. *J Hepatol*. 2001;35:195–9. [PubMed]
3. Adeel Urrehman. Endoscopic ultrasound guided liver lesions biopsy EUS LLB is an alternative method of image guided biopsy for suspected atypical liver malignancies. *Acta Scientific Clinical Case Reports*. 2020;1.3:17.
4. Madhok IK, Parsa N, Niet JM. Endoscopic Ultrasound-Guided Liver Biopsy. *Clin Liver Dis*. 2022 Feb;26(1):127-138. DOI: 10.1016/j.cld.2021.09.002. PMID: 34802658.
5. Mathew A. EUS-guided liver biopsy in select patients. *Am J Gastroenterol*. 2007;102:2354–2355.
6. Gleeson FC, Clayton AC, Zhang L, et al. Adequacy of endoscopic ultrasound core needle biopsy specimen of nonmalignant hepatic parenchymal disease. *Clin Gastroenterol Hepatol*. 2008;6:1437–1440.
7. Nakai Y, Samarasena JB, Iwashita T, et al. Autoimmune hepatitis diagnosed by endoscopic ultrasound-guided liver biopsy using a new 19-gauge histology needle. *Endoscopy*. 2012;44: E67–E68. PMCID: PMC4486032 PMID: 26171433
8. Jose Nieto, Huda Khaleel, Youssef Challita, et al. EUS-guided fine-needle core liver biopsy sampling using a novel 19-gauge needle with modified 1-pass, 1 actuation wet suction technique. *Gastrointest Endosc*. 2018;87:2:469-475.
9. Baran B, Kale S, Patil P, Kannadath B, Ramireddy S, Badillo R, DaVee RT, Thosani N. Endoscopic ultrasound-guided parenchymal liver biopsy: a systematic review and meta-analysis. *Surg Endosc*. 2021 Oct;35(10):5546-5557
10. Patel HK, Saxena R, Rush N, Patel SK, Dasari CS, Mneimneh W, Quickery A, Rahal MA, Temnykh L, DeWitt J, Al-Haddad M. A comparative study of 22G versus 19G needles for EUS-guided biopsies for parenchymal liver disease: Are thinner needles better? *Dig Dis Sci*. 2021 Jan;66(1):238-246.
11. Shah ND, Sasatomi E, Baron TH. Endoscopic Ultrasound-guided Parenchymal Liver Biopsy: Single Center Experience of a New Dedicated Core Needle. *Clin Gastroenterol Hepatol*. 2017 May;15(5):784-786. DOI: 10.1016/j.cgh.2017.01.011. Epub 2017 Jan 23. PMID: 28126424.
12. DeWitt J, McGreevy K, Cummings O, et al. Initial experience with EUS-guided Tru-cut biopsy of benign liver disease. *Gastrointest Endosc*. 2009;69:535–542.

© 2022 Majid et al.; This is an Open Access article distributed under the terms of the Creative Commons Attribution License (<http://creativecommons.org/licenses/by/4.0>), which permits unrestricted use, distribution, and reproduction in any medium, provided the original work is properly cited.

Peer-review history:

The peer review history for this paper can be accessed here:

<https://www.sdiarticle5.com/review-history/89432>