

The Outcome of the Chemotherapy and Oncothermia for Far Advanced Adenocarcinoma of the Lung: Case Reports of Four Patients

Doo Yun Lee¹, Joon Seok Park¹, Hae Chul Jung¹, Eun Seol Byun², Seok Jin Haam²,
Sung Soo Lee²

¹Department of Thoracic Cardiovascular Surgery, Bundang CHA Medical Center, CHA University, Kyunggido, Korea

²Department of Thoracic Cardiovascular Surgery, Gangnam Severance Hospital, College of Medicine, Yonsei University, Seoul, Korea

Email: dylee4831@naver.com

Received 26 January 2015; accepted 11 March 2015; published 13 March 2015

Copyright © 2015 by authors and Scientific Research Publishing Inc.

This work is licensed under the Creative Commons Attribution International License (CC BY).

<http://creativecommons.org/licenses/by/4.0/>



Open Access

Abstract

Lung cancer is one of the most aggressive and lethal form of cancers. Patients with far advanced lung cancer are treated by chemotherapy with or without radiotherapy. However, median survival of these patients is less than 6 months. To increase survival and quality of life for these patients, various forms of complementary treatments have been tried in clinical practices, and oncothermia is supposed to be one of the promising candidates. From May 2008 to November 2013, 4 patients with far advanced lung adenocarcinoma (stages IIIB and IV) were treated with oncothermia in addition to conventional chemotherapy at Gangnam Severance Hospital and Bundang CHA Hospital. All these patients have survived for more than 2 years.

Keywords

Lung Cancer, Chemotherapy

1. Introduction and Background

Lung cancer occupies the greatest number of cancer-related death of both sexes worldwide [1] [2]. In North America and Europe at about 40% of patients with newly diagnosed non-small cell lung cancer (NSCLC) have

How to cite this paper: Lee, D.Y., Park, J.S., Jung, H.C., Byun, E.S., Haam, S.J. and Lee, S.S. (2015) The Outcome of the Chemotherapy and Oncothermia for Far Advanced Adenocarcinoma of the Lung: Case Reports of Four Patients. *Advances in Lung Cancer*, 4, 1-7. <http://dx.doi.org/10.4236/alc.2015.41001>

advanced disease over the stage IIIB. Median survival of these patients is only 6 months. The estimated 1-year survival is not satisfactory (the median survival is less than a year for advanced stages), despite of the treatments such as state-of-art chemotherapy, radiotherapy and other supportive cares [3].

Various forms of chemotherapy agents have been used in combination to improve the outcomes of the treatment. The most widely used agents include Cisplatin, Gemcitabine, Pemetrexed, Paclitaxel, and Iressa/Tarceva. By the administration of these chemo-agents, median survival of patients with advanced lung cancer have increased up to 12 months (10.9 months with Gemcitabine and Cisplatin [4], and 12.6 months with Pemetrexed and Cisplatin [5]). However, in far advanced lung cancer (stage IIIB or stage IV) the cure or complete remission of disease is hardly expected with chemotherapy only. Even though the primary tumors respond to the treatments, in these advanced cases intrathoracic and abdominal metastases frequently occur. Furthermore, resistance to applied drugs eventually develops in most far-advanced lung cancer, the lesion becomes refractory as chemotherapy is administered repeatedly. Therefore, radiotherapy and other complementary treatments are usually added to improve survival and quality of life.

Hyperthermia therapy is one of the possible complementary treatments, and known to have benefit for the improvement of survival and quality of life of patients with far advanced lung adenocarcinoma [6]. Conventional hyperthermia however fails to achieve high enough temperature in the lung cooled by breathing. To create curative effect for advanced lung tumors only by necrotic thermal dose is a difficult task, the heating energy is easily spread and neutralized by the surrounding normal tissues and by the anyway intensive blood-flow as direct and active heat-exchanger. The dispersed heat-energy further increases the blood flow around the tumor and consequently accelerate tumor growth by glucose supply and induce further risks of metastatic invasion and dissemination. To go over these difficulties intensive selective heating has to be applied, heating the most sensitive microscopic target the cell-membrane of the malignant cells. Oncothermia [7] rises the temperature very locally on the membrane rafts of the malignant cells, and does not waste energy to heat other parts of the malignant mass, it does not rise the temperature of the surrounding electrolytes of the blood and lymph circulation, and does not rise the temperature either in the surrounding normal tissues too [8]. Therefore, cancer cells, which are very prone to heat injury, are selectively destructed without collateral damage to surrounding normal tissues. As there is no collateral heat dispersion, blood flow to tumor tissue is not increased considerably and the neovascularization is also suppressed. The effect is based on the overburdened extracellular electrolyte by ionic metabolites and final metabolic products, which changes the electrophysiologic environments of the immediate vicinity of the tumor-cells [9] [10]. These conditions affect the malignant cells by various ways:

1) Oncothermia pumps through heat-energy $1500 \text{ nW}/\mu\text{m}^2$ the malignant cell membranes, while the basal metabolic heat-production drives only $20 \text{ nW}/\mu\text{m}^2$ heat flow in opposite direction through the membrane.

2) Heat delivered by Oncothermia induces Na^+ influx current $150 \text{ pA}/\mu\text{m}^2$ [11] while the normal process is Na^+ efflux.

3) Na^+ ions accompanied with water molecules moves into the malignant cell by electro-osmotic way increasing the pressure within the cell. This abrupt inflow of water results higher intracellular pressure destabilizing the membrane, helping the oncothermia effects on the membrane rafts [12].

These processes enhance the cell-membrane associated apoptosis of tumor cells [13]. The massive production of the apoptotic bodies and the producing of the damage associated molecular pattern [14] could cause immunogenic cell-death and immune-activation of the system, which could lead to abscopal effect [12].

Combination of adjunct oncothermia with conventional chemotherapy can be a promising treatment to enhance chemo sensitivity, because oncothermia increases the chemo-influx into tumor cells. Consequently, concentration of chemo-agents increases and pH environment changes along with high temperature inside the cells, which could enhance the cancer cell apoptosis. Despite the beneficial effect on the tumor cell apoptosis, oncothermia has virtually no significant adverse effect.

Assuming the above factors, we expected better treatment outcomes for patients with far advanced lung cancer by the combination of chemotherapy and oncothermia than by the conventional treatments applied usually for these cases.

2. Material and Methods

From May 2008 to November 2013, 4 patients with far advanced lung adenocarcinoma were treated with complementary oncothermia and chemotherapy. These patients in the late stages are generally suitable for palliation only, but we tried to be curative. Chemotherapy was various taking into consideration the previous chemo-

therapy treatments and the actual status of the patient. Oncothermia was provided by the EHY2000+ device (Oncotherm, Germany). The device and its heating power were checked, the temperature development was checked on solid-state carbon phantom. The applicator was carefully fixed on the appropriate place of the chest of the patient, using 30 cm diameter size. The water-bolus cooling was mild to keep the homeostasis on the body-surface. The actually applied power was administered in step-up heating up to the actual tolerable limit of the patient. The energy dose aimed the described 5000 kJ in 8 sessions, however when the patient could not tolerate well the dose, it was reduced in the actual session and the number of sessions was increased.

2.1. Case 1

Forty-five years old male patient was diagnosed of stage IV (T4N3M1) advanced lung adenocarcinoma of right lower lobe (RLL) with metastases to both lungs in July 2011. First line chemotherapy of Vinorelbine and Cisplatin was administered initially. However, follow-up chest PA and chest CT revealed aggravated metastases on both lungs. After transferred to Gangnam Severance Hospital in February 2012 (**Figure 1(a)**), second line chemotherapy using Tarceva and oncothermia were administered (6 cycles) from February 2012 to August 2013 for a period of 18 months. Follow-up serial chest PA and chest CT showed gradual improvement with significant regression of metastatic tumors and stable disease of primary tumor in August 2013 (**Figure 1(b)**). However,

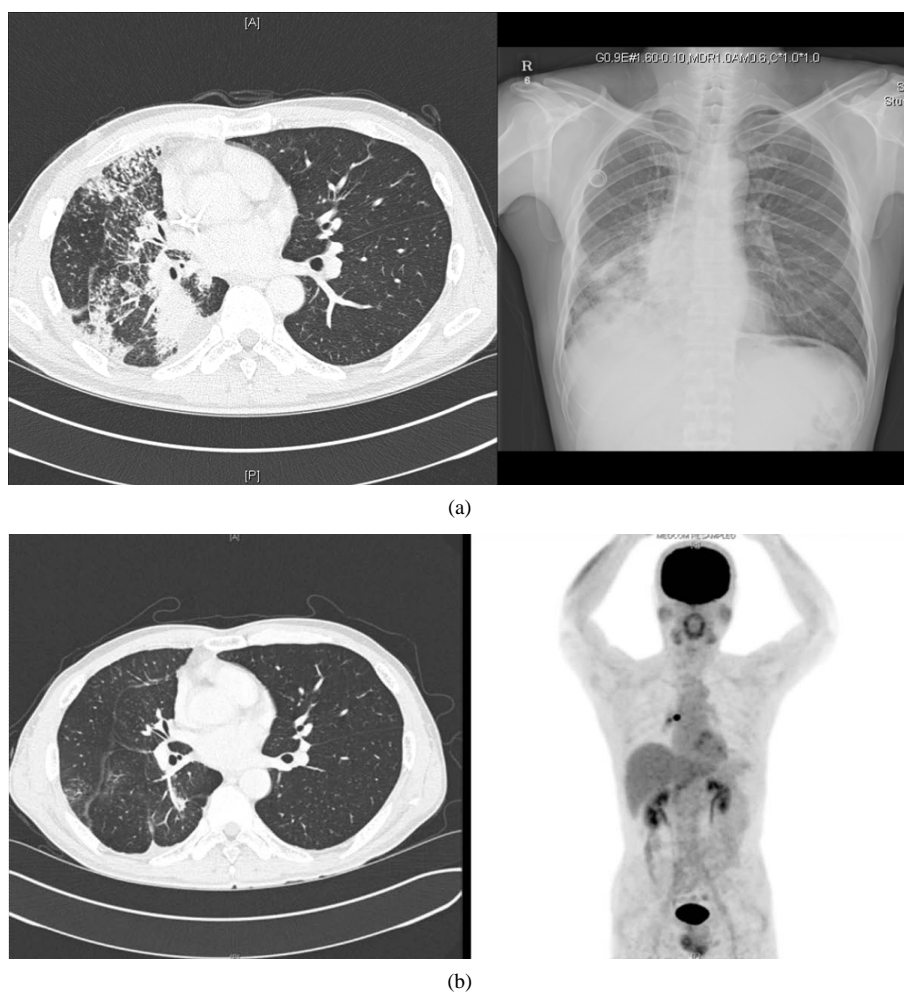


Figure 1. Radiologic exam of 45-year-old male patient. (a) Chest X-ray and CT (Feb. 2012) showed mass and consolidation of right lower lobe of the lung, and multiple small nodular lesions in both lungs. Compared to initial exam, progression of lung cancer with bilateral lung metastases was suspected; (b) Follow-up chest CT & PET (Aug. 2013) showed significant tumor regression.

patient stopped treatment at his own will and for 2 months since then, and follow-up radiologic exam in November 2013 showed slightly increased size of primary tumor. Diagnostic surgery which included wedge resection of RLL and mediastinal lymph node sampling revealed remaining primary adenocarcinoma without mediastinal lymph node metastasis. The EGFR mutation was expressed in the tumor specimen. He has been under treatment with Tarceva and oncothermia until now.

2.2. Case 2

A solitary pulmonary nodule was found in a 55-year-old female patient on routine health exam in May 2008. Chest CT showed 2 cm diameter tumor in LLL and 0.5 cm nodules in LUL and RML (chest PA, chest CT). There was no endobronchial lesion by bronchoscopy and fine needle aspiration biopsy LLL tumor revealed lung adenocarcinoma. Those two small nodules in LUL and RML were regarded radiologically as benign. However, wedge resections on May 2008 revealed primary lung adenocarcinoma from LLL tumor and metastasis from LUL nodule. No metastasis was found in the interlobar and ipsilateral mediastinal lymph nodes. EGFR mutation was positively expressed.

Patient refused to receive chemotherapy because she had worried about some complications and side effects of CTX such as anorexia, general weakness and neurological paresthesia. However, multiple metastases appeared in both lungs by follow-up chest PA and chest CT in November 2013 (stage IV) (chest PA, chest CT). Two cycles of first line chemotherapy with Tarceva was administered based on positive EFGR mutation along with oncothermia until December 2013 and follow-up radiologic exam showed marked regression of multiple metastatic nodules (Figure 2). She is in good condition only with moderate skin rashes on the face and chest wall, and is under intermittent Tarceva treatment.

2.3. Case 3

Sixty-eight years old female was transferred to Gangnam Severance hospital due to lung tumor on RUL by routine health exam in February 2011. The chest PA and chest CT revealed about 8 cm diameter tumor in RUL with suspected chest wall invasion and pleural seeding (Figure 3(a)). Tumor was pathologically confirmed as lung adenocarcinoma by bronchoscopy and percutaneous biopsy. Fifteen cycles of first-line chemotherapy and 4 cycles of oncothermia were administered until August 2012. Follow-up serial chest CT showed marked regression of primary tumor in the early phase of treatment, and then gradual settle down to stable disease during that period. The patient is not under treatment since November 2013 and there is no evidence of disease progression until now (Figure 3(b)).

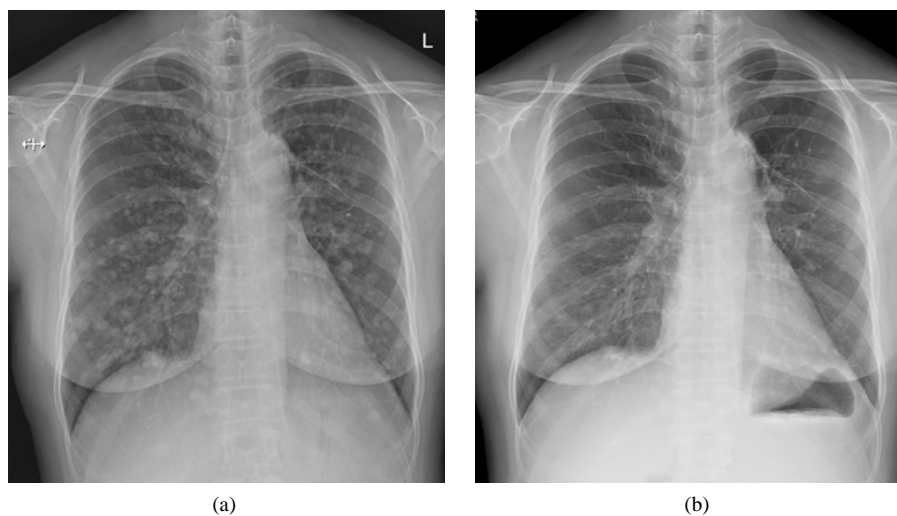


Figure 2. Chest X-ray of 55-year-old female patient with bilateral metastasis of lung cancer. (a) Chest X-ray in September 2013 showed bilateral multiple metastasis of lung cancer; (b) After 2 months of bilateral thoracic oncothermia with chemotherapy, follow-up chest X-ray showed marked regression of bilateral lung metastasis.

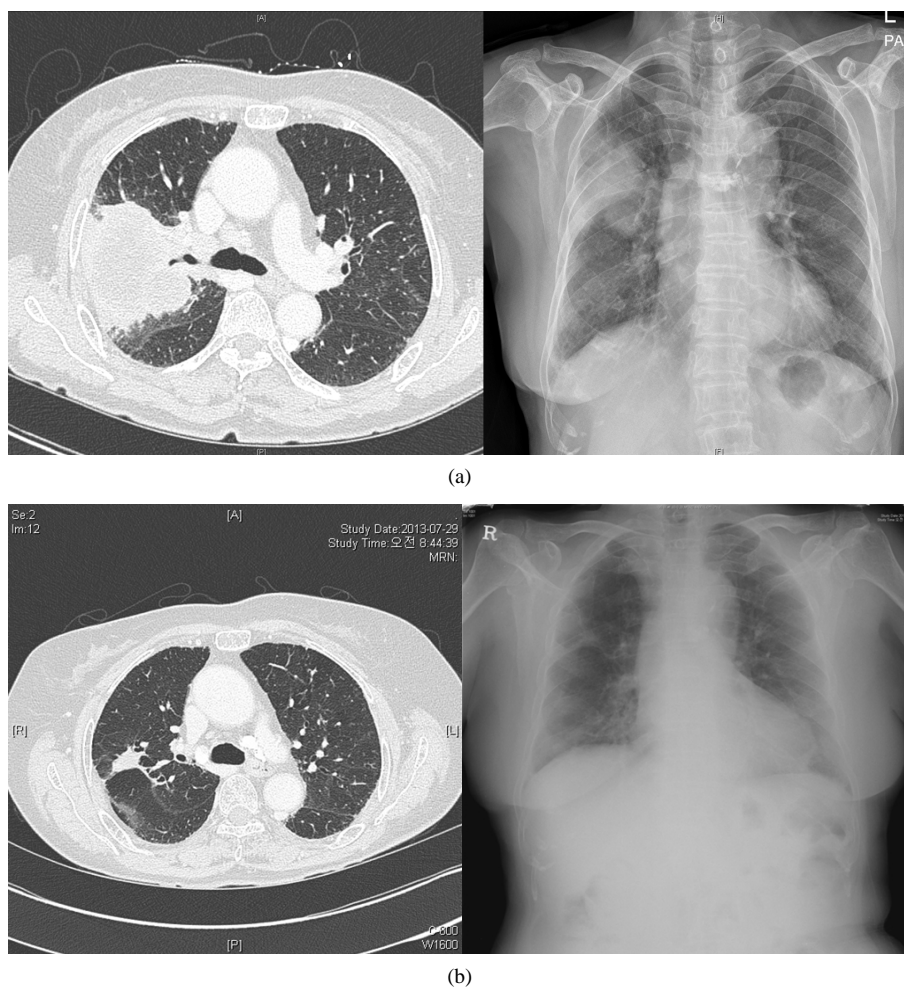

Figure 3. Chest X-ray and CT of 68-year-old female patient. (a) In February 2011, a huge tumor was observed in RUL with suspected chest wall invasion and pleural dissemination; (b) After 18 months of oncothermia with chemotherapy, follow-up exam in August 2012 showed marked regression of primary tumor.

2.4. Case 4

Sixty years old male was admitted to Gangnam Severance Hospital due to exertional dyspnea and right chest discomfort in September 2011 (**Figure 4(a)**). Chest PA and chest CT showed tumor on RLL with suspected multiple metastases in RUL. Bronchcopy and percutaneous biopsy of RLL tumor confirmed lung adenocarcinoma. Multiple metastases were found in the brain, spine, and pelvic bones by whole body bone scan and brain MRI (Stage IV with M1B disease). First line chemotherapy with Pemetrexol and Cisplatin along with whole brain radiotherapy was administered from October 2011 to February 2012. However, follow-up chest CT showed aggravation of primary tumor and the patient was transferred to Gangnam Severance Hospital in February 2012.

Oncothermia on RLL primary tumor along with second line chemotherapy by Tarceva was administered from February 2012. Follow-up radiologic exam showed marked regression of primary tumor, but newly detected ascites were found due to peritoneal carcinomatosis. Chemotherapy regimen was changed into third line chemotherapy with Gemcitabine and Cisplatin, and oncothermia covered larger area from RLL primary tumor and abdomen for 4 months from June 2012 to September 2012.

The disease seeded stable for a year without further treatment before the patient was re-admitted to Bundang CHA medical center due to re-developed exertional dyspnea and abdominal discomfort in October 2013 (**Figure 4(b)**). Bilateral pleural effusion due to pleural metastases, ascites due to peritoneal metastases and subsequent

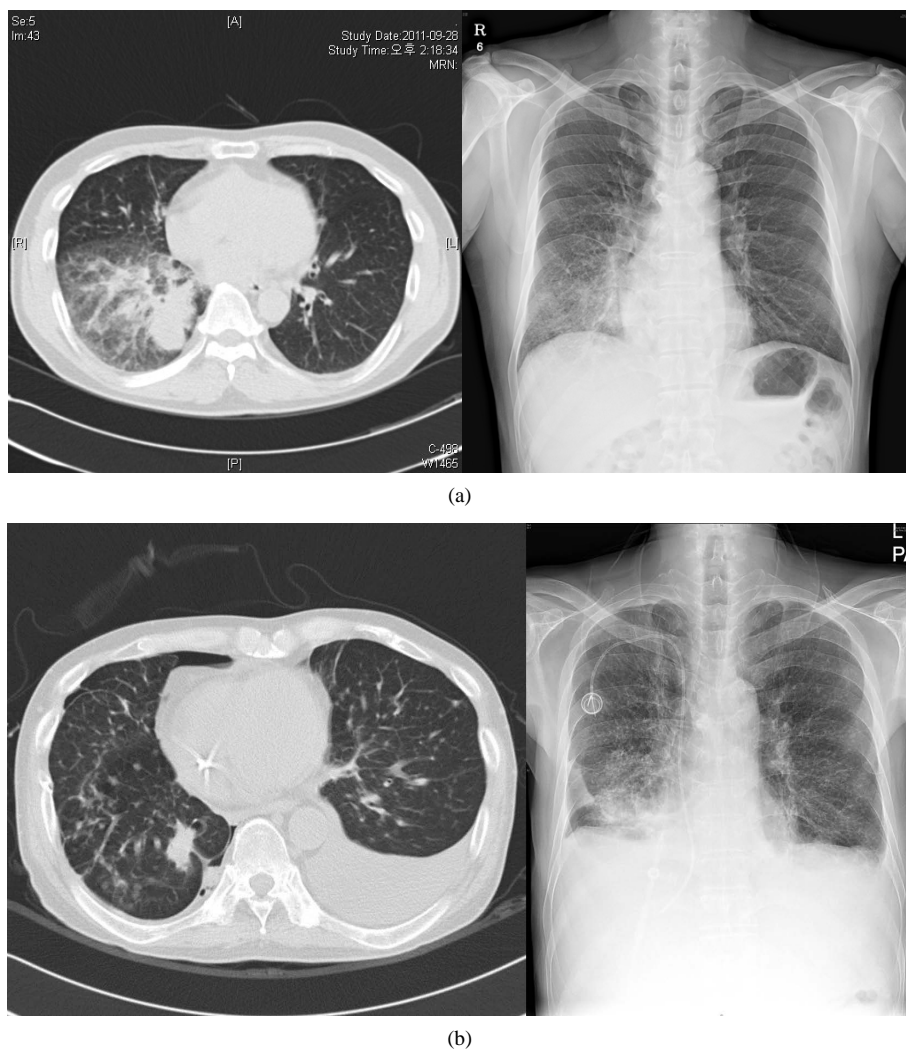


Figure 4. Radiologic exam of 60-year-old male patient with RLL lung cancer. (a) Initial exam in September 2011 showed right lower lobe lung cancer; (b) After combination of chemotherapy and oncothermia, follow-up exam in September 2013 showed marked regression of primary tumor.

multiple liver metastasis were found by serial follow-up chest and abdominal CT. After drainage of pleural effusion and ascites, oncothermia was administered on RLL primary tumor and abdomen alternatively in daily turns. Chemotherapy could not be done due to poor performance. Despite that the primary tumor showed regression, aspiration pneumonia occurred and patient died in November 2013.

3. Conclusions

- 1) Four patients with far advanced lung adenocarcinoma (stage IV) have survived for more than 2 years with combination of chemotherapy and oncothermia. No complete remission was achieved.
- 2) Conventional hyperthermia has difficulties to heat-up the breathing cooled lung, and so it cannot achieve curatively higher temperature in lung tumor cells.
- 3) Oncothermia can deliver electromagnetic energy more deeply and selectively to tumor tissue. It can also change the pH environment around tumor to induce tumor apoptosis.
- 4) Oncothermia enhance the effect of chemotherapy because it can induce higher concentration of chemo-agents inside the tumor by stasis of blood flow around the tumor and accelerated absorption of chemo-agents into tumor tissue by decreased interstitial fluid in tumor cells.

5) Despite the shrinkage of treated tumor by the combined chemotherapy and oncothermia, the distantly developed metastatic tumors, which are out of the treated area of oncothermia have continuous growth despite the systemic effect of the applied drug. Therefore, oncothermia can be useful as a kind of local treatment like radiation, rather than systemic treatment such as chemotherapy.

6) At least 3 cycles of oncothermia is required to have effect on local tumor regression. Oncothermia can be applied on both the primary tumor and metastases if possible.

References

- [1] Owonikoko, T.K., Ragin, C.C., Belani, C.P., Oton, A.B., Gooding, W.E., Taioli, E. and Ramalingam, S.S. (2007) Lung Cancer in Elderly Patients: An Analysis of the Surveillance, Epidemiology, and End Results Database. *Journal of Clinical Oncology*, **25**, 5570-5577. <http://dx.doi.org/10.1200/JCO.2007.12.5435>
- [2] Siegel, R. (2013) Cancer Statistics. *Ca—Cancer Journal for Clinicians*, **63**, 11-30. <http://dx.doi.org/10.3322/caac.21166>
- [3] Polo, V. and Besse, B. (2014) Maintenance Strategies in Stage IV Non-Small-Cell Lung Cancer (NSCLC): In Which Patients, With Which Drugs? *Annals of Oncology* **25**, 1283-1293. <http://dx.doi.org/10.1093/annonc/mdt529>
- [4] Akcali, Z., Calikusu, Z., Sakalli, H. and Ozyilkan, O. (2008) Gemcitabine and Cisplatin Treatment of Advanced-Stage Non-Small-Cell Lung Cancer in Patients Given Cisplatin on Day 8. *Tumori*, **94**, 474-480.
- [5] Kawano, Y., Ohyanagi, F., Yanagitani, N., Kudo, K., Horiike, A., Tanimoto, A., Nishizawa, H., Ichikawa, A., Sakatani, T., Nakatomi, K., Hagiwara, S., Ninomiya, H., Motoi, N., Ishikawa, Y., Horai, T. and Nishio, M. (2013) Pemetrexed and Cisplatin for Advanced Non-Squamous Non-Small Cell Lung Cancer in Japanese Patients: Phase II Study. *Anti-cancer Research*, **33**, 3327-3333.
- [6] Szasz, A. (2014) Current Status of Oncothermia Therapy for Lung Cancer, *The Korean Journal of Thoracic and Cardiovascular Surgery*, **47**, 77-93. <http://dx.doi.org/10.5090/kjtcs.2014.47.2.77>
- [7] Szasz, A., Szasz, N. and Szasz, O. (2010) Oncothermia—Principles and Practices. Springer, Dordrecht.
- [8] Szasz, A. (2013) Challenges and Solutions in Oncological Hyperthermia, *Thermal Medicine*, **29**, 1-23. <http://dx.doi.org/10.3191/thermalmed.29.1>
- [9] Szasz, A., Szasz, N. and Szasz, O. (2013) Local Hyperthermia in Oncology. In: Huilgol, N., Ed., *Hyperthermia*, InTech, Winchester, 1-82.
- [10] Szasz, A. (2013) Electromagnetic Effects in Nanoscale Range. In: Shimizu, T. and Kondo, T., Eds., *Cellular Response to Physical Stress and Therapeutic Application*, Nova Science Publishers, Inc., New York, 55-81.
- [11] Szasz, A., Vincze, Gy., Szasz, O. and Szasz, N. (2003) An Energy Analysis of Extracellular Hyperthermia. *Electromagnetic Biology and Medicine*, **22**, 103-105. <http://dx.doi.org/10.1081/JBC-120024620>
- [12] Szasz, O. and Szasz, A. (2014) Oncothermia—Nano-Heating Paradigm. *Journal of Cancer Science and Therapy*, **6**, 117-121. <http://dx.doi.org/10.4172/1948-5956.1000259>
- [13] Meggyeshazi, N., Andocs, G., Balogh, L., Balla, P., Kiszner, G., Teleki, I., Jeney, A. and Krenacs, T. (2014) DNA Fragmentation and Caspase-Independent Programmed Cell Death by Modulated Electrohyperthermia. *Strahlentherapie und Onkologie*, **190**, 815-822. <http://dx.doi.org/10.1007/s00066-014-0617-1>
- [14] Andocs, G., Meggyeshazi, N., Balogh, L., Spisak, S., Maros M.E., Balla, P., Kiszner, G., Teleki, I., Kovago, Cs. and Krenacs, T. (2014) Upregulation of Heat Shock Proteins and the Promotion of Damage-Associated Molecular Pattern Signals in a Colorectal Cancer Model by Modulated Electrohyperthermia. *Cell Stress and Chaperones*, **20**, 37-46. <http://dx.doi.org/10.1007/s12192-014-0523-6>